

# Inferior alveolar nerve paresthesia due to radicular cyst: A case and review of literature

Bilal Ege<sup>1</sup>, Mahmut Koparal<sup>1</sup>, Gunay Yapici Yavuz<sup>1</sup>, Aydin Keskinruzgar<sup>1</sup>, Abdussamed Geyik<sup>1</sup>, Bilge Aydin Turk<sup>2</sup>

<sup>1</sup>Adiyaman University, Faculty of Dentistry, Department of Oral and Maxillofacial Surgery, Adiyaman, Turkey

<sup>2</sup>Adiyaman University, Faculty of Medicine, Department of Pathology, Adiyaman, Turkey

Copyright © 2019 by authors and Annals of Medical Research Publishing Inc.

## Abstract

Radicular cysts are inflammatory jaw cysts that form in the apices of infected and necrotic pulp teeth. They are usually asymptomatic and tend to grow slowly. However, depending on the progressive size of the lesion and its relation to neighboring tissues, it may cause mobility, root resorption and displacement. In addition, a limited number of studies have been reported in which paresthesia occurs as a result of local pressure caused by periapical pathology and various mandibular intraosseous lesions on nerve tissue. In this study, treatment process of the paresthesia of inferior alveolar nerve caused by radicular cyst which is remained asymptomatic for a long time in the left posterior mandible is presented in a 33 year-old male patient and it is evaluated in the light of current literature.

**Keywords:** Apical lesion; jaw cysts; mandibular nerve; paresthesia

## INTRODUCTION

Radicular cysts (RC) are the most common inflammatory odontogenic cysts in the jaws and usually originate from these epithelium residues in the periodontal ligament or necrotic pulp. It is mostly seen in males and between the third or sixth decades of life as in our case. These cysts, which tend to grow slowly, can be seen in every region of the jaws, but most frequently observed in the maxillary anterior region (1). Clinically, the lesion is usually small in size and asymptomatic. Also they can be present in the jaws for a long time without notice unless they are infected and give a clear sign. For this reason they are usually noticed during routine examinations. However, when they reach large sizes and are infected, they cause complaints such as pain, swelling, tenderness and paresthesia (2). In our case the RC in posterior mandible was similarly asymptomatic at first, but after being infected mobility in the adjacent teeth and later paresthesia in the lips was observed.

Paresthesia is a neurosensitivity disorder characterized by burning or partial loss of local sensibility and this is often described by patients as burning, tingling and numbness in the skin and gums (3,4). In dentistry, various local or

systemic factors are caused by mental or inferior alveolar nerve (IAN) paresthesia. While systemic factors include multiple sclerosis, lymphoma, sarcoidosis, various viral or bacterial infections, local factors include mandibular fractures, surgical trauma, osteomyelitis and local infections (4-6). This paresthesia seen in the jaws can also be encountered as a result of mechanical, thermal or toxic injuries (7,8). In addition to all these factors, mental and/or IAN paresthesia may develop due to pressure caused by intraosseous benign tumors, cysts or pathological lesions, and related ischemia and influence of toxins present in the environment (9-12). In addition to these two nerves, it was also reported that lingual nerve paresthesia was reported to be developed in the mandible as a result of RC (13). In present study, we aimed to present the clinical course and treatment of IAN paresthesia case which is developed as a result of RC, and to discuss this rare case together with the literature.

## CASE REPORT

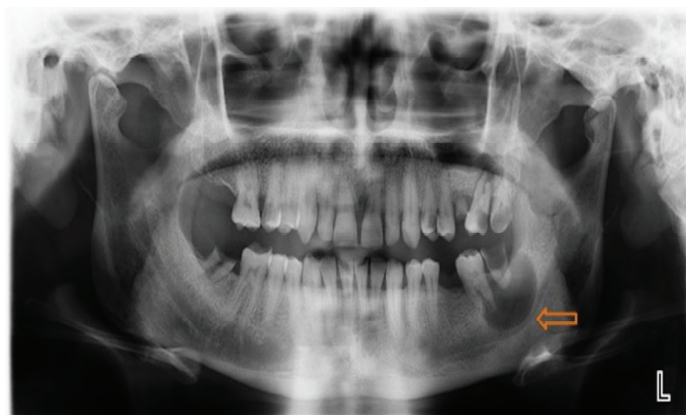A 33-year-old male patient presented to our clinic with complaints of severe pain and swelling in the lower left jaw, which has been present for a long time and was exacerbated with chewing. The patient's medical

**Received:** 14.10.2019 **Accepted:** 07.11.2019 **Available online:** 10.01.2020

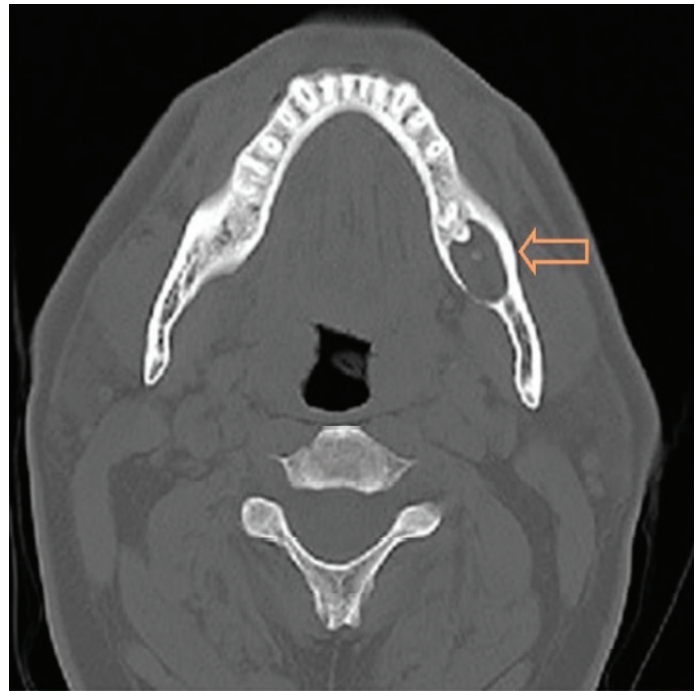**Corresponding Author:** Bilal Ege, Adiyaman University, Faculty of Dentistry, Department of Oral and Maxillofacial Surgery, Adiyaman, Turkey, **E-mail:** miregein@gmail.com

history revealed that although he had received prolonged antibiotics and analgesics treatment, both the pain and the swelling continued to increase. The patient presented to our clinic when an additional feeling of numbness started past month in the same region from the posterior to the tip of the left jaw and the lips which caused the patient's psychosocial state to be affected negatively.

In medical anamnesis, it was learned that he did not have any systemic or hereditary disease and did not use smoke, alcohol and any medication. The dental history of the patient showed that he had received medical treatment for pain, swelling and the dental abscesses originating from the teeth no 18-17-36-48 and eventually these teeth were removed. Extra oral examination showed no asymmetry, swelling, pathology or a lesion on the face. In addition, no abnormality was detected in the head and neck lymph node examination, and the nodules were asymptomatic. The intraoral examination revealed that the oral hygiene of the patient was inadequate. For this reason, there were bleeding in the gums, localized loss of alveolar bone along with swelling and periodontal pockets. In addition, there were deep caries in the teeth no 15, 24, 27, 28, 38, 48, and 27, and there were grade 3 tooth mobility in tooth no 27, grade 2 mobility in tooth no 28 and grade 1 mobility in teeth no 37-38 according to the Miller's classification. Furthermore, there was swelling of the vestibular sulcus rather than the lingual surface in the apex region of the teeth no 37-38, however, there was not any fistula and pus exit on the mucosa. This suggested that there may be an odontogenic cyst caused by chronic inflammation which was due to caries and the mobility in teeth no 37 and 38 in the lower left posterior region. Upon radiographic examination, a panoramic radiograph showed a unilocular radiolucency with a well-defined, oval, homogeneous appearance and an anteroposterior length of 25x18 mm in the apical region of the teeth no 37-38 (Figure 1). Cone-Beam Computed Tomography (CBCT) was used to evaluate the relationship between the lesion and the mandibular canal (Planmeca Promax 3D Mid, Helsinki, Finland). The tomography showed that the cortical layer was preserved in the buccal and lingual walls and there was no resorption in the buccolingual direction, but the lesion inferiorly pressed on the nerve and narrowed the canal (Figure 2).



**Figure 1.** Preoperative panoramic image (arrow: compression on the nerve of the lesion)



**Figure 2.** Preoperative CT image (arrow: buccal and lingual cortical plate)

### Paresthesia Formation Process

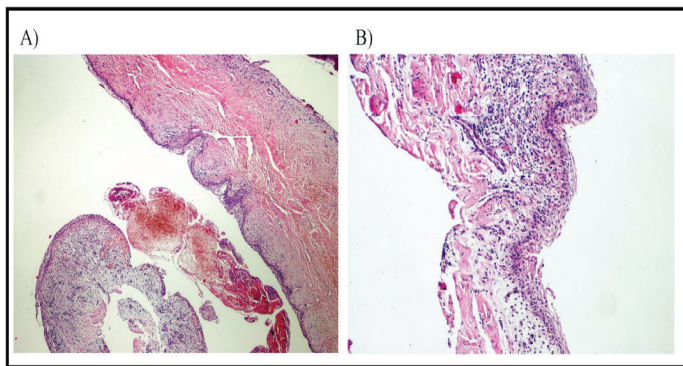
After the extra oral and intra oral examination, the superficial sensations were evaluated. The patient's eyes were closed and the sharp and blunt part of a pin was touched to the skin on both sides of the face in symmetrical areas after which the patient was asked whether he felt it. After this procedure, it was determined that there was a loss of touch and sensory sensation in the lower lip and mental region of the patient.

A radicular cyst, an odontogenic keratocyst or a residual cyst could have been considered in the differential diagnosis of the patient. All three types may have similar appearance. Residual cysts are etiologically similar to radicular cysts; however, they are usually associated with a remaining tooth root. In some cases, odontogenic keratocysts cause a diagnostic dilemma by showing appearance and location similar to those of inflammatory odontogenic cysts. However, even if they differ with regards to the high recurrence rate and aggressive behavior, histopathological evaluation should be performed for final diagnosis. We decided to take an excisional biopsy with a preliminary radicular cyst diagnosis considering the clinical and radiological examinations.

### Treatment Protocol

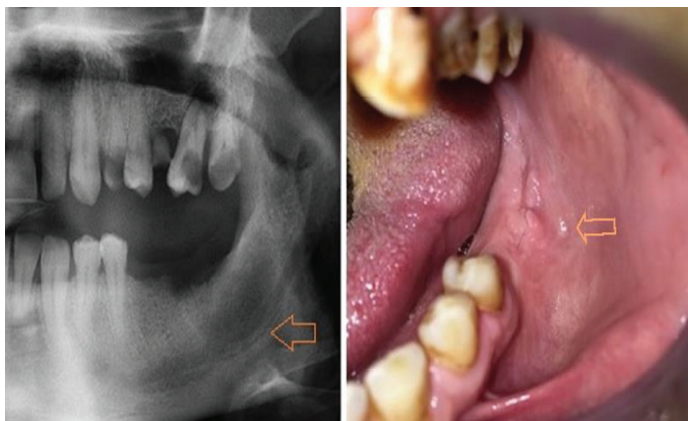
A surgical excision and curettage were performed under a local anesthesia 2 ml of 4% articaine with 1:100,000 epinephrine (Ultracain® D-S Forte; Sanofi Aventis, Topkapı, Istanbul, Turkey), which was used for inferior alveolar and buccal nerve blocks. The teeth no 37-38 were extracted and enucleation of the cyst was carried out with caution in order not to damage the nerve. The wound was closed using a 3-0 silk suture. An excisional

biopsy was performed and the specimen was submitted for the histological examination. Postoperatively, the patient was prescribed 500 mg of amoxicillin every 8 h and 550 mg of naproxen sodium every 6 h orally, when needed, and a benzydamine hydrochloride + chlorhexidine gluconate mouth rinse (1 min, three times daily) for 1 week. Immediately after surgery, an ice pack was applied to the surgical area for at least 30 min. Histopathological examination revealed the presence of a multilamellar squamous epithelium inflammatory infiltrate of the chronic type of RC without keratinization. The cyst wall was composed of an edematous, fibrous connective tissue. There was chronic inflammatory cell infiltration involving leukocytes, lymphocytes, plasma cells and macrophages in the epithelium (Figure 3). There was no finding that suggested a neoplastic lesion. On the basis of the medical history, and clinical, radiographic and histopathological examination, the final diagnosis was given as a radicular cyst associated with deep caries and pulpal inflammation.



**Figure 3.** Hematoxylin-eosin (H&E) staining of histology section showing infected hemorrhagic cyst wall with stratum squamous epithelium at A) 4X and B) 10X magnifications

At the patient's evaluation after one month, the wound was observed to heal without any problems. The patient stated that the numbness gradually decreased and it almost completely disappeared at the end of 3 months. One year clinical and radiological follow-up of the patient revealed that the wound healing was successfully completed and there was no recurrence (Figure 4).



**Figure 4.** Intraoral and radiographic appearance of postoperative 1st year (arrow: normal orientation of the nerve)

## DISCUSSION

At present, cyst formation and enlargement of cyst epithelium is still not fully understood. However, epithelial vascularity and proliferation are thought to play an important role in the development of this condition. One of the pathologies in which this active proliferation is seen is inflammatory odontogenic cysts. Such lesions are originating from the necrotic pulp of teeth and formed in the apex region of the tooth due to various microorganisms, their toxins and epithelial debris (1,14). RC are one these types of inflammatory cysts commonly seen in the jaws and they are usually asymptomatic. For this reason, they are usually detected in routine radiographic examination or with various symptoms after being infected. In our case the RC in posterior mandible was asymptomatic at first, but after being infected mobility in the adjacent teeth and later paresthesia in the lips was observed.

Sensory nerve impairments seen in the oropharyngeal region, especially paresthesia of the lower lip are a rare symptom. However, when it occurs, it affects the patient comfort and quality of life quite negatively. When most of the cases seen in the mandible are considered, it is seen that paresthesia is related to IAN and its branches. The main causes of this condition are periapical pathology and periodontal diseases (4,6,15). However, it is also stated in the literature that paresthesia can be caused by periodontal-endodontic pathologies, irrigants overflowing from root canal during endodontic treatment, various materials used during treatment and implant surgery (4,6,16-20).

It is known that bacterial toxins and metabolic debris present in the infected area may cause deterioration in the nerve conduction (4,6,15). Paresthesia seen as a result of periapical pathology are examples of this situation and it generally develops as a result of acute inflammatory process, the edema developed due to proliferation, and the compression created on the nerve tissue due to enlargement (4,6,15,21). Such neuropathologies are defined as reversible blockade of neurotransmission (neuropraxia) and it is emphasized that it may be caused by transient ischemia which occurs on acute or chronic stress on nerve tissue (22). In our case, the present neurosensory disorder was not observed at the beginning, but later when the RC is enlarged and infected, paresthesia developed on IAN, which suggests that this can be neuropraxia.

In the literature, cases with paresthesia in IAN due to intraosseous lesions have also been reported. Bodner et al. reported that the numbness in the lower lip related to compound odontoma located in the mental region improved after surgical excision (9). Also, Goodstein et al. reported that the paresthesia resulting from traumatic bone cyst located in the left posterior mandible recovered after surgery (10). Aziz et al. also reported that after surgical excision of dentigerous cysts with impacted twenty-year-old teeth in the right posterior mandible, neurological functions completely improved in 3rd month



(11). The authors share in common that paresthesia is the result of mechanical compression of the lesion to nerve. Similarly, Hamada et al. have reported that lingual and IAN paresthesia due to RC in the mandible is resolved after cystectomy (13). In our case, the numbness of the patient disappeared after cyst excision and curettage, and it was observed that there was no neurological change in 3rd month control. In neurapraxia a rapid recovery may occur after causative factor is removed but this can last from 3 to 4 months depending on how much the nerve affected (22). Also in the literature it is stated that the effect of paresthesia can last for months or can even be permanent (23). For this reason, after paresthesia the type of agent causing this condition, the size of the neurosensorial damage and the time spent thereafter are very important and the most appropriate treatment option should be determined as soon as possible according to these factors (23).

In treatment of cases caused by local infections, especially in mental nerve paresthesia, root canal treatment is often sufficient. Morse et al. reported that paresthesia due to infection disappeared after root canal treatment in the premolar teeth within 7 weeks (4). In the same situation, Genç et al. used antibiotic-assisted endodontic treatment and patient recovered within 8 weeks (12). Güneşer et al. reported that patient fully recovered within 2 weeks with only endodontic therapy without surgical intervention (24). Although endodontic therapy is a preferably method, sometimes it can cause mental or IAN paresthesia for various reasons. For example, neurotoxic materials used during treatment are the most common causes. In such cases, in order to prevent permanent nerve damage, the amount of the overflowing material should be taken into consideration and the tooth should be extracted if necessary and the overflowing material should be removed immediately (25).

In cases such as periapical pathology and RC, a very rapid treatment should be applied in order to avoid permanent paresthesia (4). Considering the close relation of the lesion to the nerve, more conservative treatment options such as endodontic treatment or marsupialization should be considered as priority to reduce the risk of permanent nerve injury after surgery. However, when these treatments are not possible, surgical treatment such as curettage and / or enucleation should be performed to remove pathologic tissue-induced mechanical stress and pathological irritants from the environment, thereby removing degeneration in the nerve tissue (8). Careful curettage of the involved tooth and lesion was performed without radical surgical options such as segmental or marginal resection in the presented case because the patient applied to us very late after lip paresthesia. After the treatment, paresthesia quickly disappeared. The patient was finally directed to perform other dental treatments prior to prosthetic and implant therapy.

## CONCLUSION

Although RC tend to be asymptomatic and slow growing,

patient follow-up is very important. Otherwise, this growth may not be foreseeable, and as in the case we are experiencing, cyst may result in paresthesia due compression to inferior alveolar nerve. Therefore, it should be noted that RC may cause unwanted conditions in neighboring anatomical structures and patients should be informed about the healing process and possible duration after the patient has paresthesia. In conclusion, although RC is asymptomatic, it will be useful to be treated when they are diagnosed.

*Competing interests: All of the authors of this manuscript declared that there is no conflict of interest.*

*Financial Disclosure: There are no financial supports.*

*Bilal Ege ORCID: 0000-0002-1279-0893*

*Mahmut Koparal ORCID: 0000-0003-1817-1230*

*Gunay Yapici Yavuz ORCID: 0000-0002-1093-6297*

*Aydin Keskinruzgar ORCID: 0000-0001-5735-6890*

*Abdussamed Geyik ORCID: 0000-0002-8386-8619*

*Bilge Aydin Turk ORCID: 0000-0003-1592-1040*

## REFERENCES

1. Pekiner FZ, Borahan O, Ugurlu F, et al. Clinical and radiological features of a large radicular cyst involving the entire maxillary sinus. *Musbed* 2012;2:31-6.
2. Balaji Tandri S. Management of infected radicular cyst by surgical decompression. *J Conserv Dent* 2010;13:159-61.
3. Alves FR, Coutinho MS, Gonçalves LS. Endodontic related facial paresthesia: systematic review. *J Can Dent Assoc* 2014;80:e13.
4. Morse DR. Infection-related mental and inferior alveolar nerve paresthesia: literature review and presentation of two cases. *J Endod* 1997;23:457-60.
5. Ozkan BT, Celik S, Durmus E. Paresthesia of the mental nerve stem from periapical infection of mandibular canine tooth: a case report. *Oral Surg Oral Med Oral Pathol Oral Radiol Endod* 2008;105:28-31.
6. Giuliani M, Lajolo C, Deli G, et al. Inferior alveolar nerve paresthesia caused by endodontic pathosis: a case report and review of the literature. *Oral Surg Oral Med Oral Pathol Oral Radiol Endod* 2001;92:670-4.
7. Gaffen AS, Haas DA. Retrospective review of voluntary reports of nonsurgical paresthesia in dentistry. *J Can Dent Assoc* 2009;75:579.
8. Ahonen M, Tjäderhane L. Endodontic-related paresthesia: a case report and literature review. *J Endod* 2011;37:1460-4.
9. Bodner L, Oberman M, Shteyer A. Mental nerve neuropathy associated with compound odontoma. *Oral Surg Oral Med Oral Pathol* 1987;63:658-60.
10. Goodstein DB, Himmelfarb R. Paresthesia and the traumatic bone cyst. *Abbreviated case report. Oral Surg Oral Med Oral Pathol* 1976;42:442-6.
11. Aziz SR, Pulse C, Dourmas MA, et al. Inferior alveolar nerve paresthesia associated with a mandibular dentigerous cyst. *J Oral Maxillofac Surg* 2002;60:457-9.
12. Genc Sen O, Kaplan V. Temporary Mental Nerve

- Paresthesia Originating from Periapical Infection. *Case Rep Dent* 2015;2015:457645.
13. Hamada Y, Yamada H, Hamada A, et al. Simultaneous paresthesia of the lingual nerve and inferior alveolar nerve caused by a radicular cyst. *J Endod* 2005;31:764-6.
  14. Johnson NR, Gannon OM, Savage NW, et al. Frequency of odontogenic cysts and tumors: a systematic review. *J Investig Clin Dent* 2014;5:9-14.
  15. Di Lenarda R, Cadenaro M, Stacchi C. Paresthesia of the mental nerve induced by periapical infection. A case report. *Oral Surg Oral Med Oral Pathol Oral Radiol Endod* 2000;90:746-9.
  16. Ricucci D, Loghin S, Siqueira JF Jr. Complicated untreated apical periodontitis causing paraesthesia: A case report. *Aust Endod J* 2018;44:281-5.
  17. Dempf R, Hausamen JE. Lesions of the inferior alveolar nerve arising from endodontic treatment. *Aust Endod J* 2000;26:67-71.
  18. Poveda R, Bagán JV, Fernández JM, et al. Mental nerve paresthesia associated with endodontic paste within the mandibular canal: report of a case. *Oral Surg Oral Med Oral Pathol Oral Radiol Endod* 2006;102:e46-9.
  19. Zmener O. Mental nerve paresthesia associated with an adhesive resin restoration: a case report. *J Endod* 2004;30:117-9.
  20. Jafarian M, Rayati F, Najafi E. Successful treatment of a large implant periapical lesion that caused paraesthesia and perimandibular abscess. *Dent Res J (Isfahan)* 2016;13:188-92.
  21. Gilbert BO, Dickerson AW II. Paresthesia of the mental nerve after acute exacerbation of chronic apical periodontitis. *J Am Dent Assoc* 1981;103:588-90.
  22. Morgan GW. Proprioception, touch and vibratory sensation. In: Goetz CG, Pappert EJ, eds. *Textbook of clinical neurology*. Philadelphia: WB Saunders; 2003. p. 333-50.
  23. Jerjes W, Swinson B, Banu B, et al. Paraesthesia of the lip and chin area resolved by endodontic treatment: A case report and review of literature. *Br Dent J* 2005;198:743-5.
  24. Guneser MB. Temporary paresthesia of the mental nerve induced by periapical infection: Case report. *Selcuk Dent J* 2016;3:135-9.
  25. Pogrel MA. Damage to the inferior alveolar nerve as the result of root canal therapy. *J Am Dent Assoc* 2007;138:65-9.