

# The importance of estrogen- $\alpha$ and progesterone immunohistochemical staining expression in patients with papillary thyroid carcinoma

Betul Peker Cengiz

Yunus Emre State Hospital, Clinic of Pathology, Eskisehir, Turkey

Copyright © 2019 by authors and Annals of Medical Research Publishing Inc.

## Abstract

**Aim:** Estrogen receptor- $\alpha$ (ER $\alpha$ ) and Progesterone receptor(PR) were studied in 58 patients who were diagnosed as papillary thyroid carcinoma in our hospital between 2011 and 2013.ER $\alpha$  and PR expression patterns were compared according to age, sex, tumor subtype, metastasis, focality and tumor size.

**Material and Methods:** ER $\alpha$  and PR immunohistochemical staining were performed on a Ventana Benchmark XT device.More than 10% expression of ER $\alpha$  and PR immunohistochemical stains in the tumor field was considered positive.

**Results:** Papillary thyroid cancer is the most common type of endocrine malignancy in females and it is approximately three times more common among females than males. Given that these lesions are more common in women than men and that the rate decreases after menopause, sex steroid hormones are thought to play a role in the etiology of the benign and malignant lesions of the thyroid. .

**Conclusion:** The findings in our study support many studies in the literature, and there is a significant relationship between tumor size, tumor stage, and metastasis and ER $\alpha$  and PR immunohistochemical expression.However, more studies are still needed to evaluate the effect of ER $\alpha$  and PR on thyroid papillary cancers.

**Keywords:**ER $\alpha$ ; PR; thyroid; papillary cancer; immunohistochemistry

## INTRODUCTION

Thyroid cancers are the most common endocrine tumors. They are the 5th most common tumor type among women in developed countries, and the rate has been increasing in some regions in recent years (1).The pathogenesis of thyroid cancers is complicated, and factors such as iodine deficiency, radiation history and genetic influences are included in the etiology (2).However, given that these lesions are more common in women than men and that the rate decreases after menopause, sex steroid hormones are thought to play a role in the etiology of the benign and malignant lesions of the thyroid.

Estrogen and progesterone are hormones with steroid structure.They are synthesized from acetyl CoA, mainly from cholesterol.Initially, progesterone and testosterone are synthesized.Then, these two hormones are converted to estrogen. The three important estrogen types are  $\beta$ -estradiol, estrone and estriol.Estrogen plays crucial roles in the growth and embryological development of cells and

maintaining life in most mammalian tissues (3-5).It has been shown in researches that the physiological effects of estrogen at the cellular level are mainly performed by three mechanisms (6-9). The first mechanism is named as "direct genomic", the second mechanism as "indirect genomic" and the third mechanism as "nongenomic effect" (10-12). Estrogen carries out its effects through the genomic mechanism via estrogen receptors (13,14). Estrogen receptors are divided into two subgroups called ER $\alpha$  and ER $\beta$  (15,16). Studies have shown that the existence of ER $\alpha$  is associated with proliferative effects of estrogens and ER $\beta$  has growth-suppressing activities. Progesterone exerts its effects through the progesterone receptors, which have two subgroups.Progesterone regulates the proliferation and function of some cells through PR-A and PR-B receptors (17).

The presence of sex steroid receptors was first demonstrated in 1960, and since then, its role in cancer patients has been known (18).Today, its relationship with breast cancers has been shown, and it is utilized in the

**Received:** 25.06.2019 **Accepted:** 16.08.2019 **Available online:** 21.10.2019

**Corresponding Author:** Betul Peker Cengiz, Yunus Emre State Hospital, Clinic of Pathology, Eskisehir,Turkey

**E-mail:** betip76@yahoo.com

treatment. A number of studies have been conducted to demonstrate whether there is such a relationship in thyroid cancers. The epidemiological and experimental studies performed in the last 10 years show that estrogen and progesterone play a probable role in the development and progression of differentiated thyroid tumors. While it has been stated in a few studies in the literature that pregnancy increases the risk of thyroid cancer, there are also studies in which it was reported that low-dose estrogen therapy or hormone replacement therapy in postmenopausal women do not increase the risk (19-21). Although there are studies supporting and opposing this relationship, we evaluated the clinical and pathological parameters of the patients and the estrogen and progesterone receptor expressions of the tumors.

## MATERIAL and METHODS

In our hospital, 670 thyroid operations were performed between 2011 and 2013, and 58 patients were diagnosed as thyroid papillary carcinoma. All 58 patients diagnosed as papillary carcinoma were included in our study. All patients underwent bilateral total thyroidectomy and regional lymph node dissection, followed by radioactive iodine therapy. After treatment, daily oral thyroid hormone (e.g., Levothyroxine) was initiated, and the patients were observed at the endocrine outpatient clinic with 3-6 months intervals. The clinical follow-up of the patients was managed through visits and patient files.

Thyroid tissue samples were taken from suspicious surgical areas and fixed in 10% buffered formalin. Tumor samples were processed in an automated tissue tracking device. The samples were embedded in paraffin to form paraffin blocks. After staining, the sections prepared from paraffin blocks with H&E, and tumor sites were selected. Estrogen- $\alpha$  (Dako, Clone EP1, Ready-to-use) and Progesterone (Dako, Clone PgR 1294, Ready-to-use) receptor immunohistochemical staining was performed to selected samples on the Ventana Benchman XT device. Estrogen- $\alpha$  and Progesterone-positive breast carcinomas were used as controls. The peripheral normal thyroid tissue was used as negative control. The criterion of positivity for Estrogen- $\alpha$  and Progesterone receptor immunohistochemical staining was nuclear staining in more than 10% of the tumor tissues. A minimum of 40% staining of the tumor tissue was observed.

Ethical approval was obtained from the Research and Development Department of the State Hospital for this nonrandomized retrospective study.

### Statistical analysis

Data were analyzed with the statistical package program SPSS 22.0 (SPSS Inc., Chicago, IL, USA). When evaluating the data, besides descriptive methods (mean, standard deviation, frequency), the Pearson correlation test was used to make a comparison of the groups for parameters having a normal distribution. The Chi-Square test was used

to compare qualitative data. The statistical significance level was accepted as  $p < 0.05$ .

## RESULTS

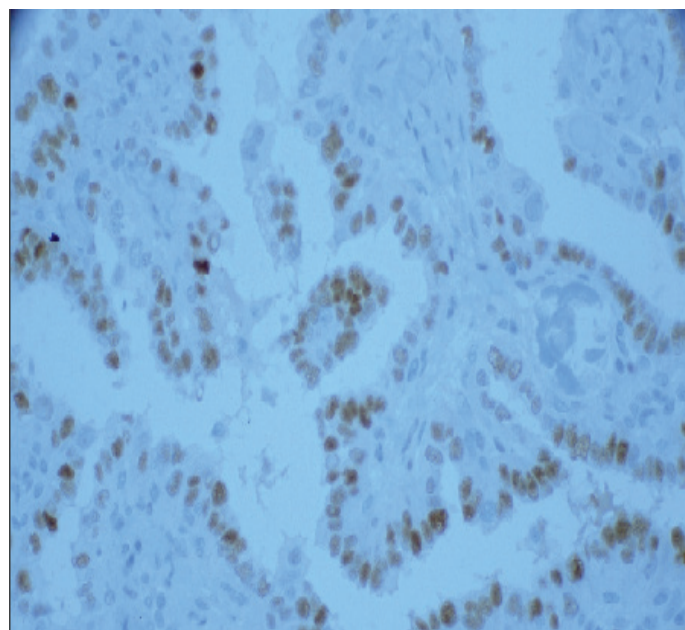
The clinical features of all patients included in the study are summarized in Table 1, and their histopathological features are summarized in Table 2. In our study, the youngest patient was 21 years old, and the oldest one was 74 years old. During the four years of follow-up, 4 of our patients had lymph node metastasis, and all of the patients were still alive. Estrogen immunohistochemical staining was positive in 23 (39.7%) of the cases; 21 of them were female, and 2 were male (Figure 1).

**Table 1. Clinical features and tumor sizes of papillary thyroid carcinoma cases**

Feature	Results	ER p value	PR p value	
Age	Mean $\pm$ SD	49.17 $\pm$ 12.03	0.649	0.923
	Range	21-74		
Gender	Female	50	0.370	0.361
	Male	8		
Size	Mean $\pm$ SD	2.03 $\pm$ 1.21	0.002	0.03
	Range	1.10-6.60		

SD: Standard deviation.

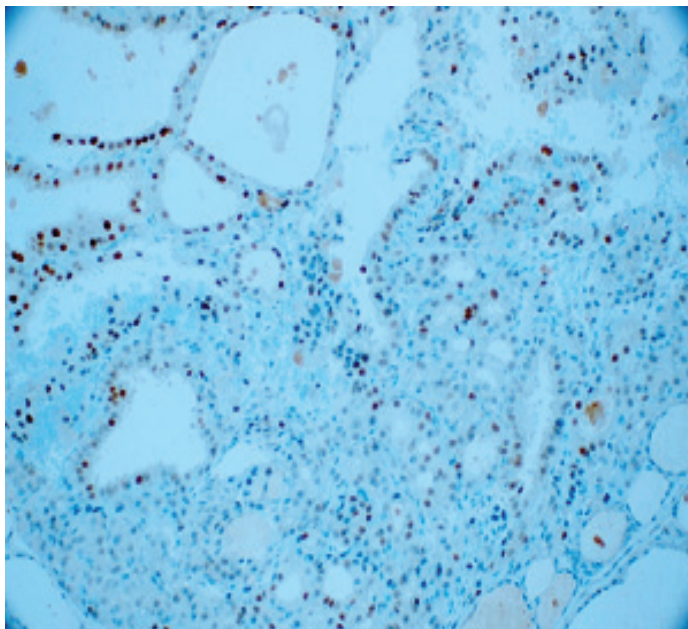
On the other hand, progesterone immunohistochemical staining was positive in 15 (25.9%) of the cases (14 women and one man) (Figure 2). There was no expression of ER $\alpha$  and PR immunohistochemical stains in the thyroid tissues having multinodularity and thyroiditis findings around the tumor samples (Figure 3).



**Figure 1.** Nuclear ER  $\alpha$  expression in primary papillary thyroid carcinoma (x40)

Table 2. Histopathological findings of the papillary thyroid carcinoma cases

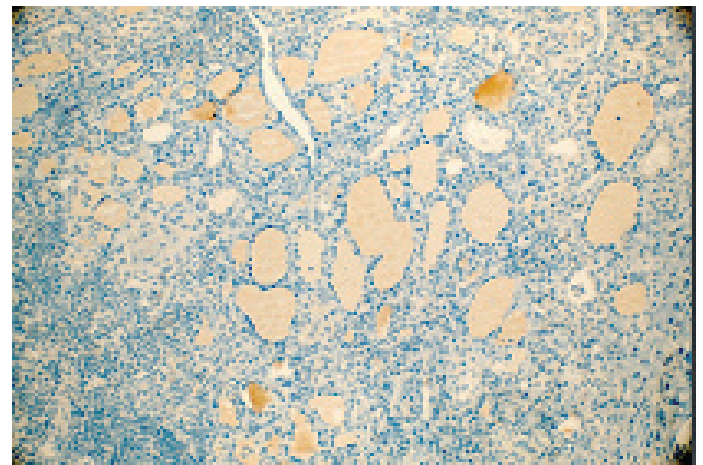
Findings			Female	Male	Total	ER P value	PR P value
Metastasis	Yes		3 (5.175%)	1 (1.725%)	4 (6.9%)	0.010	0.020
	No		47 (81.03%)	7 (12.07%)	54 (93.1%)		
Stage			Female	Male	Total	P value	P value
	T1b		34 (58.65%)	6 (10.35%)	40 (69%)	0.017	0.012
	T2		11 (18.96%)	2 (3.44%)	13 (22.4%)		
	T3a		5 (8.6%)	0 (0%)	5 (8.6%)		
Focality			Female	Male	Total	P value	P value
	Not found		26 (44.81%)	4 (6.89%)	30 (51.7%)	0.005	0.879
	The same lobe		5 (8.6%)	0 (0%)	5 (8.6%)		
	The reciprocal lobe		7 (12.04 %)	3 (5.16%)	10 (17.2%)		
Both lobes		12 (20.68%)	1 (1.72%)	13 (22.4%)			
Histopathological Subtype			Female	Male	Total	P value	P value
	Classical		19 (32.77%)	5 (8.63%)	24 (41.4%)	0.494	0.952
	Follicular		29 (50.03%)	3 (5.17%)	32 (55.2%)		
	Warthin-like (Oncocytic variant of papillary carci-noma, 2017 WHO)		2 (3.4%)	0 (0%)	2 (3.4%)		



**Figure 2.** Nuclear PR expression in primary papillary thyroid carcinoma (x20)

In our study, a significant relationship was observed between tumor size and estrogen immunohistochemical expression ( $p=0.002$ ), and progesterone immunohistochemical expression ( $p=0.003$ ) levels. Besides the relationship of estrogen and progesterone with the size of the tumor, they were also related to the stage (ER $\alpha$   $p=0.017$ ; PR  $p=0.012$ ) and metastasis (ER $\alpha$   $p=0.010$ ; PR  $p=0.020$ ). Another significant finding in our

study was the relationship found between focality and ER $\alpha$  expression ( $p = 0.005$ )



**Figure 3.** There was no expression of ER $\alpha$  immunohistochemical stain in the non-neoplastic thyroid tissues (x20)

## DISCUSSION

Estrogen, progesterone, and their receptors have been recognized to have a significant role in the pathogenesis and progression of cancers in women (especially breast carcinoma). In thyroid cancers, the importance of estrogen and progesterone in the pathogenesis and progression of the tumor is still an enigma. ER expression in the thyroid lesions was reported for the first time by Molteni et al. in 1981, and PR expression in thyroid lesions was reported for the first time by Chaudhury et al. in 1986 (22,23).

Tavangar et al. (2) reported in their study that estrogen immunohistochemical staining applied to benign and malignant thyroid lesions was positive in thyroid neoplasms. In the studies of Marugo et al. and Hoeven et al., while a high rate of progesterone expression was shown in thyroid tumors, no clear relationship was found between clinical and pathological findings (24,25).

In our study, the percentage of ER $\alpha$  positive patients was higher than the percentage of PR positive cases. While no relationship was found between progesterone positivity and age, gender, and tumor subtype, it was significantly related to tumor size. ER $\alpha$  expression was associated with tumor size as well as multifocality and metastasis. Diaz et al. showed ER immunoreactivity in normal thyroid tissues, thyroid adenomas, goiter, and differentiated and undifferentiated thyroid carcinomas (2,19,26). In the same year, Mizukami et al. published similar findings with Diaz (2,19,27). Although we did not include benign thyroid lesions in our study, ER $\alpha$  and PR immunoreactivity was not observed in the thyroid tissues (including thyroiditis and multinodularity) surrounding the tumor. There was also no significant difference between the genders. The reason for this may be that the number of male cases in the study could not reach to a number enough to yield a statistically significant result.

While studies are showing that ER $\alpha$  expression is characterized by a more aggressive phenotype in differentiated thyroid cancers in the literature, there are also studies opposing this hypothesis (19,28,29). Although cervical and supraclavicular lymph node metastases were observed in 4 cases during the about 4 years follow-up, we found a significant relationship with ER $\alpha$  and PR expression. While this relationship is statistically significant, we still have questions our minds. The reason for this significant result may be that our study did not include T3b, T4, and T1a tumors, or that the number of patients with metastases was low. To answer this question, studies with more homogeneous age groups and tumor stages are needed. Because it is a known fact that estrogen and progesterone hormones have variable expressions in women, depending on age.

Although the ER $\alpha$  expression patterns in the literature are variable and thus it is difficult to define its role in the thyroid cancer pathogenesis, the opinion accepted in most of the studies is that estrogen is a potent growth factor for benign and malignant thyroid cells and it conducts this proliferation via ER $\alpha$ -dependent signaling (19). There is an increasing number of studies suggesting that estrogen may have a direct effect on tumorigenesis in human thyroid cells by modulating cell proliferation, sodium-iodide modulation, and thyroglobulin gene expression by ER-dependent or ER-independent mechanisms. The proliferative effects of 17 $\beta$ -estradiol (E2) in thyroid cancers are mediated by the regulation of genes involved in growth control, such as bcl-2, Bax and c-fos. The proliferation of these cells is stimulated by ER- $\alpha$  agonists (17). It was

shown in the study of Vannucchi et al. that there is a non-coincidental relationship between ER $\alpha$  and PR expression in thyroid tumors and the size of the tumor (30). Also in our study, a significant relationship was found between tumor size and the ER $\alpha$  and PR expression pattern.

In the study of Eldien MMS et al. (17), in addition to clinical parameters, the relationship between histological subtypes of human thyroid papillary carcinoma and ER $\alpha$  and PR expression pattern was not significant. We found similar results in our study. However, if we had a significant difference, it could be useful in the pathology practice. The diagnosis of follicular variant papillary thyroid cancers can be challenging in pathology. The pattern of ER $\alpha$  and PR expression could be helpful in doubtful cases.

## CONCLUSION

In conclusion, a significant relationship was observed in our study between ER $\alpha$  and PR expression patterns and tumor size, and there was also a significant relationship between the ER $\alpha$  expression pattern and multifocality. These findings support many studies in the literature. However, no significant results were found concerning the pathological diagnostic process or clinical follow-up and treatment. From these aspects, more studies are needed to have definite results.

*Competing interests: The authors declare that there is no conflict of interest.*

*Financial Disclosure: The authors declared that this study has received no financial support.*

*Ethical approval: Ethical approval was obtained from the Research and Development Department of the State Hospital for this nonrandomized retrospective study.*

Betul Peker Cengiz ORCID: 0000-0002-2503-7446

## REFERENCES

1. Siegel RL, Miller KD, Jemal A. Cancer statistics, 2019. CA Cancer J Clin 2019;69:7-34.
2. Tavangar SM, Monajemzadeh M, Larijani B, et al. Immunohistochemical study of oestrogen receptors in 351 human thyroid glands. Singapore Med J 2007;48:744-7.
3. Tomikawa J, Homma T, Tajima S, et al. Molecular Characterization and Estrogen Regulation of Hypothalamic KISS1 Gene in the Pig Bio. Reprod 2009.
4. Fadini GP, Albiero M, Cignarella A, et al. Effects of androgens on endothelial progenitor cells in vitro and in vivo. Clin Sci (Lond) 2009;117:355-64.
5. Kumar DM, Simpkins JW, Agarwal N. Estrogens and neuroprotection in retinal diseases. Mol Vis 2008;14:1480-86.
6. Isgor C, Watson SJ. Estrogen receptor alpha and beta mRNA expressions by proliferating and differentiating cells in the adult rat dentate gyrus and subventricular zone. Neuroscience 2005;134:847-56.
7. Kelly MJ, Rønnekleiv OK. Control of CNS neuronal excitability by estrogens via membrane-initiated signaling. Mol Cell Endocrinol 2009;308:17-25.
8. Galea LA. Gonadal hormone modulation of neurogenesis in the dentate gyrus of adult male and female rodents. Brain Res Rev 2008;57:332-41.
9. Prange-Kiel J, Rune G.M. Direct and indirect effects of

- estrogen on rat hippocampus. *Neuroscience* 2006;138:765-72.
10. Kuiper GG, Shughrue PJ, Merchenthaler I, et al. The estrogen receptor beta subtype: a novel mediator of estrogen action in neuroendocrine systems. *Front Neuroendocrinol* 1998;19:253-86.
  11. Matthews J, Gustafsson JA. Estrogen signaling: A subtle balance between ER alpha and ER beta. *Mol Interv* 2003;3:281-92.
  12. Zhao C, Dahlman-Wright K, Gustafsson JA. Estrogen receptor beta: An overview and update. *Nucl Recept. Signal* 2008;6:3
  13. Katzenellenbogen BS, Choi I, Delage-Mourroux R, et al. Molecular mechanisms of estrogen action: selective ligands and receptor pharmacology. *J. Steroid Biochem. Mol. Biol* 2000;74:279-85.
  14. Lindberg MK, Movérare S, Skrtic S, et al. Estrogen receptor (ER)-beta reduces ERalpha-regulated gene transcription, supporting a "ying yang" relationship between ERalpha and ERbeta in mice. *Mol Endocrinol* 2003;17:203-8.
  15. Monroe DG, Getz BJ, Johnsen SA, et al. Estrogen receptor isoform-specific regulation of endogenous gene expression in human osteoblastic cell lines expressing either ERalpha or ERbeta. *J Cell Biochem* 2003;90:315-26.
  16. Cheung E, Schwabish MA, Kraus WL. Chromatin exposes intrinsic differences in the transcriptional activities of estrogen receptors alpha and beta. *E.M.B.O. J* 2003;22:600-11.
  17. Eldien MMS, Abdou AG, Rageh T, et al. Immunohistochemical expression of ER- $\alpha$  and PR in papillary thyroid carcinoma. *Ecancermedicalscience*. 2017;11:748.
  18. Memon GR, Arain SA, Jamal Q, et al. Immunohistochemical study of progesterone receptors in thyroid gland. *J Pak Med Assoc* 2005;55:321-4.
  19. Derwahl M, Nicula D. Estrogen and its role in thyroid cancer. *Endoc Relat Cancer*. 2014;21:273-83.
  20. Galanti MR, Lambe M, Ekblom A, et al. Parity and risk of thyroid cancer: a nested case-control study of a nationwide Swedish cohort. *Cancer Causes & Control* 1995;6:37-44.
  21. Kabat GC, Kim MY, Wactawski-Wende J, et al. Menstrual and reproductive factors, exogenous hormone use, and risk of thyroid carcinoma in postmenopausal women. *Cancer Causes & Control* 2012;23:2031-40.
  22. Molteni A, Warpeha RL, Brizio-Molteni L, Fors EM. Estradiol receptor-binding protein in head and neck neoplastic and normal tissue. *Arch Surg* 1981;116:207-10.
  23. Chaudhury PK, Patel N, Sandberg L. Distribution and characterization of steroid hormone receptors in human thyroid tissue. *World J Surg* 1986;10:737-44.
  24. Marugo M, Torre G, Bernasconi D, et al. Thyroid and steroid receptors. *J Endocrinol Invest* 1989;12:565-70.
  25. Hoeven K, Menendez-Botet CJ, Strong EW, et al. Estrogen and progesterone thyroid content in human thyroid disease. *Am J Clin Pathol* 1993;99:175-81.
  26. Diaz NM, Mazoujian G, Wick MR. Estrogen-receptor protein in thyroid neoplasms. An immunohistochemical analysis of papillary carcinoma, follicular carcinoma, and follicular adenoma. *Arch Pathol Lab Med* 1991;115:1203-7.
  27. Mizukami Y, Michigishi T, Nonomura A, et al. Estrogen and estrogen receptors in thyroid carcinomas. *J Surg Oncol* 1991;47:165-69.
  28. Magri F, Capelli V, Rotondi M, et al. Expression of estrogen and androgen receptors in differentiated thyroid cancer: an additional criterion to assess the patient's risk. *Endocrine-Related Cancer* 2012;19:463-71.
  29. Xu S, Chen G, Peng W, et al. Oestrogen action on thyroid progenitor cells: relevant for the pathogenesis of thyroid nodules? *J Endocrinol* 2013;218:125-33
  30. Vannucchi G, De Leo S, Perrino M, et al. Impact of estrogen and progesterone receptor expression on the clinical and molecular features of papillary thyroid cancer. *Eur J Endocrinol* 2015;173:29-36.