

Protective effect of dexpanthenol on gentamicin-induced nephrotoxicity in rats

Neslihan Pinar¹, Oguzhan Ozcan², Esin Dogan³, Gokhan Cakirca⁴

¹ Mustafa Kemal University, Faculty of Medicine, Department of Medical Pharmacology, Hatay, Turkey

² Mustafa Kemal University, Faculty of Medicine, Department of Biochemistry, Hatay, Turkey

³ Mustafa Kemal University, Faculty of Medicine, Department of Biochemistry, Hatay, Turkey

⁴ Sanliurfa Mehmet Akif Inan Training and Research Hospital, Department of Biochemistry, Sanliurfa, Turkey

Copyright © 2019 by authors and Annals of Medical Research Publishing Inc.

Abstract

Aim: We evaluated the protective effects of dexpanthenol (Dxp) in rats with gentamicin (Genta)-induced nephrotoxicity by assessing a panel of biochemical and histopathologic parameters.

Material Methods: Forty rats were divided randomly into the following four groups: Control group, physiological saline solution (0.5 cc intraperitoneally (i.p.) for 8 days; Dxp group, Dxp (500 mg/kg i.p.) for 8 days; Genta group, Genta (100 mg/kg, i.p.) for 8 days; and Genta+Dxp group, Genta and Dxp (100 and 500 mg/kg i.p., respectively) for 8 days.

Results: In the Genta group, the urea, creatinine, tumor necrosis factor- α (TNF- α), total oxidant status (TOS), oxidative stress index (OSI) and malondialdehyde (MDA) levels were significantly higher and the catalase (CAT) and glutathione peroxidase (GSH-Px) activities were significantly lower than those in the control group. In the Genta+Dxp group, the urea, creatinine, and TNF- α , TOS, OSI and MDA levels were significantly lower and the CAT and GSH-Px activities were significantly higher than those in the Genta group. Histopathological investigation showed severe tubular necrosis in the Genta group, which was of lesser severity in the Genta+Dxp group.

Conclusion: The biochemical and histopathologic results of this study indicate that Dxp can ameliorate Genta-induced nephrotoxicity.

Keywords: Oxidative stress; antioxidant; gentamicin; nephrotoxicity; dexpanthenol.

INTRODUCTION

Gentamicin (Genta) is an aminoglycoside antibiotic frequently used against infections caused by Gram negative bacteria. However, clinical use of Genta is limited by its nephrotoxicity and ototoxicity (1). High doses of Genta cause nephrotoxicity due to its accumulation in epithelial cells of the proximal renal tubules (2). Genta in rats leads to histopathological alterations such as edema, basal membrane interruption, apoptosis, and tubular necrosis (3). The mechanism of Genta-induced nephrotoxicity is unclear but involves a number of factors including reactive oxygen species (ROS), inflammation, and apoptosis (4,5). Increased production of ROS, depressed antioxidant defenses, and excessive levels of proinflammatory cytokines play a key role in the pathogenesis of Genta-induced nephrotoxicity (6,7). Thus, various antioxidants and anti-inflammatory

agents have been used to treat or prevent Genta-induced nephrotoxicity (8,9).

Dexpanthenol (Dxp), an alcohol derivative of pantothenic acid (PA), is oxidized to PA in tissues; this increases glutathione, coenzyme-A, and ATP synthesis (10). Dxp plays an important role in both cellular defense against oxidative stress and the inflammatory response (11,12). Hence, we investigated the antioxidant and anti-inflammatory effects of Dxp in rats with Genta-induced nephrotoxicity by assessing a panel of biochemical and histopathological parameters.

MATERIAL and METHODS

Chemicals

Genta sulfate (Genta ampoule 80 mg, I.E. Istanbul, Turkey) and Dxp (Bepanthen ampoule 500 mg/2 mL, Bayer) were used in this study.

Received: 26.07.2019 **Accepted:** 25.09.2019 **Available online:** 30.09.2019

Corresponding Author: Neslihan Pinar, Mustafa Kemal University, Faculty of Medicine, Department of Medical Pharmacology, Hatay, Turkey, **E-mail:** drnesli01@gmail.com

Animals

Forty male Wistar albino rats weighing 250–300 g were used in this study. The Mustafa Kemal University Experimental Animals Local Ethics Committee approved the study (Approval No., 2015/5-4). The experiment was carried out in Mustafa Kemal University Experimental Researches Application and Research Center, Hatay, Turkey. The rats were fed ad libitum and housed in appropriate cages, each containing five rats. The rats were exposed to a 12/12 h light/dark cycle at 20–22°C and 50–55% humidity.

Experimental Design

Forty rats were divided into four groups. Physiological saline was injected (0.5 mL intraperitoneally (i.p.) for 8 days to the rats in the control group. Dxp (500 mg/kg i.p.) was injected for 8 days to the rats in the Dxp group (13,14). The rats in the Genta group received injections of Genta (100 mg/kg i.p.) for 8 days (15). The rats in the Genta+Dxp group were injected with Genta and Dxp (100 and 500 mg/kg i.p., respectively) for 8 days.

Twenty-four hours after the last injection, the rats were anesthetized with ketamine hydrochloride (60 mg/kg i.p.) and xylazine hydrochloride (10 mg/kg i.p.), subjected to intracardiac blood sampling, and decapitated. A midline abdominal incision was made, and the left kidney was removed and transferred to the laboratory in 10% neutral formaldehyde solution in a closed labeled bottle for histopathological evaluation. The right kidney was removed, covered with labeled aluminum foil, and transferred in liquid nitrogen to the biochemistry laboratory. Blood samples were centrifuged at 1,500 rpm for 10 minutes and serum samples were stored at –80°C until required. The biochemical parameters assessed were the serum urea, creatinine, total antioxidant status (TAS), total oxidant status (TOS), and tumor necrosis factor-alpha (TNF- α) levels. The malondialdehyde (MDA) level, catalase (CAT) activity, and glutathione peroxidase (GSH Px) activity in renal tissue were also evaluated.

Biochemical Analysis

The TOS and TAS levels were determined by the method of Erel (16,17). The oxidative stress index (OSI) was defined as

the TOS to TAS ratio. The serum levels of urea, creatinine, Na, and K were measured spectrophotometrically using an Architect c8000 analyzer (Abbott Diagnostics). The serum TNF- α level was measured using an enzyme-linked immunosorbent assay kit (Awareness Technology Inc. Chromate ELISA) and expressed as pg/mL protein. CAT activity was evaluated by the method of Aebi (18). GSH-Px activity was measured according to the recommendations of Paglia and Valentine (19). The MDA level was evaluated by the method of Draper and Hadley (20).

Histopathological Analysis

Renal tissue samples were fixed in 10% neutral formaldehyde solution and embedded in paraffin. Paraffin sections (4 μ m thickness) were cut using a microtome and stained with hematoxylin and eosin. The sections were visualized using a light microscope. Tubular necrosis, tubular degeneration, congestion, tubular hypertrophy, and perivascular inflammation were evaluated by light microscopy. A predetermined scoring system was used for histopathologic evaluation (21). Tissue damage was scored as follows: +, slight; ++, moderate; and +++, severe.

Statistical analysis

Statistical analyses were performed using SPSS ver. 21 (SPSS Inc., Chicago, IL, USA). The values are expressed as mean \pm SEM. The groups were compared by one-way analysis of variance (ANOVA) followed by Tukey's test. A value of $p < 0.05$ was considered indicative of statistical significance.

RESULTS

Biochemical results

The results of the oxidative stress and biochemical parameters in rats with Genta-induced nephrotoxicity are shown in Table 1 and 2. The urea, creatinine and TNF- α levels were significantly higher in the Genta group than in the control group and were significantly lower in the Genta+Dxp group than in the Genta group ($p < 0.05$). The serum Na level did not differ significantly among the groups, but the serum K level was significantly lower in the Genta+Dxp group than in the Dxp group ($p < 0.05$) (Table 1).

Table 1. Effects of dexpanthenol (Dxp) on biochemical parameters

Parameters	Control	Dxp	Genta	Genta+Dxp
TNF- α (pg/mL protein)	115.5 \pm 8.1	335.8 \pm 84.8	899.3 \pm 181.3*	386.3 \pm 65.4**
Urea (mg/dL)	20.3 \pm 0.25	20.7 \pm 0.37	130.8 \pm 29.8*	61.9 \pm 11.9**
Creatinine (mg/dL)	0.5 \pm 0.01	0.49 \pm 0.0	2.55 \pm 0.6*	1.04 \pm 0.24**
Na (mmol/L)	135.5 \pm 1.4	138.2 \pm 0.4	134.7 \pm 1.57	139.1 \pm 0.89
K (mmol/L)	5.67 \pm 0.3	5.72 \pm 0.17	5.32 \pm 0.27	4.6 \pm 0.21***

Data were expressed as Mean \pm SEM. TNF- α : Tumor necrosis factor-alpha, Na: Sodium, K: Potassium.
 * $p < 0.05$ vs. Control group
 ** $p < 0.05$ vs. Genta group
 *** $p < 0.05$ vs. Dexa group

The TOS, OSI and MDA levels were higher in the Genta group than in the control group and were significantly lower in the Genta+Dxp group than in the Genta group ($p < 0.05$). However, the TAS did not differ significantly among the four groups ($p > 0.05$). The CAT and GSH-Px levels were lower in the Genta group than in the control group and were significantly higher in the Genta+Dxp group than in the Genta group ($p < 0.05$) (Table 2).

Histological results

The renal tissues were histopathologically evaluated

for tubular necrosis, tubular degeneration, glomerular atrophy and hypertrophy, and perivascular inflammation. The control and Dxp groups had normal renal tissue (Figure 1A and 1B). The rats in the Genta group had marked proximal tubular necrosis, tubular degeneration, perivascular inflammation (interstitial nephritis and pyelonephritis), and marked glomerular hypertrophy (Figure 1C). The rats in the Genta+Dxp group showed mild tubular necrosis, glomerular atrophy, and perivascular inflammation and moderate tubular degeneration and glomerular hypertrophy (Figure 1D).

Table 1. Effects of dexpanthenol (Dxp) on biochemical parameters

Parameters	Control	Dxp	Genta	Genta+Dxp
TAS ($\mu\text{mol Trolox Eq/g protein}$)	0.92 \pm 0.07	0.94 \pm 0.03	0.86 \pm 0.07	0.98 \pm 0.03
TOS ($\mu\text{mol H}_2\text{O}_2 \text{ Eq/ g protein}$)	12.6 \pm 1.00	16.9 \pm 2.00	31.5 \pm 4.84*	19.4 \pm 2.28**
OSI (H2O2/Trolox)	1.39 \pm 0.14	1.92 \pm 0.24	3.65 \pm 0.49*	1.98 \pm 0.22**
MDA	0.46 \pm 0.02	0.45 \pm 0.02	1.05 \pm 0.04*	0.71 \pm 0.03**
CAT	0.07 \pm 0.00	0.07 \pm 0.02	0.03 \pm 0.00*	0.04 \pm 0.00**
GSH- Px	0.32 \pm 0.01	0.30 \pm 0.01	0.18 \pm 0.00*	0.23 \pm 0.01**

Data were expressed as Mean \pm SEM. TAS: Total antioxidant status, TOS: Total oxidant status, OSI: Oxidative stress index, MDA: Malondialdehyde, CAT: Catalase, GSH Px: glutathione peroxidase.

* $p < 0.05$ vs. Control group

** $p < 0.05$ vs. Genta group

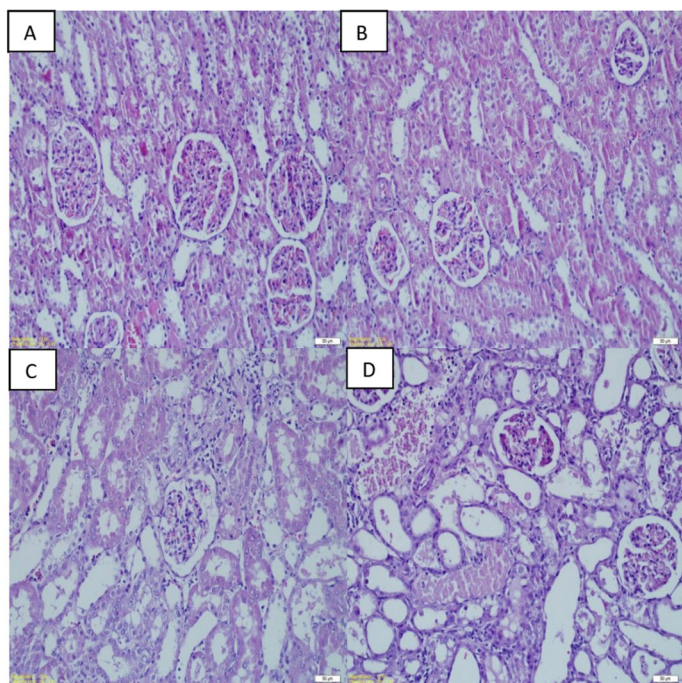


Fig. 1: H&E stained sections showing histopathologic effect of dexpanthenol on the renal changes induced by Genta.

A. Renal tissue in the control group (x200).

B. Renal tissue administered with dexpanthenol (500 mg/kg) (x200).

C. Renal tissue administered with Genta (100 mg/kg) (x200).

D. Renal tissue administered with Genta + dexpanthenol (x200), (H & E).

DISCUSSION

We evaluated the protective effect of Dxp on Genta induced nephrotoxicity. The results showed that Dxp ameliorated the renal injury caused by high-dose Genta by decreasing oxidative stress and the inflammation.

Clinical use of aminoglycosides is restricted by their nephrotoxicity, which is caused by generation of ROS (5). In renal pathology, NADPH oxidases, together with the mitochondrial respiratory chain, are the major sources of ROS such as the superoxide anion ($\text{O}_2^{\cdot-}$), hydrogen peroxide (H_2O_2), and the hydroxyl radical ($\cdot\text{OH}$) (22). Abnormal production of ROS leads to cellular injury and necrosis by inducing membrane lipid peroxidation, protein denaturation, and damage to DNA. The changes in renal function caused by lipid peroxidation are considered to be the initial event in the Genta-induced nephrotoxicity injury cascade (5,23). Genta increases ROS production, reduces the antioxidant capacity, and increases lipid peroxidation (24,25). Genta-induced renal injury can be prevented by various agents (6,9). In this study, we investigated for the first time the therapeutic effects of Dxp, which has antioxidant and anti-inflammatory activity, on Genta-induced nephrotoxicity.

Genta causes nephrotoxicity by decreasing the glomerular filtration rate and increasing the serum urea and creatinine levels (26,27). In our study, Genta led to a significant

increase in the serum urea and creatinine levels, whereas Genta+Dxp induced a significant decrease in the serum urea and creatinine levels. These results suggest a role for Dxp in preventing Genta-induced nephrotoxicity.

Inflammatory reactions, which are characterized by leukocyte infiltration into the injury site, increase the production of proinflammatory cytokines, such as TNF- α , and activation of nuclear factor- κ B, also play an important role in the nephrotoxicity of Genta (5,28). In our study, the TNF- α level was significantly higher in the Genta group and significantly lower in the Genta+Dxp group compared to the Genta group. Thus, the anti-inflammatory activity of Dxp suppressed renal inflammation.

Excess ROS production caused by the nephrotoxic effect of Genta damages cells by interacting with membrane lipids. MDA is a product of lipid peroxidation by ROS (22). In our study, as in prior reports, Genta led to a significant increase in the MDA level (29,30). In contrast, the MDA level was significantly lower in the Genta+Dxp group compared to the Genta group.

GSH-Px and CAT are enzymatic antioxidants that protect cells against the negative effects of free radicals, for example, by converting H₂O₂ into H₂O (31). In this study, the GSH-Px and CAT activities were lower in the Genta group than in the control group, as reported previously (23,26). On the other hand, GSH-Px and CAT activities were higher in the Genta+Dxp group than in the Genta group.

We also measured the TAS, TOS, and OSI to evaluate the oxidant and antioxidant status in Genta-induced nephrotoxicity. The TOS and the OSI value were significantly higher in the Genta group compared to the control group; this increase was reversed by simultaneous administration of Dxp with Genta. These results indicate that Dxp reduces the level of oxidative stress induced by Genta. Collectively, our results showed that Dxp administration increases the activities of GSH-Px and CAT and decreases the TOS and the OSI value and the level of MDA. This effect is likely to be mediated by the antioxidant activity of Dxp, which protects the kidney against free oxygen radicals. Similarly, Dxp protected against ischemia-reperfusion-induced renal injury in rats (32,33). Thus, Dxp has antioxidant activity and reduces the generation of free radicals.

Genta-induced nephrotoxicity is morphologically characterized by proximal tubule epithelial desquamation, epithelial edema, glomerular congestion, necrosis, and tubular casts (34). In this study, the renal tissue of the rats in the Genta group exhibited marked glomerular hypertrophy, perivascular inflammation, congestion, tubular degeneration, and tubular necrosis. Thus, Genta induced severe renal injury. In the Genta+Dxp group, however, Genta induced moderate renal injury, suggesting that Dxp ameliorated the tubular injury caused by Genta. Also, the histopathological changes were consistent with the biochemical findings.

CONCLUSION

Our results showed that Genta-induced nephrotoxicity in rats was ameliorated by the anti-inflammatory and antioxidant effects of Dxp. We believe that Dxp can be used safely in clinical practice to prevent Genta-induced kidney damage. However, further studies of the protective effect of Dxp on Genta-induced nephrotoxicity are required.

Acknowledgments

This work was presented at the 28th National and 1. International Biochemistry Congress, Erzurum, 2017.

Competing interests: The authors declare that they have no competing interest.

Financial Disclosure: This research was supported by a grant from Mustafa Kemal University Research Fund (14300/2015).

Ethical approval: The Mustafa Kemal University Experimental Animals Local Ethics Committee approved the study (Approval No., 2015/5-4).

*Neslihan Pinar ORCID:0000-0001-5863-9665
Oguzhan Ozcan ORCID:0000-0001-7486-503X
Esin Dogan ORCID:0000-0002-5242-2753
Gokhan Cakirca ORCID:0000-0003-1526-5899*

REFERENCES

- Quiros Y, Vicente-Vicente L, Morales AI, et al. An integrative overview on the mechanisms underlying the renal tubular cytotoxicity of gentamicin. *Toxicol Sci* 2011;119: 245–56.
- Nagai J, Takano M. Molecular aspects of renal handling of aminoglycosides and strategies for preventing the nephrotoxicity. *Drug Metab Pharmacokinet* 2004;19:159-70.
- De Souza VB, Oliveira RFL, Lucena HF, et al. Gentamicin induces renal morphopathology in wistar rats. *Int J Morphol* 2009;27:59-63.
- Lee KE, Kim EY, Kim CS, et al. Macrophage-stimulating protein attenuates gentamicin-induced inflammation and apoptosis in human renal proximal tubular epithelial cells. *Biochem Biophys Res Commun* 2013;434:527–33.
- Balakumar P, Rohilla A, Thangathirupathi A. Gentamicin induced nephrotoxicity: Do we have a promising therapeutic approach to blunt it? *Pharmacol Res* 2010;62:179-86.
- Fouad AA, Albuali WH, Zahran A, et al. Protective effect of naringenin against gentamicin-induced nephrotoxicity in rats. *Environ Toxicol Pharmacol* 2014;38:420-9.
- El-Kashef DH, El-Kenawi AE, Suddek GM, et al. Protective effect of allicin against gentamicin-induced nephrotoxicity in rats. *Int Immunopharmacol* 2015;29:679-86.
- Abuelezz SA, Hendawy N, Abdel Gawad S. Alleviation of renal mitochondrial dysfunction and apoptosis underlies the protective effect of sitagliptin in gentamicin-induced nephrotoxicity. *J Pharm Pharmacol* 2016;68:523-32.
- Aygün FO, Akçam FZ, Kaya O, et al. Caffeic acid phenethyl ester modulates gentamicin-induced oxidative nephrotoxicity in kidney of rats. *Biol Trace Elem Res* 2012;145:211–6.
- Slyshenkov VS, Dymkowska D, Wojtczak L. Pantothenic acid and pantothenol increase biosynthesis of glutathione by boosting cell energetics. *FEBS Lett* 2004;569:169-72.
- Doğan EE, Erkoç R, Ekinci İ, et al. Protective effect of dexpanthenol against nephrotoxic effect of amikacin: An experimental study. *Biomed Pharmacother* 2017;89:1409-14.
- Li-Mei W, Jie T, Shan-He W, et al. Anti-inflammatory and anti-oxidative effects of dexpanthenol on lipopolysaccharide

- induced acute lung injury in mice. *Inflammation* 2016;39:1757-63.
13. Ermiş H, Parlakpınar H, Gulbaş G, et al. Protective effect of dexpanthenol on bleomycin-induced pulmonary fibrosis in rats. *Naunyn Schmiedebergs Arch Pharmacol* 2013;386:1103-10.
 14. Cagin YF, Parlakpınar H, Vardi N, et al. Effects of dexpanthenol on acetic acid-induced colitis in rats. *Exp Ther Med* 2016;12:2958-64.
 15. Polat A, Parlakpınar H, Tasdemir S, et al. Protective role of aminoguanidine on gentamicin-induced acute renal failure in rats. *Acta Histochem* 2006;108:365-71.
 16. Erel O. A novel automated method to measure total antioxidant response against potent free radical reactions. *Clin Biochem* 2004;37:112-9.
 17. Erel O. A new automated colorimetric method for measuring total oxidant status. *Clin Biochem* 2005;38:1103-11.
 18. Aebi H. Catalase in vitro. *Methods Enzymol* 1984;105:121-6.
 19. Paglia DE, Valentine WN. Studies on the quantitative and qualitative characterization of erythrocyte glutathione peroxidase. *J Lab Clin Med* 1967;70:158-69.
 20. Draper HH, Hadley M. Malondialdehyde determination as index of lipid-peroxidation. *Methods Enzymol* 1990;186:421-31.
 21. Ouédraogo M, Lamien-Sanou A, Ramdé N, et al. Protective effect of *Moringa oleifera* leaves against gentamicin-induced nephrotoxicity in rabbits. *Exp Toxicol Pathol* 2013;65:335-9.
 22. Ratliff BB, Abdulmahdi W, Pawar R, et al. Oxidant mechanisms in renal injury and disease. *Antioxid Redox Signal* 2016;25:119-46.
 23. Parlakpınar H, Tasdemir S, Polat A, et al. Protective role of caffeic acid phenethyl ester (CAPE) on gentamicin-induced acute renal toxicity in rats. *Toxicology* 2005;207:169-77.
 24. Kandemir FM, Ozkaraca M, Yildirim BA, et al. Rutin attenuates gentamicin-induced renal damage by reducing oxidative stress, inflammation, apoptosis, and autophagy in rats. *Ren Fail* 2015;37:518-25.
 25. Abdelsameea AA, Mohamed AM, Amer MG, et al. Cilostazol attenuates gentamicin-induced nephrotoxicity in rats. *Exp Toxicol Pathol* 2016;68:247-53.
 26. Abdel-Raheem IT, Abdel-Ghany AA, Mohamed GA. Protective effect of quercetin against gentamicin-induced nephrotoxicity in rats. *Biol Pharm Bull* 2009;32:61-7.
 27. Sardana A, Kalra S, Khanna D, et al. Nephroprotective effect of catechin on gentamicin-induced experimental nephrotoxicity. *Clin Exp Nephrol* 2015;19:178-84.
 28. Bae EH, Kim IJ, Joo SY, et al. Renoprotective effects of the direct renin inhibitor aliskiren on gentamicin-induced nephrotoxicity in rats. *J Renin Angiotensin Aldosterone Syst* 2014;15:348-61.
 29. El-Kashef DH, El-Kenawi AE, Suddek GM, et al. Flavocoxid attenuates gentamicin induced nephrotoxicity in rats. *Naunyn Schmiedebergs Arch Pharmacol* 2015;388:1305-15.
 30. Boroushaki MT, Asadpour E, Sadeghnia HR, et al. Effect of pomegranate seed oil against gentamicin-induced nephrotoxicity in rat. *J Food Sci Technol* 2014;51:3510-4.
 31. Özcan O, Erdal H, Çakırca G, et al. Oxidative stress and its impacts on intracellular lipids, proteins and DNA. *J Clin Exp Invest* 2015;6:331-6.
 32. Altintas R, Parlakpınar H, Beytur A, et al. Protective effect of dexpanthenol on ischemia-reperfusion-induced renal injury in rats. *Kidney Blood Press Res* 2012;36:220-30.
 33. Sen H, Deniz S, Yedekci AE, et al. Effects of dexpanthenol and N-acetylcysteine pretreatment in rats before renal ischemia/reperfusion injury. *Ren Fail* 2014;36:1570-4.
 34. Lakshmi BVS, Sudhakar M. Protective effect of *Zingiber officinale* on gentamicin induced nephrotoxicity in rats. *Int J Pharmacol* 2010;6:58-62.