

# Complications of 200 cervical anterior surgery cases and the management of these complications in light of the literature

Necati Kaplan<sup>1</sup>, Fatma Bahar Hacıoğlu Kasım<sup>2</sup>, Ozkan Özger<sup>3</sup>, Numan Karaarslan<sup>4</sup>

<sup>1</sup> Istanbul Rumeli Univesity, Corlu Reyap Hospital, Department of Neurosurgery, Tekirdag, Turkey

<sup>2</sup> Republic of Turkey, Ministry of Health, State Hospital, Department of Radiology, Tekirdag, Turkey

<sup>3</sup> Medicalpark Anadolu Hospital, Department of Neurosurgery, Canakkale, Turkey

<sup>4</sup> Namik Kemal Univesity Faculty of Medicine, Department of Neurosurgery, Tekirdag, Turkey

Copyright © 2019 by authors and Annals of Medical Research Publishing Inc.

## Abstract

**Aim:** The aim of this retrospective study was to evaluate the possible complications and the complication management of cervical anterior discectomies and fusions in light of the literature.

**Materials and Methods:** The study population consisted of patients who presented to the clinic with neck pain and/or arm pain, loss of strength, and sensory disturbances who were operated on after a lack of response to conservative/medical treatment. This study included 200 cervical discopathy and/or cervical spondylosis cases. The literature review was performed according to the Preferred Reporting Items for Systematic Reviews and Meta-analyses guidelines without language or country restrictions.

**Results:** The most common complication was dysphagia. The complications also included dural tears, cerebrospinal fluid leakage, graft extrusions, neurological deterioration, postoperative hematomas, and recurrent laryngeal nerve injuries. These were found to be consistent with the literature.

**Conclusion:** In order to minimize the incidence of complications, the preoperative clinical examinations and radiological imaging of each patient should be examined carefully, and the appropriate surgical planning should be performed. It is also important to comply with the rules of asepsis and antisepsis, make sure the surgical time is as short as possible, and perform a dissection based on the patient's anatomy with the appropriate surgical equipment. In addition, it is important to wash the surgical area frequently, drain the system at the end of the operation, close the tissues in accordance with anatomical integrity, and perform close clinical follow-ups.

**Keywords:** Anterior cervical discectomy and fusion; cervical degenerative disc disease; complications; management of complications

## INTRODUCTION

An anterior cervical discectomy and fusion (ACDF) is a type of surgery involving the removal of a damaged disc with a total anterior intervention and the use of fusion material instead of the removed disc. Cervical discopathies can cause pain, sensory disorders, and weakness by compressing the spinal cord and spinal nerves. The purpose of an ACDF is to treat these symptoms by decompressing these structures.

Both anterior and posterior procedures have been described for the surgical treatment of radicular and myelopathic symptoms caused by cervical discopathies. However, anterior procedures are preferred

for the surgical treatment of cervical discopathies. Adding fusion to an anterior cervical discectomy prevents the formation of foraminal stenosis by preserving the height of the intervertebral disc; then, potential pressure on the spinal root is prevented. When a fusion is performed with a discectomy, dynamic instability and kyphotic deformation can be prevented (1).

The clinical results obtained from this procedure are usually good or excellent. However, rare complications may occur, leading to poor outcomes and management difficulties. The early diagnosis and proper management of any complications can prevent bad outcomes.

In our retrospective study, we have presented the early and late complications of ACDFs and the management

Received: 15.06.2019 Accepted: 16.07.2019 Available online: 30.09.2019

Corresponding Author: Numan Karaarslan, Namik Kemal Univesity Faculty of Medicine, Department of Neurosurgery, Tekirdag, Turkey

E-mail: numikara@yahoo.com

of these complications by comparing them in light of the literature.

## MATERIAL and METHODS

Our study included ACDF patients who presented to our clinic between April 2013 and April 2019. Written informed consent forms explaining the manner in which the surgical procedure would be performed and the complications and risks that may be encountered during the surgery were obtained from the patients before their operations.

The 200 patients (119 males and 81 females) included in our study were selected from those cervical discopathy/spondylosis patients who had undergone 1 to 4-level anterior micro discectomies and fusion surgeries. The ages of the patients ranged from 22 to 75 years old (mean: 54.2 years).

The cervical magnetic resonance imaging (MRI) results of all of the patients were examined preoperatively. Fifteen of the patients (7.5%) had computed tomography (CT) scans in addition to MRI scans. Twenty-two of the patients (11%) underwent electromyography studies before their surgeries. The anterior Smith-Robinson approach was used for all of the patients, and three neurosurgeons (Necati Kaplan, Numan Karaarslan, and Ozkan Ozger) were included in this study. The choice of the right or left side at the beginning of an ACDF depends on the surgeon's preference. A right sided approach was preferred in the patients who were included in our study. All of the surgeries were performed under general anesthesia while the patient was in a supine position with their head and neck supported with a silicone cushion. Autologous grafts or allografts were used in our series.

The patients' preoperative clinical examinations and necessary consultations before and after the surgeries were performed meticulously. On the 10<sup>th</sup> day, 1 month, 3 months, and six months after discharge, the follow-up clinical examinations were conducted. Undesirable results requiring additional treatments and longer hospitalizations were defined as complications.

A comprehensive and systematic literature search of numerous electronic databases was performed. A combination of key words was used to retrieve studies broadly associated with the topic of interest. In total, 335 studies, of which 53 were clinical studies, were retrieved using the keywords "anterior cervical discectomy and fusion", and "Surgical Technique". Later, 1197 studies, of which 130 were clinical studies, were extracted using the keyword "complications" alongside the foregoing keywords.

## RESULTS

### Surgical Technique

A right sided approach was selected for all of the patients who had ACDFs. In the patients with single level ACDFs, a skin incision was made parallel to the neckline at the level determined after fluoroscopy-guided leveling. In the

patients with 2 or more ACDF levels, the skin incision was made parallel to the SCM. Following the skin incision, the platysma was cut parallel to the incision.

The carotid artery was palpated, and the site was determined. The area between the esophagus and the carotid artery was explored, and the anterior of the vertebral corpus was reached. The longus colli was separated from the vertebral surfaces using scissors and bipolar.

The separators of the cervical retractors were placed in the space between the longus colli and the vertebrae, and the retraction was continued. After determining the desired level using C-arm fluoroscopy, a radical discectomy was performed. The residual disc and osteophytes that remained after the radical discectomy were thoroughly cleared via a microsurgical technique using a microscope, and the decompression was completed.

The fusion was carried out using a polyetheretherketone cage with demineralized bone matrix. Cervical plaque was applied in 11 patients with cervical kyphotic angulated spondylotic changes who underwent partial corpectomies. Wound drainage was used in all of the patients.

Most of the patients were discharged on the 2<sup>nd</sup> or 3<sup>rd</sup> day after the operation. Outpatient follow-ups were conducted on the 10<sup>th</sup> day after discharge. Then, during the 1<sup>st</sup>, 3<sup>rd</sup>, and 6<sup>th</sup> months, follow-ups were performed in the outpatient clinic. The patients were evaluated using a cervical x-ray 24 hours postoperatively and at the first outpatient follow-up. The cervical lordosis and cage conditions were evaluated.

### Patient Characteristics

The mean age of the ACDF patients was 54.2 years old (range: 22–75 years), and 40.5% of the patients were females. The female to male ratio was 6:10. ACDFs were performed at 260 disc levels in the patients who participated in our study. Neck pain and/or arm pain was present in all of the patients who participated in the study. In 19 patients (9.5%), there was a loss of strength with pain, and 5 patients (2.5%) had deep sensory disorders and upper motor neuron findings.

### Complications

Complications were seen in 19 of the 200 patients, and the overall complication rate was 9.5%.

### Dysphagia

Dysphagia was observed in 8 of the patients (4%) following their operations. These patients presented with mild dysphagia according to the scale proposed by Bazaz et al. (2).

One patient developed severe dysphagia due to graft extrusion and had to be operated on again. A total of 87.5% (7/8) of the patients with dysphagia were found to have survived the active complaints during the first

examination. Only one patient had moderate dysphagia, and at the postoperative first month examination, they complained of complete dysphagia.

### Dural Tear and Cerebrospinal Fluid Leak

In one patient in our series (0.5%), a small dural tear developed during the discectomy, and cerebrospinal fluid (CSF) leakage was observed. The dural rupture could not be sutured due to the narrow intervertebral space (not a corpectomy patient). Therefore, the dural rupture was closed using TISSEEL tissue glue (Baxter Healthcare Corporation, Deerfield, IL, USA). There was no drainage during the surgery that indicated a CSF flow from another location. In accordance with the anatomy, the tissue closure was waterproof. The patient had a brain tomography scan due to a headache, nausea, and vomiting the second day after the operation. The brain CT showed air images in the cistern and frontal lobes (Figure 1).

This patient underwent another operation to close the dural tear with gel foam 3 days after the first operation. After the second operation, the CSF leakage was treated conservatively, and acetazolamide was used to reduce the CSF. There was no appearance of a pseudomeningocele in the follow-up images.

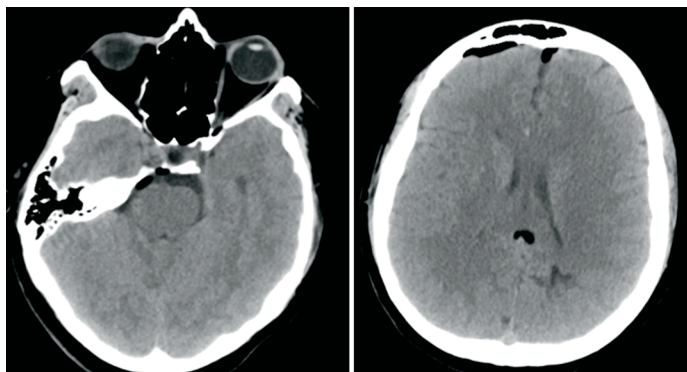
### Postoperative Hematoma

One patient (0.5%) had difficulty swallowing on the 7<sup>th</sup> postoperative day, and an MRI scan revealed a retropharyngeal hematoma (Figure 2). The patient was hospitalized, and conservative treatment was applied. No coagulopathy-related disorders were observed in the patient. Within 10 days, the complaint had disappeared completely.

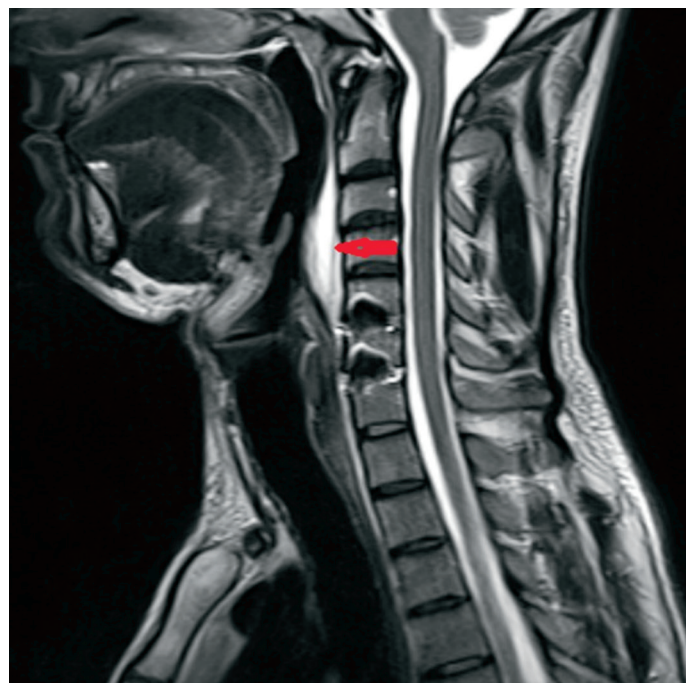### Laryngeal Nerve Palsy Causing Hoarseness

In total, during the postoperative period, hoarseness occurred in one patient. Unilateral vocal cord paralysis was determined via laryngoscopy after an ears, nose, and throat consultation. The patient was treated conservatively, and the hoarseness was completely resolved during the first follow-up visit.

### Esophageal Injury



**Figure 1.** Axial CT images revealed dense free air in the extra-axial region of the prepontine cistern, quadrigeminal cistern and bilateral frontal.

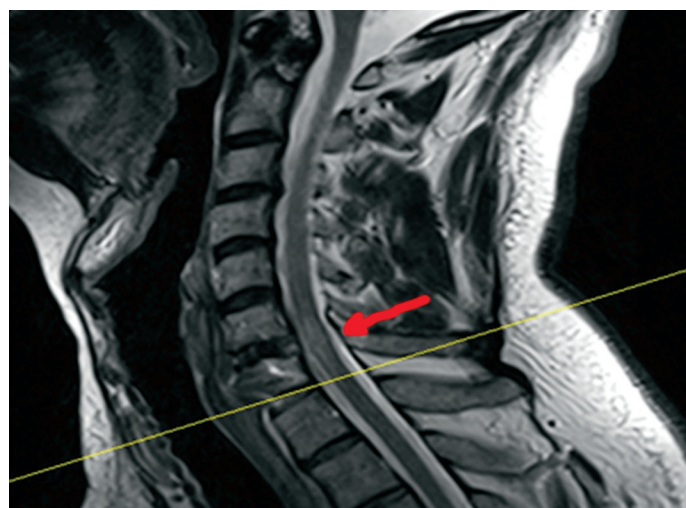

**Figure 2.** Sagittal T2W (A) images showed hyperintense soft tissue, consistent with retropharyngeal hematoma, narrowing the pharyngeal air column.

None of the patients in our series, including the patients who underwent cervical plaque revisions, had esophageal injuries.

### Worsening of the Neurological Clinical Condition

One patient presented to our clinic due to a C6-7 right sided protrusion, which led to right arm pain. The patient underwent a C6-7 micro discectomy and fusion. After the operation, there was a loss of strength and sensation on the patient's left side during the early postoperative period. The patient underwent an MRI scan, and a left-sided spinal cord contusion had developed at the operative level (Figure 3).



**Figure 3.** Sagittal T2W (A) images revealed an increase in signal and thickness in the spinal cord that was consistent with postoperative contusion at C 6 -7 disc level.

Intensive steroid therapy and physical therapy provided complete relief of the strength and sensation losses on the 7<sup>th</sup> day after the surgery. During the 1<sup>st</sup> month follow-up at the outpatient clinic, the patient had no complaints.

### **Graft Dislocation**

One patient who underwent stabilization with a 4-level ACDF and cervical plaque application presented again with difficulty swallowing due to cervical plaque removal 10 days after the surgery. The patient was reoperated on, and a cervical plaque revision was performed. Fifteen days after the second operation, the patient presented again with difficulty swallowing. An examination showed that the cervical plaque had come out of place again. The patient underwent a third reoperation, and the cervical plaque was completely removed. In the outpatient clinic, complete healing was seen in this patient.

### **Wound Site and Surrounding Tissue Infection**

No wound infections developed in any of our patients.

### **Mortality**

No deaths occurred in any of our patients after the cervical micro discectomies.

### **Other Complications**

One patient who had respiratory distress on the first postoperative day had a pulmonary thromboembolism and deep vein thrombosis in the right lower extremity. Anticoagulant treatment was initiated in this patient, and no further complications were observed.

### **Correlation between the Complications and the Number of Disc Levels Operated On**

The prevalence of dysphagia was higher in the patients who underwent 3-level ACDFs when compared to 1 or 2-level ACDFs ( $H \frac{1}{4} 12.89$ ,  $df \frac{1}{4} 3$ ,  $P \frac{1}{4} 0.05$ ; Kruskal-Wallis H test). There were no statistically significant differences in the incidence rates of the ACDF-treated levels in any of the complications other than dysphagia ( $P > 0.05$ ).

## **DISCUSSION**

In the literature, the ACDF complications included dysphagia, postoperative hematomas, esophageal ruptures, recurrent laryngeal nerve injuries, Horner syndrome, vascular structure damage, respiratory failure, pneumothorax, hemothorax, CSF leakage due to dural injuries, spondylodiscitis, bone graft extrusions, facial and hypoglossal nerve damage, and vertebral artery damage (3-11).

### **Dysphagia**

The rate of dysphagia was 4% in the patients included in our study, and it was observed more frequently in the patients who had ACDFs with 3 levels ( $P < 0.05$ ). In the studies by Fountas et al., the incidence of dysphagia in their study group was 9.5% (12,13). Robinson et al. reported this complication in 3.6% of their patients (14).

In their study, Bertalanffy et al. stated that dysphagia

occurs in every patient who undergoes an ACDF, and it should be seen as a normal result of this surgery (3). In general, in the literature, the incidence of dysphagia varied between 2% and 67%. In a recent study (15); the dysphagia rate 5.7% result was reported. The pathophysiological mechanism of dysphagia has not been fully elucidated; however, various explanations have been provided, including pharyngeal or esophageal edema due to intubation, retraction of the esophagus, postoperative soft tissue edema or hematoma, and finally, tissue adhesions in patients undergoing revision surgery. Smith-Hammond et al. reported that a lower cervical fusion and an advanced age were independent risk factors for postoperative dysphagia development (16). Dysphagia is a complication that can be cured most often by conservative treatment. However, there may be a surgical option that includes implant removal in the presence of prolonged dysphagia. In our series, one patient developed severe dysphagia due to a graft extrusion and had to be operated on again. The other patients with dysphagia in our series were managed conservatively with complete resolution of this symptom.

### **Hoarseness and Recurrent Laryngeal Nerve Palsy**

Postoperative hoarseness was present in 0.5% of the patients who underwent ACDF surgeries in our study. In the literature, the recurrent laryngeal nerve injury rate varied between 0.2% and 16.7% (17,18). The recurrent laryngeal nerve injury rate reported by Fountas et al. was 3.1% (13). The rate of recurrent laryngeal nerve injury reported by Fountas et al. was 3.1%. Robinson et al. reported a 7.1% incidence in the literature (14).

In our study, our patient recovered with conservative treatment, which was consistent with the literature. There were a number of studies in the literature that included permanent recurrent laryngeal nerve injuries after surgery. The proper placement of the retraction system and rigorous dissection play key roles in preventing this complication. A long intubation duration and a high endotracheal tube cuff pressure may also cause recurrent laryngeal nerve injuries, so this complication should be taken into account.

### **Postoperative Hematoma**

The occurrence of this complication can be life-threatening, and in some patients, it requires the immediate evacuation of the hematoma. Only one patient (0.5%) with a postoperative hematoma was seen in our series. This patient presented with dysphagia on the 7<sup>th</sup> postoperative day. Conservative treatment alone was provided, and the complication was cured. The incidence of this complication varied between 1% and 11% in the literature (13,19,20). On the postoperative 16<sup>th</sup> day, there were reports about the formation of a hematoma in one study (11). It is controversial to prevent this complication by using a closed drainage system that provides postoperative wound drainage. Fountas et al. reported postoperative hematomas in 5.6% of their patients. Similarly, the authors of another series reported this complication in 1.3% of their patients despite using a closed drainage system in all of the patients (3). **In another**

study (21); the rate of postoperative hematoma was reported as 7%. A preoperative closed drainage system was inserted in all of the patients in our series, and it was removed postoperatively on the 1<sup>st</sup> or 2<sup>nd</sup> day. With this complication, early detection and emergency hematoma drainage are important in terms of the mortality and morbidity incidences. During surgery, careful dissection, retraction, and hemostasis are very important to avoid this complication.

### **Esophageal Injury**

This is one of the most destructive complications of an ACDF, and it was reported in fatal cases in one previously reported series (13). There were no complications related to esophageal injuries in our series. No clear data were available in the literature on the incidence of esophageal injuries; however, the incidence of hypopharyngeal injuries varied between 0.2% and 7% (22). The importance of the early diagnosis of this complication cannot be underestimated. Care and attention to dissecting and retractor placement can help prevent this complication. Especially in high-risk patients (previous neck surgeries or longitudinal irradiation), more attention should be paid to these protection measures.

### **Neurological Deterioration**

In our study, only one patient had neurological deterioration (0.5%). Lied et al. (17) reported this complication in 1.2% of their patients. In two of their patients, the myelopathy worsened, one sustained brachialgia, and the other two developed radicular weakness. In another study, the rate of worsening myelopathy present in the post-ACDF cases was 0.2%, and after 12 months of conservative treatment, it was reported that cures were obtained in all of the cases (13). Choosing the appropriate case and appropriate surgery, avoiding excessive extension of the neck during intubation, and avoiding over-clearing of the osteophytes during surgery all help to protect against this complication. Transient Horner syndrome has also been reported in various series in the literature, ranging from 0.02% (13) to 0.2% (10). The careful and meticulous subperiosteal dissection of the longus colli from the vertebral surface can prevent this complication.

### **Graft Extrusion**

This complication occurred in only one of our patients (0.5%), and it was found to be reported at a lower rate in the literature than the previously reported incidence (20, 22). The preoperative measurement of the intervertebral disc height and the use of the fusion material appropriate for this measurement, as well as caring for the lordosis angle appropriate for the cervical plaque in our patients may be helpful for explaining the lower incidence of this complication than that in the literature. Fountas et al. reported that there was no graft extrusion in their series, and only one patient stated that one of the plate fixing screws was displaced 16 months after the operation (12,13).

### **Wound Infection**

None of our patients had wound infections (0%). In the literature, the incidence of this complication varied between 0.3% and 3% (3,10,13). Complying with the rules of sterilization during surgery, keeping the operation time as short as possible, loosening the retractors occasionally during the surgery, washing the surgical field frequently with saline, closing the surgical floors carefully in accordance with the anatomy, and paying attention to the postoperative wound care may all reduce the infection risk.

### **Dural Tear and CSF Leak**

Only one (0.5%) of our patients had a dural tear and CSF leakage, which correlated with the incidence rates of 0.2% to 1.8% reported in the literature (6,13). Working with microsurgical techniques, including radical discectomies, paying attention to the use of micro instruments, and being patient and attentive during the expansion of the posterior longitudinal ligament can prevent dural injuries and CSF leakage. In order to prevent a CSF fistula formation with a dural rupture, it is important to close the dural tear with fibrin tissue glue without creating pressure on the spinal root and neural structures. At the end of the operation, it is necessary to close the tissue layers appropriately and provide a waterproof seal according to the anatomical structure. A CSF path changer can be fitted with a closed drainage system.

### **Mortality**

There were no operation-related mortalities in the ACDF patients in our series. In the literature, the incidence ranged from 0.5% to 7.1%, but most of these deaths were due to nonsurgical medical complications (3). Fountas et al. reported mortality in their series secondary to an esophageal perforation and infection (13). The performing the required perioperative care and patience needed to complete the surgery, conducting the appropriate controls, and implementing the necessary medical treatments during the early postoperative period can minimize the mortality risk.

### **Limitations**

The limitations of this retrospective study are obvious. Although we analyzed the complications and management of patients who underwent ACDFs performed at a single center appropriately in this study, prospective or randomized studies may provide a more accurate estimation of the complication incidences.

### **CONCLUSION**

Although an ACDF is a safe and effective surgery for symptomatic cervical disc disease, one should consider the complications that may occur. When looking at the most common complications in our study, we saw postoperative dysphagia, dural injuries, hoarseness, graft extrusions, neurological deterioration, and hematomas. The selection of the appropriate surgical approach,

Careful perioperative planning, avoiding overextension of the neck during the procedure, the correct placement of the retractors, a rigorous microsurgical technique, careful hemostasis, an appropriate wound closure, and full compliance with aseptic measures will reduce the incidence of these complications. The necessity for an early diagnosis and the appropriate management of complications cannot be underestimated. Because there is no standardization in the definitions of preoperative and postoperative complications, our results may not be consistent with those of other studies. The main reason for this is that each center examines the causes of its complications and decreases the complication rate by taking appropriate measures. Based on the results of this study, we may conclude that an ACDF is a safe surgery with very low morbidity and mortality rates.

*Competing interests: The authors declare that they have no competing interest.*

*Financial Disclosure: There are no financial supports*

*Ethical approval: This is a retrospective study. Permission from Chief Physician to use data.*

*Necati Kaplan ORCID:0000-0001-5672-0566*

*Fatma Bahar Hacıoglu Kasım ORCID:0000-0002-3605-2350*

*Ozkan Ozger ORCID:0000-0001-7257-8379*

*Numan Karaarslan ORCID:0000-0001-5590-0637*

## REFERENCES

- Smith-Hammond CA, New KC, Pietrobon R, et al. Prospective analysis of incidence and risk factors of dysphagia in spine surgery patients: comparison of anterior cervical, posterior cervical, and lumbar procedures. *Spine* 2004;29:1441-6.
- Bazaz R, Lee MJ, Yoo JU. Incidence of dysphagia after anterior cervical spine surgery: a prospective study. *Spine* 2002;27:2453-8.
- Bertalanffy H, Eggert HR. Complications of anterior cervical discectomy without fusion in 450 consecutive patients. *Acta Neurochir* 1989;99:41-50.
- Burke JP, Gerszten PC, Welch WC. Iatrogenic vertebral artery injury during anterior cervical spine surgery. *Spine J* 2005;5:508-14, discussion 514.
- Cosgrove GR, Theron J. Vertebral arteriovenous fistula following anterior cervical spine surgery. Report of two cases. *J Neurosurg* 1987;66:297-9.
- Graham JJ. Complications of cervical spine surgery. A five-year report on a survey of the membership of the Cervical Spine Research Society by the Morbidity and Mortality Committee. *Spine* 1989;14:1046-50.
- Jellish WS, Jensen RL, Anderson DE, et al. Intraoperative electromyographic assessment of recurrent laryngeal nerve stress and pharyngeal injury during anterior cervical spine surgery with Caspar instrumentation. *J Neurosurg* 1999;91(2 Suppl):170-4.
- Jenis LG, Leclair WJ. Late vascular complication with anterior cervical discectomy and fusion. *Spine* 1994;19:1291-3.
- Karim A, Knapp J, Nanda A. Internal jugular venous thrombosis as a complication after an elective anterior cervical discectomy: case report. *Neurosurgery* 2006;59:E705, discussion E705.
- Klaerke A, Kroyer L, Lindeberg H, et al. Treatment of cervical disc disease using Cloward's technique. I. General results, effect of different operative methods and complications in 1,106 patients. *Acta Neurochir* 1984;70:97-114.
- Yu NH, Jahng TA, Kim CH, et al. Life-threatening late hemorrhage due to superior thyroid artery dissection after anterior cervical discectomy and fusion. *Spine* 2010;35:E739-42.
- Fountas KN, Kapsalaki EZ, Machinis T, et al. Extrusion of a screw into the gastrointestinal tract after anterior cervical spine plating. *J Spinal Disord Tech* 2006;19:199-203.
- Fountas KN, Kapsalaki EZ, Nikolakakos LG, et al. Anterior cervical discectomy and fusion associated complications. *Spine* 2007;32:2310-7.
- Pedram M, Castagnera L, Carat X, et al. Pharyngolaryngeal lesions in patients undergoing cervical spine surgery through the anterior approach: contribution of methylprednisolone. *Eur Spine J* 2003;12:84-90.
- Milavec H, Kellner C, Ravikumar N, et al. First Clinical Experience with a Carbon Fibre Reinforced PEEK Composite Plating System for Anterior Cervical Discectomy and Fusion. *J Funct Biomater* 2019; 10: E29.
- Robinson RA, Walker AE, Ferlic DC, et al. The results of anterior interbody fusion of the cervical spine. *J Bone Joint Surg Am* 1962;44:1569-87.
- Lied B, Sundseth J, Helseth E. Immediate (0-6 h), early (6-72 h) and late (>72 h) complications after anterior cervical discectomy with fusion for cervical disc degeneration; discharge six hours after operation is feasible. *Acta Neurochir* 2008;150:111-8, discussion 118.
- Morpeth JF, Williams MF. Vocal fold paralysis after anterior cervical discectomy and fusion. *Laryngoscope* 2000;110:43-6.
- Espersen JO, Buhl M, Eriksen EF, et al. Treatment of cervical disc disease using Cloward's technique. I. General results, effect of different operative methods and complications in 1,106 patients. *Acta Neurochir* 1984;70:97-114.
- Tew JM Jr, Mayfield FH. Complications of surgery of the anterior cervical spine. *Clin Neurosurg* 1976;23:424-34.
- Srikhande NN, Kumar VAK, Sai Kiran NA, et al. Clinical presentation and outcome after anterior cervical discectomy and fusion for degenerative cervical disc disease. *J Craniovertebr Junction Spine* 2019; 10: 28-32.
- Sonntag VKH, Klara P. Controversy in spine care. Is fusion necessary after anterior cervical discectomy? *Spine* 1996;21:1111-2.