

# Clinical and radiographic features of odontogenic keratocysts and evaluation of recurrence rates after treatment: A retrospective study

Bilal Ege<sup>1</sup>, Mehmet Demirkol<sup>2</sup>, Mustafa Yalcin<sup>3</sup>, Hilal Alan<sup>4</sup>

<sup>1</sup> Adiyaman University, Faculty of Dentistry, Department of Oral and Maxillofacial Surgery, Adiyaman, Turkey

<sup>2</sup> Gaziantep University, Faculty of Dentistry, Department of Oral and Maxillofacial Surgery, Gaziantep, Turkey

<sup>3</sup> Inonu University, Faculty of Dentistry, Department of Oral and Maxillofacial Surgery, Malatya, Turkey

Copyright © 2019 by authors and Annals of Medical Research Publishing Inc.

## Abstract

**Aim:** In this retrospective study, it was aimed to evaluate the clinical and pathological features of cases diagnosed with OKC and the recurrence status after treatment options.

**Material and Methods:** 41 patients who were treated with the diagnosis of OKC between December 2015-June 2018 and whose pre- and post-treatment follow-up data could be reached were included in the study. As the variables examined, age and gender of the patients, localization of cyst and radiographic features, histopathological findings, treatment methods and recurrence status were investigated retrospectively.

**Results:** Of 41 patients with a mean age of 36.68±17.89 (age range 13 to 78) years, 24 (58.5%) were males and 17 (41.5%) were females. It was determined that OKCs were observed most frequently in the third decades (21.9%) followed by the second and fourth decades (19.5%). The incidence of OKC was determined to be higher in the mandible (80.5%) than in the maxilla (19.5%). The recurrence was observed in 7 of 41 cases (17.1%) after the treatment. The recurrence was detected particularly in mandibular posterior and larger lesions. The fact that five of the seven recurrent cases were parakeratotic and likewise five cases were treated with enucleation was noteworthy.

**Conclusions:** The treatment and prognosis of OKC should be determined according to the condition of the case and the treatment protocol should be managed accordingly.

**Keywords:** Odontogenic cyst; odontogenic keratocyst; decompression; retrospective; recurrence.

## INTRODUCTION

Odontogenic cysts (OCs) are pathological cavities that are surrounded by epithelium, containing liquid or semi-solid material, and originating from the epithelial components of dental tissues. OCs are divided into two groups as developmental and inflammatory considering their origin (1). Odontogenic keratocysts (OKCs), one of developmental cysts, first defined by Mikulicz in 1956 and first described by Philipsen in 1876, are odontogenic cysts with intraosseous location, benign, uni or multilocular appearance, characteristically surrounded by a parakeratinized squamous epithelium (2).

OKCs usually grow in antero-posterior direction within the medullary cavity of the bone without significant expansion

(3). Therefore, when the diagnosis is made, the volume of the cyst can be quite large (4). This is also useful for clinicians in the differential diagnosis of other OCs, such as dentigerous, radicular cyst, which causes expansion in bone (3). While small-sized OKCs do not provide a significant clinical finding in early stages; with the enlargement of the size of the lesion, symptoms such as pain, swelling, bone perforation, displacement of adjacent teeth or resorption of roots, inferior alveolar paresthesia due to pressure on the mental nerve can also be seen (5).

Although OKCs can be seen at all ages, they are usually seen in males in the second and third decades of life and often in the mandibular molar and ramus regions; also rarely seen in the maxilla and other mandibular regions (6,7). While OKCs occur in the jaws on their own,

**Received:** 15.06.2019. **Accepted:** 06.07.2019 **Available online:** 01.10.2019

**Corresponding Author:** Bilal Ege, Adiyaman University, Faculty of Dentistry, Department of Oral and Maxillofacial Surgery, Adiyaman, Turkey, **E-mail:** miregein@gmail.com

they can also occur in multiple styles, like nevoid basal cell carcinoma syndrome (Gorlin Syndrome) in which an autosomal dominant transition is observed (3,8). Radiographically, they appear as smooth, radiopaque, well-demarcated, unilocular or multilocular radiolucency, and usually occur with impacted teeth (3).

OKCs have two histopathological types: orthokeratinized and parakeratinized. The parakeratinized type has been reported to demonstrate a higher rate of recurrence (9). In addition, it has been reported that parakeratinized cysts contain gp38, a specific glycoprotein found in basal cell carcinomas that are not found in normal tissues, and this supports the neoplastic potentials of the parakeratinized OKCs (10). Furthermore, it has been reported that these cysts can indicate malignant changes and p53 protein, which is not found in normal cells but detected in many malignant lesions, is clearly seen in OKCs compared to other odontogenic cysts (10,11). For this reason, it is reported that it is obligatory to perform histological examination as well as radiographic and clinical examinations in OKC diagnosis.

In the current literature, there is still no clear consensus in the planning of treatment. Treatment options vary depending on the size of the cyst, proximity to adjacent anatomical regions, recurrence tendency, or the difficulty of surgical intervention, but generally these include conservative approaches such as enucleation, decompression, marsupialization and/or enucleation; aggressive treatments such as segmental or marginal resection, cryotherapy and chemical curettage using Carnoy's solution (12,13).

The aim of this study was to examine retrospectively the demographic, clinical, radiographic features of 41 cases diagnosed with OKC, treated and/or followed-up, and the recurrence rates observed after the implementation of treatment methods in the light of the literature.

## **MATERIAL and METHODS**

Forty-one patients who were directly admitted to the Department of Oral and Maxillofacial Surgery at Adiyaman and Inonu Universities between December 2015 and June 2018 or who were referred from another hospital and diagnosed with OKC because of histopathological examination according to the latest classification by the World Health Organization in 2017 were included in this study. Histopathological, clinical and radiographic records of the patients were analyzed retrospectively.

All necessary clinical data including patient age and gender, histopathological findings, anatomic location of the cyst, radiographic features, treatment methods and recurrence were obtained from patient archives. Patients with more than one OKC due to the suspicion of basal cell nevus syndrome, patients whose follow-up information could not be reached, and patients who had previously been treated and had a follow-up of less than 12 months

were not included in the study. Prior to the first biopsy, informed consent form was obtained from all patients. All cases were evaluated clinically and radiographically regularly during the observation periods due to the possibility of a recurrence. The frequency of follow-up was every month during the first year after the operation; in the following year, it was at intervals of 3 months. In addition, routine control radiographs were taken from the patients at the 3rd, 6th and 12th months in the first postoperative year; once every 6 months in the second year; and once every year in the following years. Dental tomography was also used if needed and where necessary.

The anatomical distribution of the lesions in the jaws was performed by dividing each jaw into four regions. The areas of involvement were divided into distinct regions as anterior (between canine-canine), premolar, first-second molar and third molar-ramus for the mandible; as anterior (between canine-canine), premolar, first-second molar and third molar-maxillary sinus for the maxilla. The lesions involved in more than one area were defined as "multiple areas" (14). In the radiographic examination of the lesions, whether the lesion with unilocular and multilocular appearance had any relationship with the impacted tooth was evaluated.

Three types of treatment methods were implemented, including only decompression, enucleation and additional enucleation after decompression. In small-sized lesions, the cyst epithelium was removed by curettage with simple enucleation. Carnoy's solution was not used with enucleation. Decompression was performed by opening a window into the cystic cavity and creating a patient-specific personal apparatus or a drainage path, which is a treatment technique to reduce the cystic internal pressure. To keep the cystic cavity away from food remnants, patients were told to irrigate the inside of cavity at least twice a day. In cases treated with decompression alone, this procedure was continued until the entire cyst cavity was completely filled with new bone formation and the procedure was terminated when confirmed by radiographic controls. Similarly, in large-sized cysts and in cases where especially adjacent anatomical structures were affected by this condition, the size of the lesion was brought into a shape with decompression treatment that would not damage adjacent vital structures, and then the total removal of the lesion was aimed.

Among the variables examined in present study, demographic data such as age and gender of the patients, localization of cyst, histopathological subtype, radiographic appearance, presence of impacted teeth, treatment methods and presence of recurrence were recorded.

### **Statistical Analysis**

SPSS 18.0 package program was used for statistical analysis of data. Descriptive statistics were given as mean  $\pm$  standard deviation for continuous variables. The number of cases and % were used to express the variables.

## RESULTS

Of the 41 patients included in the study, 24 were males (58.5%), 17 were females (41.5%). The female/male ratio was 1:1.4. At the time of diagnosis, the patients' ages ranged from 13 to 78 years. (Mean, 36.68 ± 17.89). Considering the distribution according to age, it was determined that OKCs were observed most frequently in the third decades (21.9%) followed by the second and fourth decades (19.5%) of life. It was observed that while they were seen more frequently in males (12.2%) in the second and fourth decade, they were seen more frequently in females (14.6%) in the third decade (Table 1).

Age	Male (%)	Female (%)	Total (%)
0-9	0 (0)	0 (0)	0 (0)
10-19	5 (12.2)	3 (7.3)	8 (19.5)
20-29	3 (7.3)	6 (14.6)	9 (21.9)
30-39	5 (12.2)	3 (7.3)	8 (19.5)
40-49	2 (4.9)	2 (4.9)	4 (9.8)
50-59	4 (9.8)	2 (4.9)	6 (14.6)
60-69	3 (7.3)	0 (0)	3 (7.3)
70-79	2 (4.9)	1 (2.4)	3 (7.3)
<b>Total</b>	<b>24 (58.5)</b>	<b>17 (41.5)</b>	<b>41 (100)</b>

\*Mean age 36.68±17.89; ratio of female: male: 1:1.4

Considering the distribution of the lesions according to the localization on the jaws; 33 (80.5%) of the cases were located in the mandibular region. Of these, two (4.9%) were in the molar region, 3 (7.3%) were in the premolar region, 19 (46.3%) were in the 3rd molar and ramus region, and 9 (21.9%) were in at least two regions. No lesions were observed in the canine-canine region. Eight (19.5%) of the lesions were located in the maxilla. Of these, one (2.4%) case was located in the canine-canine and premolar region, 2 (4.9%) were located in the 3rd molar+sinus region and half of the cases (9.8%) were located in at least two regions. No lesion was detected in the molar region of the maxilla in contrast to the mandible (Table 2). The mandibula/maxilla ratio of the lesions was determined to be 4.1:1. It was observed that mandibular cysts were mostly located on the right side of the half jaw. Of the lesions, twenty were located on the right side of the half jaw, 12 were located on the left of the half jaw and one was located in bilateral area. Of the lesions, three were observed to be on the right and left sides in an equal number and two were seen to be located in bilateral areas in the maxilla (Figure 1).

	Canine-canine (%)	Premolar (%)	Molar region (%)	Third Molar+Sinus/Ramus (%)	Two regions (%)	Total (%)
<b>Maxilla</b>	1 (2.4)	1 (2.4)	0 (0)	2 (4.9)	4 (9.8)	8 (19.5)
<b>Mandible</b>	0 (0)	3 (7.3)	2 (4.9)	19 (46.3)	9 (21.9)	33 (80.5)
<b>Total</b>	1 (2.4)	4 (9.8)	2 (4.9)	21 (51.2)	13 (31.7)	41 (100)

Mandible/maxilla ratio: 4.1:1

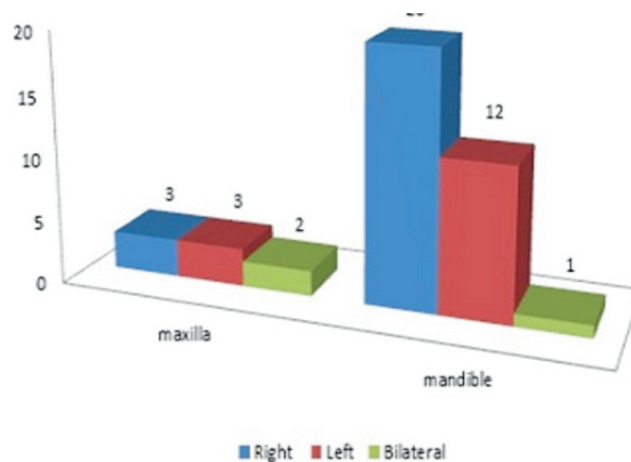


Figure 1. Placement of lesions in both jaws

Considering the radiographic appearance of the lesions; 26 (63.4%) of them had unilocular appearance and 19 of them were in the mandible; seven of them were located in the maxilla. The remaining 15 (36.6%) of the cases had multilocular appearance and 14 of them were in the mandible; only one of them was located in the maxilla. In addition, in the radiographic examination, a lesion was observed to be associated with impacted teeth in 15 patients (36.6%). Of these, 12 were seen in the mandible; 3 were seen in the the maxilla. In 26 cases, there were no impacted teeth (63.4%). Histopathologically, of the lesions, 16 (39%) were diagnosed as orthokeratinized (mandibular; n=11, maxilla; n=5); 25 (61%) were diagnosed as parakeratinized type (mandibular; n=22 / maxilla; n=3) (Table 3).

Considering the applied treatment methods, 17 (%41.5) of the cases were treated with enucleation, 14 of which were in the mandible, 3 of which were in the maxilla, while a total of 14 (34.1%) the cases were treated with decompression, 11 of which were in the mandible and 3 of which were in the maxilla. The remaining 10 cases (24.4%) were treated with decompression+enucleation, eight of which were in the mandible and two of which were in the maxilla (Table 4). While recurrence was observed in five of the cases treated with enucleation (29.4%), recurrence was observed in only 1 case (7.1% and 10%) in the other two treatment methods (Table 4, Figure 2). In addition, while five of these cases were parakeratinized and two of them were orthokeratinized type; 4 of them had unilocular appearance and 3 of them had multilocular appearance (Table 5). Finally, a detailed examination of the cases with recurrence was presented in Table 6.

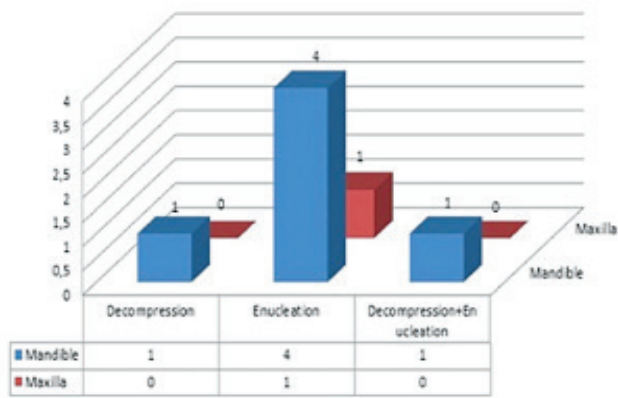


Figure 2. Treatment methods and recurrence rates

Table 3. Radiographic and histopathological characteristics of lesions

	Mandible (%)	Maxilla (%)	Total
<b>Radiographic examination</b>			
Uniloculated	19	7	26 (63.4)
Multiloculated	14	1	15 (36.6)
<b>Impacted tooth</b>	12	3	15 (36.6)
<b>Histopathological examination</b>			
Orthokeratinized	11	5	16 (39)
Paraceratinized	22	3	25 (61)

Table 4. Treatment methods and recurrence rates

Treatment	Lesions		Recurrences		Rate; %
	Mandible (n:33)	Maxilla (n:8)	Mandible	Maxilla	
Enucleation (n:17)	14	3	4	1	29.4
Decompression (n:14)	11	3	1	0	7.1
Decompression + Enucleation (n:10)	8	2	1	0	10
			18.2%	12.5%	

Table 5. Clinicopathological findings of lesions and its relationship with recurrence

	OKC		Total (%)
	No recurrence	Recurrent	
<b>Appearance</b>			
Uniloculated	22	4	26 (63.4)
Multiloculated	12	3	15 (36.6)
<b>Histopathological type</b>			
Orthokeratinized	14	2	16 (39)
Paraceratinized	20	5	25 (61)
<b>Impacted tooth</b>			
Available	15	0	15 (36.6)
Unavailable	19	7	26 (63.4)
<b>Treatment method</b>			
Enucleation	12	5	17 (41.5)
Decompression	13	1	14 (34.1)
Decompression+Enucleation	9	1	10 (24.4)
<b>Total</b>	34	7	41 (100)

OKC: Odontogenic keratocysts

Table 6. Descriptive information for recurrent cases

	Half of jaw	Localization	Histopathological type	Radiologic appearance	Treatment
Patient 1	Mandible	Molar	Orthokeratinized	Uniloculated	Enucleation
Patient 2	Mandible	Premolar	Paraceratinized	Uniloculated	Enucleation
Patient 3	Mandible	Third molar-ramus region	Paraceratinized	Multiloculated	Decompression
Patient 4	Mandible	Third molar/ ramus region	Paraceratinized	Multiloculated	Enucleation
Patient 5	Mandible	Least two regions	Paraceratinized	Uniloculated	Decompression+Enucleation
Patient 6	Mandible	Least two regions	Orthokeratinized	Multiloculated	Enucleation
Patient 7	Maxilla	Least two regions	Paraceratinized	Uniloculated	Enucleation

## DISCUSSION

The OKCs were classified as uni-multicystic odontogenic tumor by the World Health Organization (WHO) in 2005. They named odontogenic tumors under the name of "keratocystic odontogenic tumor" due to their aggressive behavior and recurrence characteristics (15). However, in 2017, the classification was repeated by the same organization, the lesion was again referred to as "Odontogenic Keratocyst", and it was regarded as a cystic formation (16). This retrospective study was conducted in accordance with WHO's recent classification in 2017.

OKCs are cysts in a wide age range and most frequently seen in the second and third decades of life (7,8,17,18). The mean age was reported as 41 in the study of Ahlfors et al (2); as 41.7 by Morganet et al (12); as 37 by Brannon et al (19). In this study, similarly to these data, cases were observed in a wide age range (13-78); the mean age was determined as 36.78 years. Myoung et al (8) reported that these cysts were observed most frequently in the third decade of life, followed by the second decade. However, there were studies indicating that OKCs were seen more frequently in the fifth and sixth decades of life (8,17,20). In this study, OKCs were observed most frequently in the third decade of life (21.9%), followed by second and fourth decades (19.5%).

There are studies conducted in different populations in the literature, and most of these cysts have been reported to be seen more frequently in males than females (6,21). Zhao et al (7) reported the ratio of female to male as 1:1.47 in the Iranian population by Habibi et al (6); as 1:1.96 in the Japanese population by Yagyuu et al (21); as 1:1.93. Akay et al (17) also reported this ratio as 1:2.2 in the Turkish population. It was reported as 1:1.42 by Myoung et al (8) and also as 1:1.4 by Lam et al (22). In this study, similarly to these two studies this ratio was determined as 1:1.4 in the Turkish population. In contrary to this, there are studies in the literature indicating that females are affected more frequently than males (23,24).

OKCs are often localized on the jaws in the posterior mandible and ramus region. It has been reported that this rate varies between 65% and 83% (6,7,15,19,22). However, unlike this situation, it was reported that Yagyuu et al (21) most frequently saw these cysts in the molar and premolar regions in the study of Myoung et al (8) and in the molar region. In this study, it was detected that OKCs were most frequently observed in the mandible (19.5%) than in the maxilla (80.5%), and the 3rd molar-ramus region was the most affected region (Table 2). Present results were observed to be consistent with the studies in the literature (6,12,17).

It is difficult to distinguish OKCs from some cysts and tumors because they are clinically and radiologically similar. Radiographically, it is often observed to be associated with impacted teeth (2, 25). It was stated that of OKCs, 33.7% (n=28) were associated with impacted teeth in the study of Habibi et al (6), 27.1% (n=16) by Yagyuu et al

(21), 35.3% (n=173) by Zhao et al (7). This ratio was (n=15; 36.5%) in line with the literature. Furthermore, it should be kept in mind that OKCs can be confused with dentigerous and radicular cysts due to their radiological appearance, and ameloblastoma or myxoma due to their scalloped margin structure and multilocular features (3,26).

Radiographically, the lesions are unilocular with 83.5% and multilocular with 16.5% (9). Buckley et al (27) reported that multilocular appearance was a predictor in the diagnosis of OKC by radiographic examination and was more determinant. Multilocular appearance was also known to be effective on recurrence. Yagyuu et al (21) reported recurrence in 5 (35.7%) of 14 multilocular lesions; but only in 2 of 27 unilocular lesions (7%). In present study, recurrence was observed three (20%) of 15 multilocular cases; in 4 of 26 unilocular cases (15.4%). As reported by Yagyuu et al (21), it may be associated with inadequate access to all cystic cavities, especially with multilocular types, and with remaining epithelial residues.

OKCs are divided into subtypes histopathologically as parakeratotic and orthokeratotic (28). Lam et al (22) stated that of cases, 82.6% were parakeratinized, 11.6% were orthokeratinized and the remaining 5.8% were mixed type. Similarly, Akay et al (17) also reported that parakeratinization was detected in 79.7% of the cases and a mixed histopathological image was determined in 20.3%. The fact that the majority of cases (61% parakeratotic and 39% orthokeratotic) are parakeratotic indicates that present results are consistent with the literature. Parakeratotic type constitutes the majority of these cysts (83-97%) and increases the likelihood of rapid growth and recurrence, and this sub-type has higher local destruction and expansion potential (26). The detection of new small satellite cysts by parakeratinization is another factor that increases the likelihood of recurrence, and it is recommended that patients in whom new cysts have been detected should be followed up for a long time. Myoung et al (8) reported histopathologically that the presence of one or more small satellite cysts was significantly associated with recurrence. Akay et al (17) reported that of nine recurrent cases, 7 were associated with parakeratotic and 4 were associated with small satellite cysts. In this study, no small satellite cysts were observed histopathologically, and recurrence was seen in five of 25 cases that were parakeratinized, while recurrence was seen in two of 16 cases that were orthokeratinized.

Recurrence rates of OKCs are observed in a wide range between 2.5% and 62.5% (8,12,16) and it has been reported that a large number of variables such as anatomical localization differences of the cyst, the presence or absence of infection, and the size of the associated teeth and lesion may affect the recurrence rate (13, 29). When the recurrence rate in both jaws was evaluated, Habibi et al (6) determined the distribution of mandibular/maxilla recurrence rate as 10.7% and 3.7%. Present distribution was found to be 18.2% in the mandible and 12.5% in the maxilla. This difference here may be possible due to differences among the number of cases seen in half jaws.

Akay et al (17) reported that individuals were under 30 years of age in five of the nine cases with recurrence. Similarly, Forssell et al (30) determined a higher recurrence rate in young patients. In present study, all of the cases with recurrence were observed in patients over 30 years of age. This condition may be more effective in that healing potential is higher and conservative methods are primarily preferred in young patients. Nevertheless, Woolgar et al (31) compared 228 non-recurrent and 44 recurrent OKC cases; while they detected no difference in terms of age, gender and localization among the cases and stated that operative factors had a much greater effect on the likelihood of recurrence.

There is still no clear consensus on the treatment of OKCs in the literature review (32). The treatment options of OKC vary from radical surgeries such as segmental resection to conservative approaches including simple enucleation or decompression (12,13,23). When determining the method to be applied in the treatment of OKCs, the cyst's characteristics such as the size, width, localization, histopathology, relationship with soft tissue, and recurrence of a lesion should be considered. Otherwise, it should be kept in mind that misdiagnosed or incomplete treatment methods may cause recurrence (31).

The simple enucleation without curettage is no longer recommended, since the capsule of the OKC is easily cleavable and fragile (33). Because, it was observed that the recurrence rate could reach up to 60% as a result of the incomplete enucleation and/or curettage (12,23). The recurrence rate was reported as 9.1% in 44 cases undergoing enucleation by Akay et al (17), in 29 of 163 patients (17.79%) by Zhao et al (7), in 7.6% of 66 patients by Habibi et al (6). Morgan et al (12) also determined this rate as 54.5%. In present study, 5 (29.4%) of 17 patients who underwent enucleation were seen with recurrence. In addition, these patients were also treated with enucleation. Due to the cyst epithelium cannot be completely removed; new cyst formation that formed with the remaining epithelial residues may be caused by this condition.

It has been indicated that the application of marsupialization and decompression can be successful in the treatment of large volume OKCs (33). Pogrel et al (34) observed complete improvement in both clinical and radiological aspects in all 10 patients who underwent marsupialization treatment. However, in a recent study, Marin et al (35) suggest that the decompression method used in the treatment of various jaw cysts is effective, but highly recommend that enucleation be performed after decompression in the treatment, especially in OKCs. Similarly, in the studies in which only decompression was performed, Akay et al (17) reported recurrence in five (41.7%) of 12 cases, and Habibi et al (6) reported recurrence in two (33.3%) of six cases. In this study, recurrence was observed in only one of 14 cases treated with decompression. The recurrence in cases in which decompression was applied, it may be developed that lesion extended between the roots of the teeth or remained residue in these regions as stated in the literature (29).

There are studies indicating that no recurrence has been encountered in the application of enucleation/curettage during decompression and follow-up (6,7). Zhao et al (7) did not indicate recurrence in 11 cases that treated with marsupialization after enucleation. In this study, recurrence was encountered in only 1 out of 14 patients (n=1/7) having undergone decompression and 10 patients (n=1/7) having undergone decompression alone while recurrence was observed at the rate of 29.4% (n=5/7) with enucleation. When the recurrence rates are evaluated according to the methods applied, the recurrence rates are consistent with the literature and that decompression can be used either alone or in combination with other methods. However, in order to get more clear results, we believe that the number of cases in each treatment group should be higher and distributed evenly. This is one of the limitations of current study.

The recurrence of recurrent OKCs is reported to be frequently observed in the first five to seven years after treatment (19,22,23,28,31). Similarly, Stoelinga stated that recurrence occurred mostly in 5 years, but it could be seen even after a long follow-up of 25 years (36). Lam et al (22) reported that they encountered the first recurrence in their study at the 19th month and that the parakeratinization of the cyst was effective. The recurrence was found to be in only two of 24 cases with OKC in this study. However, the mean follow-up period of these patients has not yet exceeded 5 years.

## CONCLUSIONS

Although many treatment procedures in the treatment of OKCs have been investigated in the literature but there is no single type of treatment method that completely eliminates the possibility of recurrence. Therefore, the treatment and prognosis of OKC should be determined according to the condition of the case and the treatment protocol should be managed accordingly.

*Competing interests: The authors declare that they have no competing interest.*

*Financial Disclosure: There are no financial supports*

*Ethical approval: This present study was reviewed in accordance to the Declaration of Helsinki on medical protocol and ethics. The necessary approval was obtained from Non-Interventional Ethics Committee of Inonu University (Decision number: 2019/6-14).*

*Bilal Ege ORCID: 0000-0002-1279-0893*

*Mehmet Demirkol ORCID: 0000-0003-1973-0364*

*Mustafa Yalcin ORCID: 0000-0003-2365-1909*

*Hilal Alan ORCID: 0000-0002-2063-4188*

## REFERENCES

1. Nuñez-Urrutia S, Figueiredo R, Gay-Escoda C. Retrospective clinicopathological study of 418 odontogenic cysts. *Med Oral Patol Oral Cir Bucal* 2010;15:e767-73.
2. Ahlfors E, Larsson A, Sjögren S. The odontogenic keratocyst: A benign cystic tumor? *J Oral Maxillofac Surg* 1984;42:10-9.
3. White SC, Pharoah MC. Oral radiology: principles and

- interpretation. 6th edition. St. Louis, Mosby, 2013;351-5.
4. Shear M. Odontogenic keratocyst: clinical features. *Oral Maxillofac Surg Clin North Am* 2003;15:335-45.
  5. Duman SB, Yasa Y, Ocak A. Keratocystic Odontogenic Tumor: Panoramic, Tomographic and Ultrasonographic Assessment. *EÜ Dişhek Fak Derg* 2015;36:52-5.
  6. Habibi A, Saghravanian N, Habibi M, et al. Keratocystic odontogenic tumor: A 10-year retrospective study of 83 cases in an Iranian population. *J Oral Sci* 2007;49:229-35.
  7. Zhao YF, Wei JX, Wang SP. Treatment of odontogenic keratocysts: A follow-up of 255 Chinese patients. *Oral Surg Oral Med Oral Pathol Oral Radiol Endod* 2002;94:151-6.
  8. Myoung H, Hong S. Odontogenic keratocyst: Review of 256 cases for recurrence and clinopathologic parameters. *Oral Surg Oral Med Oral Pathol Oral Radiol Endod* 2001;91:328-33.
  9. Lee CA, Damm DD, Neville BW, et al. *Oral and maxillofacial pathology*. 3rd edition. St. Louis, Saunders, 2008;683-7.
  10. Shear M. Odontogenic keratocyst: natural history and immunohistochemistry. *Oral Maxillofac Surg Clin North Am* 2003;15:347-62.
  11. Makowski G, McGuff S. Squamous cell carcinoma in a maxillary odontogenic keratocyst. *J Oral Maxillofac Surg* 2001;59:76-80.
  12. Morgan TA, Burton CC, Qian F. A retrospective review of treatment of the odontogenic keratocyst. *J Oral Maxillofac Surg* 2005;63:635-9.
  13. Blanas N, Freund B, Schwartz M, et al. Systematic review of the treatment and prognosis of the odontogenic keratocyst. *Oral Surg Oral Med Oral Pathol Oral Radiol Endod* 2000;90:553-8.
  14. Sharifian MJ, Khalili M. Odontogenic cysts: a retrospective study of 1227 cases in an Iranian population from 1987 to 2007. *J Oral Sci* 2011;53:361-7.
  15. Philipsen HP. Keratocystic odontogenic tumour. In: Barnes EL, Eveson JW, Reichart P, Sidransky D eds. *World Health Organization classification of tumours: pathology and genetics of head and neck tumours*. Lyon: IARC Press; 2005;306-7.
  16. Speight PM, Takata T. New tumour entities in the 4th edition of the World Health Organization Classification of Head and Neck tumours: odontogenic and maxillofacial bone tumours. *Virchows Arch* 2018;472:331-9.
  17. Akay C, Tetik A, Zeytinoglu M. Keratocystic odontogenic tumor: A retrospective study of 64 cases. *Ege Journal of Medicine* 2015;54:59-64.
  18. Jones AV, Craig GT, Franklin CD. Range and demographics of odontogenic cysts diagnosed in a UK population over a 30-year period. *J Oral Pathol Med* 2006;35:500-7.
  19. Brannon RB. The odontogenic keratocyst. A clinicopathologic study of 312 cases. Part I. *Oral Surg Oral Med Oral Pathol* 1976;42:54-72.
  20. Kakarantza-Angelopoulou E, Nicolatou O. Odontogenic keratocysts: Clinicopathologic study of 87 cases. *J Oral Maxillofac Surg* 1990;48:593-9.
  21. Yagyu T, Kirita T, Sasahira T, et al. Recurrence of keratocystic odontogenic tumor: Clinicopathological features and immunohistochemical study of the hedgehog signaling pathway. *Pathobiology* 2008;75:171-6.
  22. Lam KY, Chan AC. Odontogenic keratocysts: A clinicopathological study in Hong Kong Chinese. *Laryngoscope* 2000;110:1328-32.
  23. Chirapathomsakul D, Sastravaha P, Jansisyanont P. A review of odontogenic keratocysts and the behavior of recurrences. *Oral Surg Oral Med Oral Pathol Oral Radiol Endod* 2006;101:5-9.
  24. Maurette PE, Jorge J, de Moraes M. Conservative treatment protocol of odontogenic keratocyst: a preliminary study. *J Oral Maxillofac Surg* 2006;64:379-83.
  25. Titinchi F, Nortje CJ. Keratocystic odontogenic tumor: A recurrence analysis of clinical and radiographic parameters. *Oral Surg Oral Med Oral Pathol Oral Radiol* 2012;114:136-42.
  26. MacDonald-Jankowski DS, Li TK. Keratocystic odontogenic tumour in a Hong Kong community: the clinical and radiological features. *Dentomaxillofac Radiol* 2010;39:167-75.
  27. Buckley PC, Seldin EB, Dodson TB, et al. Multilocularity as a radiographic marker of the keratocystic odontogenic tumor. *J Oral Maxillofac Surg*. 2012;70:320-4.
  28. Crowley TE, Kaugars GE, Gunsolley JC. Odontogenic keratocysts: A clinical and histologic comparison of the parakeratin and orthokeratin variants. *J Oral Maxillofac Surg* 1992;50:22-6.
  29. Cunha JF, Gomes CC, de Mesquita RA, et al. Clinicopathologic features associated with recurrence of the odontogenic keratocyst: a cohort retrospective analysis. *Oral Surg Oral Med Oral Pathol Oral Radiol* 2016;121:629-35.
  30. Forssell K, Forssell H, Kahnberg KE. Recurrence of keratocysts. A long-term follow-up study. *Int J Oral Maxillofac Surg* 1988;17:25-8.
  31. Woolgar JA, Rippin JW, Browne RM. A comparative study of the clinical and histological features of recurrent and nonrecurrent odontogenic keratocysts. *J Oral Pathol* 1987;16:124-8.
  32. de Castro MS, Caixeta CA, de Carli ML, et al. Conservative surgical treatments for nonsyndromic odontogenic keratocysts: a systematic review and meta-analysis. *Clin Oral Investig* 2018;22:2089-101.
  33. Pogrel A. The history of odontogenic keratocyst. *Oral and Maxillofacial Surg Clinics of North America* 2003;15:311-5.
  34. Pogrel A, Jordan K. Marsupialization as a Definitive Treatment for the Odontogenic Keratocyst. *J Oral Maxillofacial Surg* 2004;62: 651-5.
  35. Marin S, Kirnbauer B, Rugani P, et al. The effectiveness of decompression as initial treatment for jaw cysts: A 10-year retrospective study. *Med Oral Patol Oral Cir Bucal* 2018 Dec 20. [Epub ahead of print]
  36. Stoelinga P. Long-term follow-up on keratocysts treated according to a defined protocol. *Int J Oral Maxillofac Surg* 2001;30:14-25.