



The Case of a Patient with Concomitant Popliteal Artery and Ascending Aortic Aneurysm Who Presented with the Blue Toe Syndrome

Tevfik Güneş, İhsan Alur, Serkan Girgin, Bilgin Emrecan

Pamukkale University, Faculty of Medicine, Department of Cardiovascular Surgery, Denizli, Turkey

Abstract

Popliteal artery aneurysms (PAAs) are rare though these aneurysms are the most frequently encountered peripheral arterial aneurysms. In this article, we present the treatment of a patient who simultaneously had bilateral popliteal artery and ascending aortic aneurysm but was admitted to the emergency room due to the blue toe syndrome. A 72-old-year female was admitted to the hospital with left lower extremity pain and cyanosis in her toe. Bilateral popliteal artery and ascending aortic aneurysm were observed on computed tomography. Aneurysmectomy and femoropopliteal bypass was performed primarily to the left popliteal artery owing to ischemia. Two months later, we performed valve and ascending aorta replacement followed by right popliteal aneurysmectomy and femoropopliteal bypass 16 months later. In conclusion, since other arterial aneurysms can be simultaneously observed with popliteal artery aneurysm, it is very important to scan whole main arterial system when PAA is evaluated.

Key Words: Popliteal Artery; Aorta; Aneurysm; Embolism.

Blue Toe Sendromu ile Başvuran Popliteal Arter ve Asendan Aort Anevrizmalı Hasta

Özet

Popliteal arter anevrizmaları (PAA) nadir görülen patolojilerdir, fakat periferik arter anevrizmaları arasında en sık karşılaşılandır. Bu yazıda blue toe sendromu ile başvuran bilateral popliteal arter ve asendan aort anevrizması saptanan hastanın aşamalı tedavisi sunulmaktadır. 72 yaşında bayan hasta sol bacakta ağrı ve parmak uçlarında morarma yakınması ile acil servise başvurdu. Yapılan bilgisayarlı tomografik anjiyografisinde bilateral popliteal arter ve asendan aort anevrizması saptandı. Hastanın sol bacağı iskemik olduğundan öncelikli olarak sol popliteal artere anevrizmektomi ve femoropopliteal baypas uygulandı. 2 ay sonra kapak ve asendan aort replasmanı yapıldı ve 16 ay sonra sağ popliteal anevrizmektomi ve femoropopliteal baypas uygulandı. Sonuç olarak popliteal arter anevrizmalarına diğer arteriyel anevrizmalar eşlik ettiğinden saptandığında tarama yapılması çok önemlidir.

Anahtar Kelimeler: Popliteal Arter; Aort; Anevrizma; Emboli.

INTRODUCTION

Popliteal artery aneurysms (PAA) are rare pathologies (1-4). However, among other peripheral artery aneurysms, they are the most frequent type with an incidence rate of 0,1-2,8% (4, 5). They account for 70% of peripheral artery aneurysms (1, 3) and are bilaterally seen in half of the patients (3). They are more common in males (2-4). The major factor in elderly patients is atherosclerosis whereas the popliteal artery entrapment syndrome, cystic adventitial degeneration, osteochondroma, and trauma are the causes in younger patients (1, 2, 4).

Clinically, most PAAs are asymptomatic. Thrombosis, the major complication of PAA, may cause clinical views ranging from intermittent claudication to acute limb ischemia (4). Two methods can be used in therapy: 1) Open surgical techniques (ligation and bypass, endoaneurysmorrhaphy etc.) (2) Endovascular techniques (stent grafts) (1, 3). In this study, we aim to present the case of a patient who was admitted with blue toe syndrome along with a rare combination of bilateral popliteal artery aneurysm and ascending aorta

aneurysm and our experience of the patient's gradual surgical treatment.

CASE REPORT

A seventy-two-year-old female patient was admitted with pain in the left leg and symptoms of bruising on the left toes in June 2012. There was no remarkable signs in the patient's medical history except for uncontrolled hypertension. On physical examination, we heard 3/6 systolic murmur (+) around cardiac foci. The left foot was cold and pale with cyanotic appearance. We could not feel distal pulses in the bilateral lower extremity (dorsalis pedis artery: ADP; posterior tibial artery: ATP). We detected a palpable pulsatile mass in the bilateral popliteal region. We performed a Doppler ultrasonography (USG) to the bilateral lower extremity arterial and observed popliteal artery aneurysm reaching 30 mm in diameter on the left side. During the emergency operation preparations, we noticed murmur on physical examination and asked for an echocardiography, which at length revealed an ascending aortic aneurysm. The echocardiography conducted further revealed a left atrial diameter of 50

mm, 3rd-4th degree mitral insufficiency, third-degree aortic regurgitation, 2nd-3th degree tricuspid regurgitation, an ejection fraction of 45%, and a pulmonary artery pressure of 50 mmHg. Whereupon we performed a whole body computed tomographic angiography (CTA) scanning in order to see the extent of the aneurysm. The CTA imaging revealed ascending, descending aorta, and popliteal artery aneurysm (Figure 1).

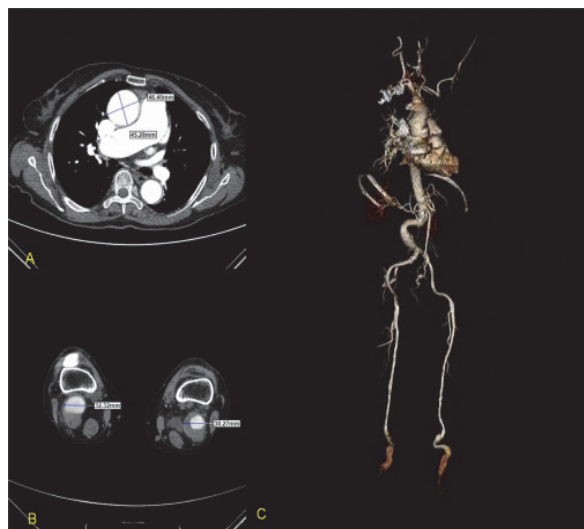


Figure 1. A) Aneurysmic ascending aorta and B) CT image of the popliteal artery; C) 3D image of the aneurysmic arteries and other segments.

The widest part of ascending aorta was 46 mm; the descending aorta was 49 mm at its widest diameter. The abdominal aortic diameter at the widest part was 26mm while the left popliteal artery at the widest part was 35 mm and the right popliteal artery was found to be 30 mm at the widest part. Because our hospital does not offer conventional angiography in emergency conditions and since the patient had ischemic discoloration in the left foot, we urgently took the patient to the operation room to operate her for the left popliteal artery aneurysm. Under general anaesthesia (GA), we applied the incision starting from the level of the hunter channel level in the left lower extremity down to the level of left infragenaal popliteal artery. Following the aneurysmectomy and embolectomy, we performed interposition with reverse saphenous vein graft from the beginning of the hunter channel until the distal of the left popliteal artery on the same side of the extremity. We could take pulses manually from the lower extremity in the postoperative period. The control Doppler USG showed normal flow velocity and patterns. As the echocardiography showed aortic, mitral, and tricuspid regurgitation while coronary angiography revealed normal coronary arteries, we planned a combined intervention of aortic valve, mitral valve, and simultaneous ascending aortic surgery. But the patient refused to undergo this planned operation and we discharged the patient without any problems 1 week after the popliteal aneurysm operation. 2 months later,

the patient presented again and this time we replaced the aortic and mitral valves with bioprosthetic valves along with an ascending aorta replacement with a Dacron tube graft and De Vega annuloplasty for the tricuspid valve. After an uneventful postoperative period, the patient was discharged without any problems with an appointment for surgery for the right popliteal artery aneurysm within a month. The patient did not turn up for the surgery. After 16 months, the patient was admitted to the emergency service of our hospital with complaints of pain and bruising at the bottom of the right foot and leg. Physical examination showed ischemic discoloration on the right lower extremity accompanied by motor and sensory loss. We could not take distal pulses (ADP-ATP) manually on the right lower extremity. We performed an arterial Doppler ultrasound for the right lower extremity to observe thrombus of the arterial system extending from the right inguinal region to the popliteal region and thrombosed popliteal aneurysm. Due to a possible embolisation that may result from the patient's known popliteal artery aneurysm, we planned an emergency operation. We carried out an exploration starting from the proximal of the right thigh hunter channel to the distal trifurcation region of the right popliteal artery. Following the aneurysmectomy, we performed embolectomy and an interposition between popliteal artery and anterior tibial artery using a reverse saphenous vein graft. Next, we performed a bypass with the saphenous vein from the saphenous vein to the posterior tibial artery. During the postoperative period and due to the long ischemic process, we observed reperfusion injury. At length, we also had to implement an amputation from over the knees because of wound problems (necrosis, oedema, etc.) in the right lower extremity, poor distal run-off, and the continuation of the ischemic process.

DISCUSSION

PAA is the most common type of peripheral artery aneurysms. Unlike our case, it is often seen in males. In half of the patients, bilateral aortic aneurysm accompanies PAA while almost 50% of PAA patients may have concomitant abdominal aortic aneurysms (3). Dawson et al.'s study on 1673 patients 97% of which were males reports that 50% patients had accompanying bilateral popliteal artery aneurysms while 36% of the patients had concomitant abdominal aortic aneurysms (6). Huang et al.'s study on 494 patients gives a concomitant abdominal aortic aneurysm rate of 54%. The same study reports that 9% of the patients had thoracic aortic aneurysms with PAA. However, the study does not report any concomitant ascending aorta aneurysms (3). In our patient, we observed bilateral popliteal artery aneurysm with ascending aorta aneurysm, a very rare condition itself.

Atherosclerosis is the major cause of PAA. Other factors can be posttraumatic, mycotic, popliteal artery entrapment syndrome-related, or connective tissue disease related reasons (7). In the etiology of ascending aortic aneurysm, degenerative changes (cystic medial degeneration) are in the foreground. Other etiological

factors can be connective tissue disorders such as Marfan syndrome, atherosclerosis, bicuspid aortic dissection, chronic dissection, inflammatory diseases, or traumas (8). In our patient, atherosclerosis accompanied by hypertension was the underlying reasons for the formation of both of the aneurysms.

PAA usually follows a clinically asymptomatic course though it may still bring about serious complications such as loss of extremities or even lives (4, 5). Most serious complications are acute thrombosis, distal embolization, and, though uncommon, popliteal vein thrombosis due to rupture and local compression (1-4). Distal embolisation related intermittent claudication may manifest itself as ischemic findings such as rest pain, ulceration, or "blue toe syndrome." Blue toe syndrome (also known as cholesterol crystal embolism syndrome) is a systemic disorder that usually results from tissue ischemia caused by the embolisation of components from the aorta or ulcerated atheroma plaque as well as of cholesterol crystals. It can affect any organ, but it often keeps the skin and kidneys. Livedo reticular (blue or purplish discoloration of the skin) in the lower extremities and acrocyanosis (bruises on the hands and feet) are the most common skin symptoms (9). The presenting symptoms of our patient also included distal embolism, which is one of the most serious complications.

Interference indications in patients with acute ischemia and chronic ischemic symptoms have been identified clearly. For patients with local compression findings, rest pain, and tissue loss and those who describe severe claudication, there is consensus on the indications for elective interventions (1, 3). But intervention indications in asymptomatic patients are not clear. Factors affecting the decision to intervene PAA are the incidence and speed of symptoms, size of aneurysm in diameter, mural thrombus, and the presence of thromboembolic history (1, 3, 4). Many authors recommend elective intervention in terms of thromboembolic risks for mural thromboses larger than 20 mm in asymptomatic patients (5, 10). Patients with untreated PAAs tend to have an increased risk of complications over time; Galland et al.'s study has put forward that asymptomatic PAA has the risk of becoming symptomatic by 14% annually (11). In Lowel et al.'s study 18% of PAA patients have become symptomatic within a 17-month period (12). Indeed, our patient, too, has become symptomatic within 16 months.

Treatment of popliteal artery aneurysms requires attention since the treatment may bring about the risk of losing limbs, extremity dysfunction due to nerve and vein compression, and even rupture-related deaths. There are many treatment options in such cases (2). Despite the fact that open surgical techniques play a leading role in a successful treatment, endovascular stenting is also among preferred methods. For patients presenting with acute limb ischemia, preoperative implementation of thrombolytic therapy followed by bypass or stent application is another treatment option (2). While thrombolytic therapy is suggested for Rutherford class I-IIa patients with acute ischemia, it is

not not recommended in patients with Rutherford class IIb-III (patients with motor or sensory loss) as this option is seen as a waste of time (3, 5). Krop et al.'s study has found out that preoperative or intraoperative thrombolytic implementation has significant impact on reducing rate of amputation. However, they have added that these applications bear notable differences only by one-year primary patency rates and in comparison to the group undergoing surgical procedures (5).

The general approach in open surgery concentrates on removing the lesion and achieving arterial continuity with synthetic or autogenous grafts (4). Today, as a minimally invasive approach for the treatment of PAA, practitioners also prefer endovascular methods. However, these approaches are still subject to controversy due to potential secondary stent fractures that may be observed in popliteal joint flexion. Although new stents with improved flexibility have been developed, there is need for long-term outcomes of these innovations (4).

CONCLUSIONS

As a conclusion, it can be stated that popliteal artery aneurysms are often accompanied by other arterial aneurysms. Therefore, when identified, there is need for other system scans. As it is indicated in the guidelines for arteries and veins published by the Turkish Cardiovascular Surgery Society, we also believe that, even if asymptomatic, thromboses larger than 20 mm ought to be treated in elective conditions before they get more complicated since PAA may result in extremity loss and mortality.

This study was accepted as an e-poster for the 13th National Turkish Cardiovascular Surgery Society Congress held between 30 October and 2 November 2014 in Antalya.

REFERENCES

1. Kim SW, Chang JW A giant popliteal artery aneurysm treated with exclusion and bypass using a saphenous vein. Korean J Thorac Cardiovasc Surg. 2013;46(5):369-72.
2. Mataracı İ, Büyükbayrak F, Şaşmaz A, Aksüt M, Sarıkaya S, Saçlı H ve ark. Popliteal arter anevrizma tanısıyla cerrahi onarım uygulanan olgularda erken ve geç dönem sonuçlarımız. Türk Göğüs Kalp Damar Cerrahisi Dergisi. 2009;(17):173-8.
3. Huang Y, Gloviczki P, Noel AA, Sullivan TM, Kalra M, Gullerud RE et al. Early complications and long-term outcome after open surgical treatment of popliteal artery aneurysms: is exclusion with saphenous vein bypass still the gold standard? J Vasc Surg. 2007;45(4):706-713; discussion 713-5.
4. Kaya E, Doğanç S, Kadan M, Erol G, Günay C, Demirkılıç U. Dev tromboze Popliteal Arter Anevrizması. Damar cer Derg 2012;21(2):171-4.
5. Kropman RH, Schrijver AM, Kelder JC, Moll FL, de Vries JP. Clinical outcome of acute leg ischaemia due to thrombosed popliteal artery aneurysm: systematic review of 895 cases. Eur J Vasc Endovasc Surg. 2010;39(4):452-7.
6. Dawson I, Sie RB, Van Bockel JH. Atherosclerotic popliteal aneurysm. Br J Surg 1997;84:293-9.
7. Szilagyi DE, Schwartz RL, Reddy DJ. Popliteal arterial aneurysms. Their natural history and management. Arch Surg 1981;116:724-8.

8. Moreno-Cabral CE, Miller DC, Mitchell RS, Stinson EB, Oyer PE, Jamieson SW, et al. Degenerative and atherosclerotic aneurysms of the thoracic aorta. Determinants of early and late surgical outcome. *J Thorac Cardiovasc Surg.* 1984;88(6):1020-32.
9. Özler A, Tarhan İA, Kehlibar T, Arslan Y, Yılmaz M, Dumantepe M, et al. Blue toe syndrome following modified Bentall procedure: a case report. *Turkish J Thorac Cardiovasc Surg* 2010;18(3):220-1.
10. Aulivola B, Hamdan AD, Hile CN, Sheahan MG, Skillman JJ, Campbell DR, et al. Popliteal artery aneurysms: a comparison of outcomes in elective versus emergent repair. *J Vasc Surg* 2004;39(6):1171-7.
11. Michales JA, Galland RB. Management of asymptomatic popliteal aneurysms: the use of a Markov decision tree to determine the criteria for a conservative approach. *Eur J Vasc Surg* 1993;7(2):136-43.
12. Lowell RC, Gloviczki P, Hallett J, Naessens JM, Maus TP, Cherry KJ, et al. Popliteal artery aneurysms: the risk of nonoperative management. *Ann Vasc Surg* 1994;8:14-23.

Received/Başvuru: 26.11.2014, Accepted/Kabul: 12.12.2014

Correspondence/İletişim

Tevfik GÜNEŞ
Pamukkale Üniversitesi Tıp Fakültesi, Kalp Damar Cerrahisi
Anabilim Dalı, DENİZLİ, TÜRKİYE
E-mail: tevfik04@yahoo.com

For citing/Atf için

Günes T, Alur I, Girgin S, Emrecan B. The patient with concomitant popliteal artery and ascending aortic aneurysm who admitted to the hospital due to the blue toe syndrome *J Turgut Ozal Med Cent* 2015;22:197-200 DOI: 10.7247/jtomc.2014.2480