

# A retrospective analysis of anterior single dental implants

Nermin Demirkol<sup>1</sup>, Mehmet Demirkol<sup>2</sup>

<sup>1</sup>Gaziantep University, Faculty of Dentistry Department of Prosthodontics, Gaziantep, Turkey

<sup>2</sup>Gaziantep University, Faculty of Dentistry Department of Oral and Maxillofacial Surgery, Gaziantep, Turkey

Copyright © 2019 by authors and Annals of Medical Research Publishing Inc.

## Abstract

**Aim:** This retrospective study aimed to examine the demographic data of patients who underwent an intraosseous maxillary anterior single dental implant and the characteristic features of dental implants, including diameter/length, distribution of anatomic localization and implant failure.

**Material and Methods:** Demographic data, including the distribution of dental implants according to age, gender and the age of 108 patients who underwent dental implant placement in the researchers' clinic between 2009 and 2015 were obtained from archival records. Only patients with the loss of a single tooth in the anterior region of the jaws were included. Anatomic localizations, diameter/height characteristics and implant failure results of the dental implants were analyzed with descriptive statistical analysis.

**Results:** Of 108 patients, 47 (36.7%) were males and 61 (63.3%) were females. A total of 120 dental implants were evaluated. The mean age of the patients was 35.4±15.63 years, ranging from 18 to 70 years. The ages of the second decade, particularly 18 or 19 years old, was the most placed dental implant (n=24, 25%). A total of 103 (85.8%) implants were surgically placed into the maxillary anterior region and 17 (14.2%) into the lower jaw. The most common implant diameter was 4.1 mm (17 patients, 14.1%) and the length was 14 mm (42 patients, 35%).

**Conclusion:** This study showed that the dental implant treatment in the esthetic region was demanded immediately by the patients without any further bone resorption.

**Keywords:** Dental implant; mandible; maxilla; esthetic zone.

## INTRODUCTION

The principle of osseointegration based on single dental implant has been accepted as a predictable and successful treatment (1) since it was first described by Jemt in 1986 (2). It is effective in providing an esthetical and functional alveolar bone volume and gingival structure in the treatment of anterior dental implants with high esthetic expectancy (3).

In 1970s and 1980s, the treatment protocol for the implants was accepted as placement in the fully healed alveolar ridges (4,5). But this concept turned around on the approach that include the placement of the implants in fresh extraction sockets (6) or partially healed alveolar bones (7) after tooth extraction, predominantly for implants in the esthetic zone.

Due to the esthetic concerns of the patients, the anterior dental implants are placed immediately and treatment process is also shortened. With this protocol, a better gingival aesthetic result can be obtained by providing

a soft tissue contour with immediate placement of the implant and application of a temporary prosthesis (3,8).

Single tooth deficiencies in the anterior region of the jaws can be caused by dental trauma, periapical abscess, root resorption, endodontic complications, and periodontal causes. In addition to these, in order to avoid fixed prosthesis with the support of the remaining teeth or in cases in which orthodontic closure is contraindicated, anterior single dental implants are primarily preferred in young adults (9-11).

The aim of this study is to retrospectively examine the demographic data of the patients who underwent intraosseous single dental implant surgery in the anterior regions of the maxilla and/or mandible between 2009 and 2015 in the researchers' clinic and analyze the characteristics of surgically placed dental implants.

## MATERIAL and METHODS

The sample population consisted of 108 patients who

**Received:** 15.05.2019 **Accepted:** 11.07.2019 **Available online:** 05.08.2019

**Corresponding Author:** Nermin Demirkol, Gaziantep University, Faculty of Dentistry Department of Prosthodontics, Gaziantep, Turkey,

**E-mail:** dt\_nerminhamdemirci@hotmail.com

attended the Departments of Oral and Maxillofacial Surgery and Prosthodontics, Gaziantep University, Faculty of Dentistry for one or two single tooth deficiencies in the mandibular and/or maxillary anterior regions between 2009 and 2015 years. Demographic and clinical characteristics of 120 dental implants in 108 patients were retrospectively evaluated. The age, gender, the edentulous dental area, implant diameter and length, the number of implants applied to the mandibular or maxillary anterior regions and the distribution of dental implants according to the site, were examined. All of the examined implants had either a natural tooth or a prosthetic restored tooth on either side of the edentulous site.

No dental implant was immediately placed following tooth extraction. All implants were installed with different implant placement protocols including early placement with soft tissue healing, early placement with partial bone healing and late placements according to Chen and Buser (12). The study was approved by the Clinical Research Ethics Committee of the Sanko University (June 11, 2018; session: 2018/07, decision no: 03).

Ten different brands dental implants including Straumann (Straumann Institute, Waldenburg, Switzerland), Bredent (Bredent medical GmbH & Co.KG, Senden, Germany), Biotech (Biotech Dental, Salon de Provence, France), Zimmer Dental (Carlsbad, CA, USA), Biohorizons (Maestro Dental Implants, Birmingham, AL, USA), Mis® Seven (MIS®, Medical implants System, Israel), NucleOSS, (Şanlılar Tibbi Cihazlar Medikal Kimya San Tic Ltd. Sti, İzmir, Turkey), BIOMET 3i, Palm Beach Gardens, FL, USA),

Implantium implants (Dentium Co., Seoul, Korea), DIO Implant (Busan, Republic of Korea) had been surgically placed with the same surgical procedure under local anesthesia. Descriptive statistical analysis was used for investigation of data.

## RESULTS

In this study, 47 (36.7%) of the 108 patients were male and 61 (63.3%) were female. A total of 120 dental implants were evaluated. In 12 patients, 2 separate single dental implants were applied. The mean age of patients was 35.4±15.63 years, ranging from 18 to 70 years. There were 24 patients (20%) who were 18 or 19 years of age, and 23 patients (19.1%) were in the 3th, 19 patients in their 4th decade (15.8%), 18 patients in their 5th decade, 15 patients (12.5%) in their 6th decade, 6 patients (5%) in their 7th decade and 3 patients (2.5%) in their 8th decade (Table 1). In the distribution of implants according to gender, it was found that female patients mostly preferred the implant treatment from males in both jaws (maxilla; female=58, male=45, mandible; female=10, male=7).

A hundred and three dental implants (85.3%) were placed in the anterior maxillary region and 17 implants (14.2%) in the mandible. When the distribution of implants in the upper jaw were examined, it was found that 35 (29.1%) implants were placed in the central tooth region, 36 (30%) in the lateral and 32 (26.6%) in the canine. In the mandible, while most of the implants were placed in the canine region (8, 6.6%), the central tooth area (4, 3.3%) was the least (Table 2).

**Table 1. Distribution of dental implants according to age (decade)**

	2 <sup>nd</sup> decade	3 <sup>th</sup> decade	4 <sup>th</sup> decade	5 <sup>th</sup> decade	6 <sup>th</sup> decade	7 <sup>th</sup> decade	8 <sup>th</sup> decade
<b>Number of Implants (n/%)</b>	24 (20%)	23 (19.1%)	19 (15.8%)	18 (15%)	15 (12.5%)	6 (5%)	3 (2.5%)

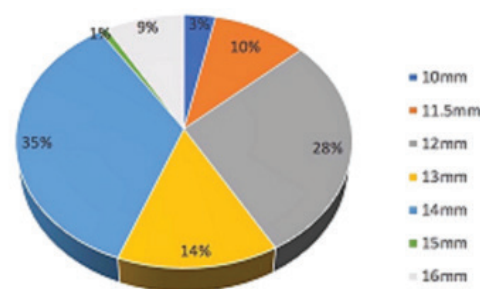
**Table 2. The distribution of dental implants at the anterior of the jaws according to the single tooth areas**

<b>Number of Implants</b>	<b>Central area n/%)</b>	<b>Lateral area n/%)</b>	<b>Canine area n/%)</b>	<b>Total n/%)</b>
<b>Maxilla</b>	35/29.1%	36/30%	32/26.6%	103/85.7%
<b>Mandible</b>	4/3.3%	5/4.3%	8/6.7%	17/14.3%
<b>Total</b>				120/100%

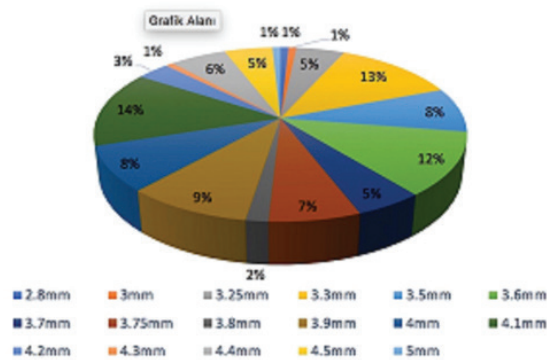
When the distribution of the dental implants according to their diameters and lengths were examined, it was found that the implant diameters were between 2.8 - 5 mm and the implant size was between 10 - 16 mm. The most common placed three implant diameters were 4.1 mm (17 patients, 14.1%), 3.3 mm (15 patients, 12.5%) and 3.6 mm (14 patients, 11.6%), respectively. Data on other diameters are shown in Graphic 1. The three most common implant sizes were 14 mm (42 patients, 35%), 12 mm (34 patients, 28.3%) and 13 mm (17 patients, 14.1%), respectively (Graphic 2).

Regarding implant survival, four (3.3%) implants were lost due to infection before loading. Three of them were located in the maxilla and the other in the mandible. Three implants were 3.25 mm in diameter and the other was 3.7

mm in diameter. The survival rate of all 120 dental implant patients was 96.6%.



**Graphic 1. Patient distributions according to diameter of the implants (mm)**



**Graphic 2.** Patient distributions according to length of the implants (mm)

## DISCUSSION

Dental implants, replacing the lost tooth, are now a preferred treatment option by clinicians (13). Due to high survival rates, they can be performed with various placement and loading protocols in the anterior or posterior parts of the jaws (14,15). The success of osseointegration depends on the absence of pain or mobility in the implant, and the absence of progressive bone loss around the implant during function. These criteria are generally required for all implants in the function. However, in the anteriorly placed implants, the selection and design of the prosthetic superstructure material and harmony in the soft tissues are as important as these criteria. Particularly, the minimal differences between the soft tissue structures in the anterior dental implants and natural tooth has become the most important criterion for the patients with high aesthetic expectancy (1,16,17).

When evaluating the distribution of implants anteriorly placed on the jaws, the most common region of the maxillary anterior was lateral tooth (30%) area followed by central (29.1%) and canine (26.6%) teeth. In the mandible, the most common implanted region was the canine (6.7%). Parel and Schow placed a single tooth implant to the anterior part of the lower and upper jaws in 29 of the 45 patients. They reported that 6 implants placed in maxillary central and 18 placed maxillary lateral, 4 placed maxillary canine. Only one implant was placed canine region in the mandible. One implant placed in the lateral region was unsuccessful. They found a success rate of 97.8% and suggested that single tooth deficiencies could be effectively restored with dental implants (18). Ferrara et al. inserted and immediately restored 33 implants in the maxillary aesthetic area, 14 placed in the central area, 9 in the lateral, 4 in the canine and 6 in the premolar region. They observed the implants that were placed in diameter of 3.8 – 5.5 mm and implants of 13 – 15 mm lengths were between 2 and 52 months. They reported that the implant was not osseointegrated in only one patient and 1 implant failed in another patient due to secondary trauma. As a result, it has been reported that the functional and esthetic results of single anterior implants that immediately placed in postextraction sites were satisfactory for both the clinician and their patient (19).

In another study, dental implants were inserted in the single tooth deficiencies in the jaws of 102 patients. 29 of them were placed maxilla and 30 in the mandible. After one year follow-up, only 1 implant placed the lateral incisor was not osseointegrated (20). In this study, the implant success rate was found to be 96.6% which is consistent with the literature (11,19).

In a retrospective study conducted of 30,959 implants in 2018, the implant failure in the anterior region of the mandible was reported to be 2.17 times higher than the posterior region in the early period before prosthetic restoration. The thick mandibular cortical bone plate, low blood supply to the mandible and difficulty in operation in the anterior mandible may be causative factors in the occurrence of this failure (21).

Immediate implantation following tooth extraction with temporarily restoration without loading shortens the total healing process of the implant. This procedure provides the reduction of crestal bone loss and enhances aesthetics, supported by gingival architecture. Therefore, this approach is increasingly preferred by clinicians in recent years (22,23).

The selection of which implant therapy protocol on the anterior zone depends on clinical and radiological preoperative assessment of the patient's risk profile. Based on the 3rd volume of the ITI Treatment Guide Series by Chen and Buser in 2008, clinicians may use the four treatment options for aesthetic zones (Type I-IV); (1) an immediate implant placement following extraction, (2) early implant placement with soft tissue healing (4-8 weeks), (3) early implant placement with partial bone healing (12-16 weeks), (4) late implant placement ( $\geq 6$  months of healing post extraction) (12). The preoperative assessment of the characterization of gingival phenotype (thick or thin) and facial bone thickness of alveolar socket or whether sufficient bone volume of bone apical and palatal of the extraction site by cone beam computerized tomography are present are the paramount anatomic factors to predict further gingival recession, particularly in type 1 placement. To provide the long-term aesthetic success and stability in facial hard and soft tissues of the anterior dental implant, it has been highly recommended for type 2 placement that provides a good regenerative and aesthetic results with high predictability and a low risk of gingival recession (24).

## CONCLUSION

It is known that there is a relationship between dental implant treatment and age in the tooth loss in jaws. The mean age of the total edentulism (25,26) is higher than the partial edentulism (27,28). The need for a single dental implant in the anterior region of the jaws occurs in the younger age of years (29,30). In this study, the mean age was 35.4 years. However, single implant placement in the aesthetic region was done in wide range of life decades, the most common implantation age was found in early adulthood, particularly at the ages of 18 and 19. With

these results, it can be concluded that patients mostly prefer dental implant treatment in young adulthood period reducing further bone resorption in the alveolar bone.

*Competing interests: The authors declare that they have no competing interest.*

*Financial Disclosure: There are no financial supports*

*Ethical approval: Ethical approval was obtained from the Ethics Committee of Sanko University, Gaziantep, Turkey (June 11,2018; session: 2018/07, decision no: 03).*

*Nermin Demirkol ORCID: 0000-0002-2415-5977*

*Mehmet Demirkol ORCID: 0000-0003-1973-0364*

## REFERENCES

- den Hartog L, Slater JJ, Vissink A, et al. Treatment outcome of immediate, early and conventional single-tooth implants in the aesthetic zone: a systematic review to survival, bone level, soft-tissue, aesthetics and patient satisfaction. *J Clin Periodontol* 2008;35:1073-86.
- Jemt T. Modified single and short-span restorations supported by osseointegrated fixtures in the partially edentulous jaw. *J Prosthet Dent* 1986;55:243-7.
- Arora H, Khzam N, Roberts D, et al. Immediate implant placement and restoration in the anterior maxilla: Tissue dimensional changes after 2-5 year follow up. *Clin Implant Dent Relat Res* 2017;19:694-702.
- Branemark PI, Hansson BO, Adell R, et al. Osseointegrated implants in the treatment of the edentulous jaw. Experience from a 10-year period. *Scand J Plast Reconstr Surg Suppl* 1977;16:1-32.
- Adell R, Lekholm U, Rockler B, et al. A 15-year study of osseointegrated implants in the treatment of the edentulous jaw. *Int J Oral Surg* 1981;10:387-416.
- Schwartz-Arad D, Chaushu G. The ways and wherefores of immediate placement of implants into fresh extraction sites: A literature review. *J Periodontol* 1997;68:915-23.
- Nir-Hadar O, Palmer M, Soskolne WA. Delayed immediate implants: Alveolar bone changes during the healing period. *Clin Oral Implants Res* 1998;9:26-33.
- Raes F, Cosyn J, Crommelinck E, et al. Immediate and conventional single implant treatment in the anterior maxilla: 1-year results of a case series on hard and soft tissue response and aesthetics. *J Clin Periodontol* 2011;38:385-94.
- Salinas TJ, Block MS, Sadan A. Fixed partial denture or singletooth implant restoration? Statistical considerations for sequencing and treatment. *J Oral Maxillofac Surg* 2004;62:2-16.
- Misch CE. Maxillary anterior single-tooth replacement. Chapter 22, *Dental Implant Prosthetics*, St.Louis: Mosby; 2005. p. 368-413.
- Winitzky N, Olgart K, Jemt T, et al. A retro-prospective long-term follow-up of Brånemark single implants in the anterior maxilla in young adults. Part 1: Clinical and radiographic parameters. *Clin Implant Dent Relat Res* 2018;20:937-44.
- Chen ST, Buser D. ITI Treatment Guide Vol 3: Implants in extraction sockets. In: Buser D, Belser U, Wismeijer D, eds. *Implants in post-extraction sites: a literature update*. Berlin: Quintessence Publishing Co, Ltd; 2008. p. 9-16.
- Misch CE, Perel ML, Wang HL, et al. Implant success, survival and failure: The international congress of oral implantologists (ICOI) Pisa consensus conference. *Implant Dent* 2008;17:5-15.
- Gallucci GO, Hamilton A, Zhou W, et al. Implant placement and loading protocols in partially edentulous patients: A systematic review. *Clin Oral Implants Res* 2018;16:106-34.
- Troiano G, Lo Russo L, Canullo L, et al. Early and late implant failure of submerged versus non-submerged implant healing: A systematic review, meta-analysis and trial sequential analysis. *J Clin Periodontol* 2018;45:613-23.
- Slagter KW, den Hartog L, Bakker NA, et al. Immediate placement of dental implants in the esthetic zone: a systematic review and pooled analysis. *J Periodontol* 2014;85:241-50.
- Arora H, Ivanoski S. Clinical and aesthetic outcomes of immediately placed single tooth implants with immediate vs. delayed restoration in the anterior maxilla: A retrospective cohort study. *Clin Oral Impl Res* 2018;29:346-52.
- Parel SM, Schow SR. Early clinical experience with a new one-piece implant system in single tooth sites. *J Oral Maxillofac Surg* 2005;63:2-10.
- Ferrara A, Galli C, Mauro G, et al. Immediate provisional restoration of postextraction implants for maxillary single-tooth replacement. *Int J Periodontics Restorative Dent* 2006;26:371-7.
- Kemppainen P, Eskola S, Ylipaavaniemi P. A comparative prospective clinical study of two single-tooth implants: A preliminary report of 102 implants. *J Prosthet Dent* 1997;77:382-7.
- Lin G, Ye S, Liu F, et al. A retrospective study of 30,959 implants: Risk factors associated with early and late implant loss. *J Clin Periodontol* 2018;45:733-43.
- De Rouck T, Collys K, Cosyn J. Immediate single-tooth implants in the anterior maxilla: a 1-year case cohort study on hard and soft tissue response. *J Clin Periodontol* 2008;35:649-57.
- Cosyn J, Eghbali A, Hermans A, et al. A 5-year prospective study on single immediate implants in the aesthetic zone. *J Clin Periodontol* 2016;43:702-9.
- Buser D, Chappuis V, Belser UC, et al. Implant placement post extraction in esthetic single tooth sites: when immediate, when early, when late? *Periodontol* 2000 2017;73:84-102.
- Kim HS, Cho HA, Kim YY, et al. Implant survival and patient satisfaction in completely edentulous patients with immediate placement of implants: a retrospective study. *BMC Oral Health* 2018;18:219.
- Yunus N, Masood M, Saub R, et al. Impact of mandibular implant prostheses on the oral health-related quality of life in partially and completely edentulous patients. *Clin Oral Implants Res* 2016;27:904-9.
- Younes F, Eghbali A, De Bruyckere T, et al. A randomized controlled trial on the efficiency of free-handed, pilot-drill guided and fully guided implant surgery in partially edentulous patients. *Clin Oral Implants Res* 2019;30:131-8.
- Attard NJ, Zarb GA. Implant prosthodontic management of partially edentulous patients missing posterior teeth: The Toronto experience. *J Prosthet Dent* 2003;89:352-9.
- Arora H, Ivanoski S. Evaluation of the influence of implant placement timing on the esthetic outcomes of single tooth implant treatment in the anterior maxilla: A retrospective study. *J Esthet Restor Dent* 2018;30:338-45.
- Khoshhal M, Vafaei F, Najafi M, et al. Comparison of interdental papilla around single implants in the anterior maxilla between two implant systems: A cohort study. *J Dent Res Dent Clin Dent Prospects* 2018;12:38-44.