

A rare cause of acute generalized exanthematous pustulosis (AGEP); paracetamol ingestion

Dursun Turkmen

Malatya Training and Research Hospital, Dermatology Clinic, Malatya, Turkey

Dear Editor,

Acute generalized exanthematous pustulosis (AGEP) was first defined by Beylot et al. (1) and its annual incidence is 1-5 million (2). 90% of the cases have a history of drug use (1,3). Antibiotics are the most frequent AGEP causing agents. While Beta-lactam antibiotics and macrolides are the most frequent reason, tetracyclines, quinolones, aminoglycosides and sulphonamides can also cause AGEP. Other drugs which cause AGEP less frequently can be listed as metronidazole, nystatin, isoniazide, furosemide, diltiazem, nonsteroid anti-inflammatory drugs, codeine, dexamethasone, anticonvulsants such as carbamazepine and phenytoin (1-5).

In addition to drugs, its etiology also includes Parvovirus B19, Coxsackie B4, Epstein Barr virus, Cytomegalovirus, Hepatitis B virus infections and Mycoplasma infections (5). With this case, our purpose was to draw attention that paracetamol can also cause AGEP.

An 8-year-old girl referred to our clinic with a complaint of rashes that started 3 days ago. The vital signs of the patient were as follows: fever 38.6 °C, pulse 112 beat/min, respiratory rate 28/min, arterial blood pressure 98/60 mm Hg. The patient's history revealed that she used paracetamol for fever and three days later widespread rashes started in the body.

Dermatologic examination showed widespread nonfollicular pustules on erythematous background which were dense in the proximals and less dense in the distals of the upper and lower extremities (Figure 1).

Lesions of the torso were seen up to the gill and lesions of the leg were seen as far as the sides of the foot. No lesions were seen on her head, face and soles. Mucosae were normal. The patient's laboratory results were as follows: hemoglobin: 11.9 g/dl, Hct: %36.7, thrombocyte: 409.000/

mm³, leukocyte: 27.420/mm³, peripheral smear had 80% neutrophil, 15% lymphocyte and 3% eosinophil. C-reactive protein was found as 24.78 mg/dl. Throat culture showed normal flora. Since the lesions were typical, together with fever and neutrophilia, the patient was considered to have AGEP. Our case got 9 points according to the scoring chart made by EuroSCAR study group. According to this; the patients who have 8-12 points diagnosed as AGEP. Skin biopsy is important for diagnosis of AGEP. In our case, biopsy was planned for the patient, but the patient's relatives did not consent.

The patient was discontinued for paracetamol medication. Following that, the lesions started to regress rapidly. When the patient was checked again four days later, it was seen that the pustules disappeared completely and they were replaced by desquamation (Figure 2).

AGEP is one of the rare drug eruptions. In more than 90% of acute generalized exanthematous pustulosis cases drugs, mainly antibiotics, are responsible (6,7). Apart from drugs, the etiology of acute generalized exanthematous pustulosis includes viral infections, exposure to mercury, radiation and spider bite. NSAII drugs and paracetamol are rarely in the etiology (8,9).

Although the pathogenesis of AGEP is not completely understood, the accumulation of cytokines released by adjuvant T cells and drug or infection induced antigen-antibody complexes on the skin are held responsible. Clinical signs generally start within the first 24 hours after the drug is used; however, in some cases the appearance of clinical signs can take up to 3 weeks (10).

As a conclusion, AGEP is a T cell mediated drug reaction rarely seen in children and its etiology typically includes drugs. It should be kept in mind that, although rarely, it may develop as a result of antipyretics such as paracetamol which are used frequently in practice.

Received: 11.08.2017 Accepted: 28.08.2017

Corresponding Author: Dursun Turkmen, Malatya Training and Research Hospital, Dermatology Clinic, Malatya, Turkey.

E-mail: drturkmen44mlt@gmail.com

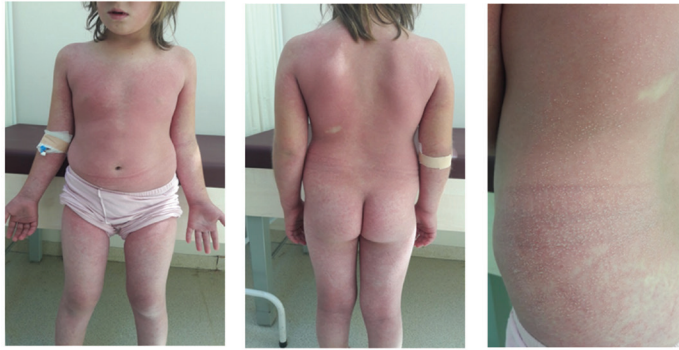

Figure 1. Widespread nonfollicular pustules on erythematous background

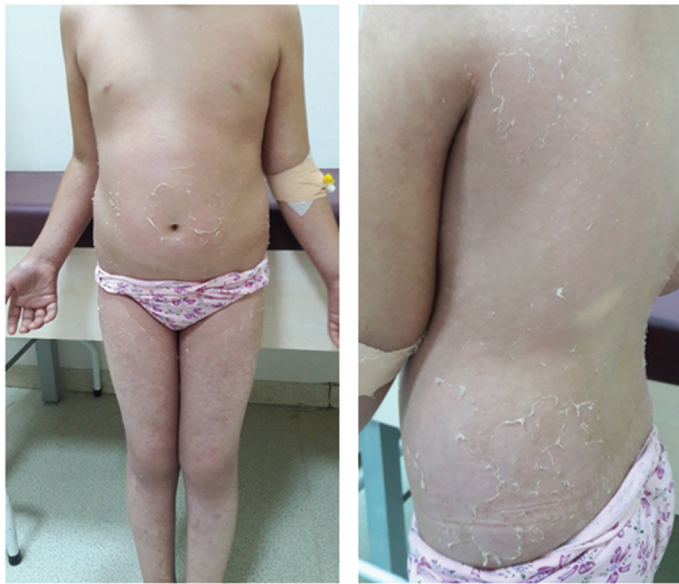


Figure 2. Four days later. Widespread desquamation on background of the lesions

The informed consent was taken from patient's parent.

REFERENCES

1. Beylot C, Bioulac P, Doutre MS. Acute generalized exanthematous pustulosis (four cases). *Ann Dermatol Venereol* 1980;107(1-2):37-48.
2. Freedberg IM, Eisen AZ, Wolff K, Austen KF, Goldsmith LA, Katz SI (eds) *Fitzpatrick's Dermatology in General Medicine*. 6th ed. New York: McGraw-Hill; 2003. p. 625-7.
3. Chaabane A, Aouam K, Gassab L, Njim L, Boughattas NA. Acute generalized exanthematous pustulosis (AGEP) induced by cefotaxime. *Fundam Clin Pharmacol* 2010;24(4):429-32.
4. Roujeau JC, Bioulac-Sage P, Bourseau C, Guillaume JC, Bernard P, Lok C, et al. Acute generalized exanthematous pustulosis. Analysis of 63 cases. *Arch Dermatol* 1991;127(9):1333-8.
5. Belhadjali H, Mandhouj S, Moussa A, Njim L, Amri M, Zakhama A, et al. Mercury-induced acute generalized exanthematous pustulosis misdiagnosed as a drug-related case. *Contact Dermatitis* 2008;59(1):52-4.
6. Halevy S. Acute generalized exanthematous pustulosis. *Curr Opin Allergy Clin Immunol* 2009;9:(4)322-8.
7. Şenbaba E, Çatal F, Topal E, Ermiştekin H, Varol Fi, Akpolat N. A case of acute generalised exanthematous pustulosis (AGEP) induced by amoxicillin-clavulanic acid. *Asthma Allergy Immunol* 2014;12:45-9.
8. Choi MJ, Kim HS, Park HJ, Park CJ, Lee JD, Lee JY, et al. Clinicopathologic manifestations of 36 Korean patients with acute generalized exanthematous pustulosis: a case series and review of the literature. *Ann Dermatol* 2010;22(2):163-9.
9. Fernando SL. Acute generalised exanthematous pustulosis. *Australas J Dermatol* 2012;53(2):87-92.
10. Halevy S, Kardaun SH, Davidovici B, Wechsler J; EuroSCAR and RegiSCAR study group. The spectrum of histopathological features in acute generalized exanthematous pustulosis: a study of 102 cases. *Br J Dermatol* 2010;163:1245-52.