

# Antioxidant effects of ellagic acid on testicular tissue of rats exposed to tobacco smoke metabolite-acetic acid

Nalan Kaya<sup>1</sup>, Gonca Ozan<sup>2</sup>, Durrin Ozlem Dabak<sup>1</sup>, Seyfettin Gur<sup>3</sup>, Ibrahim Enver Ozan<sup>1</sup>

<sup>1</sup>Firat University, Medical School, Department of Histology and Embryology, Elazig, Turkey

<sup>2</sup>Firat University, Faculty of Veterinary Medicine, Department of Biochemistry, Elazig, Turkey

<sup>3</sup>Firat University, Faculty of Veterinary Medicine, Department of Reproduction and Artificial Insemination, Elazig, Turkey

## Abstract

**Aim:** Tobacco smoke negatively affects the male reproductive system. Ellagic acid (EA) has protective effects against oxidative damage. The aim of the study was to examine the protective effects of EA on testis of rats exposed to tobacco smoke.

**Material and Methods:** Twenty-four male Sprague-Dawley rats were divided into 4 groups (n=6): Control, tobacco smoke (TS), tobacco smoke+corn oil (TS+C) and tobacco smoke+ EA (TS+EA). TS, TS+C and TS+EA groups were exposed to tobacco smoke 1 hour twice a day and EA was applied 12 mg/kg every other day. Testis tissues were removed. eNOS immunohistochemical stain and TUNEL methods were applied. Biochemical analyzes and sperm analyzes were performed.

**Results:** Degeneration in germinative epithelium, cell debris in the seminiferous tubule lumen, separation in basement membrane, atrophic tubules, vascular congestion and edema in interstitial area were observed in TS and TS+C groups. Increased apoptotic cells and eNOS immunoreactivity were observed in TS and TS+C groups. EA administration caused a decrease in histological alterations, eNOS immunoreactivity and apoptotic cells. Increased MDA levels, decreased CAT and GSH-Px activities were observed in TS and TS+C groups. MDA levels decreased, CAT and GSH-Px activities increased in TS+EA group. A significant increase in the amount of abnormal sperm was detected in TS and TS+C groups. The reduction in the amount of abnormal sperm was detected in TS+EA group.

**Conclusions:** Exposure to TS led to marked alterations on testes tissue and treatment with EA might prevent these toxic effects.

**Keywords:** Tobacco Smoke; Testis; Ellagic Acid; Rat; TUNEL.

## INTRODUCTION

Tobacco smoke has highly adverse effects on all tissues and systems in the body because of its toxic substances. The respiratory, cardiovascular and reproductive systems are mostly affected from tobacco smoke exposure (1).

Male infertility may be caused by numerous factors such as hormonal aberrations, several diseases, genetic disorders, poor semen quality and some toxic chemicals (2). It has been suggested that tobacco smoking negatively affects every process involved in the male reproductive system (3). Nitric oxide (NO), produced by three isoforms of NO synthase (neuronal NOS, inducible NOS and endothelial NOS), is a free radical and has been implicated in various reproductive functions. It is one of the numerous factors that causes oxidative stress in many cases such as testicular injury (4).

Ellagic acid (EA), (2, 3, 7, 8-tetrahydroxy [1]-benzopyranol

[5, 4, 3-cde] benzopyran 5, 10-dione), a natural phenolic lactone compound, is found in various plant species including strawberries, pomegranate, grape, blackberries and raspberries. Recent studies have shown that EA has antioxidant (5), antiapoptotic (6), anticarcinogenic (7,8), antibacterial (9) and antiinflammatory (10) effects.

EA can safely interact with the free radicals and reduces oxidative stress through the phenolic ring and hydroxyl components in its structure (11). The aim of the present study was to examine the protective effects of ellagic acid against oxidative damage on testis tissues of rats induced by tobacco smoke.

## MATERIAL and METHODS

### Ethical approval

All experimental procedures involving animals were approved by the local ethics committee of the Firat University (05.02.14, 2014/4- 42).

**Received:** 26.05.2017 **Accepted:** 18.06.2017

**Corresponding Author:** Nalan Kaya, Firat University, Medical School, Department of Histology and Embryology, Elazig, Turkey.  
E-mail: nalankaya@firat.edu.tr

### Experimental Design

This experimental study was carried out at the Experimental Research Unit of Firat University (FUDAM). Twenty-four male Sprague-Dawley rats aged eight weeks old ( $200 \pm 10$  g) were used in the study. Rats were fed with standard rat chow and tap water freely available. 12-h light-dark cycles,  $21 \pm 1$  C standard temperature and humidity conditions were provided. The rats were divided randomly into 4 equal groups: Control, tobacco smoke (TS), tobacco smoke + corn oil (TS+C) and tobacco smoke + ellagic acid (TS+EA). During 12 weeks of experimental stage, the rats treated as follows: The rats in group TS, TS+C and TS+EA were exposed to tobacco smoke 1 hour twice a day. In addition to tobacco smoke exposure, 12 mg/kg and dissolved in corn oil ellagic acid (A15722 Lot: 10176718, Ellagic acid hydrate, Alfa Aesar, Germany) was applied to the rats in group TS+EA and equal amount of corn oil used in solving ellagic acid was applied to the rats in group TS+C by oral gavage.

A glass cage, in the size of 150x50x50 cm and openable cover from the top, has been designed specifically for exposing the rats to tobacco smoke. The smoke of 10 grams tobacco was introduced into the glass cage via air pump (AP-001 Aquarium Air Pump Xilong, China). At the end of the experimental period of 12 weeks rats were decapitated under xylazine (10 mg/kg)-ketamine (75 mg/kg) anesthesia. The testes were removed rapidly and utilized for histological and biochemical analysis, as described below. Also sperm samples were taken for sperm analyzes.

### Histological evaluation

For histological analyzes testes were removed, fixed in Bouin solution and processed by using routine paraffin techniques. Bouin-fixed testis tissues were embedded in paraffin blocks and the blocks were cut into 5-6  $\mu$ m thick sections. Slides stained with hematoxylin and eosin (H&E), Periodic Acid Schiff (PAS) and Masson's Trichrome staining and examined under the light microscope (NovelN-800 M, Ningbo, China).

Severity of testicular injury was semi-quantitatively evaluated following alterations: degeneration in seminiferous tubule germinative epithelium, separation in basement membranes, vascular congestion, atrophic tubules, edema in interstitial area and immature cell debris in tubule lumen. Scores were given as 0= absent, 1= weak, 2= moderate and 3= strong for each criteria. The microscopic score of each tissue was calculated as the sum of the scores given to each criterion, and at least five microscopic areas were examined under a x20 objective to score each specimen.

### TUNEL assay

In the 5-6  $\mu$ m thickness paraffin block sections were taken to slides with poly-L-lysine. ApopTagPlus Peroxidase in Situ Apoptosis Detection Kit (Chemicon, cat no: S7101, USA) was used for detection of apoptotic cells in

accordance with the manufacturer's instructions for use. In the evaluation of TUNEL staining, cells with blue nuclei were normal, while brown nuclear staining was admitted as representing apoptotic cells. At least 500 cells were counted on each field. Apoptotic index was calculated as a ratio of the TUNEL - positive cell number to the total cell number (normal + apoptotic cells).

### Immunohistochemical evaluation

Avidin-biotin-peroxidase complex method was used to determine endothelial nitric oxide synthase (eNOS) immunoreactivity (PA1712-1 Lot No: 01714jd011231, Polyclonal Anti-NOS3 Antibody, Boster Immunoleader) in testicular tissue. The immunohistochemical histoscore was created on the basis of immunoreactivity prevalence (0.1: < 25%, 0.4: 26-50%, 0.6: 51-75%, 0.9: 76-100 %) and severity (0: no, +0.5: very little, +1: little, +2: medium, +3: severe). (Histoscore = prevalence  $\times$  severity)

### Biochemical evaluation of testes tissue

For biochemical analyzes testes were taken and stored at  $-80^{\circ}\text{C}$  until analysis. The concentrations of MDA as a marker of lipid peroxidation were determined according to a modified method of Placer (1966), based on the reaction with thiobarbituric acid, and were expressed as nmol g tissue $^{-1}$  (12). CAT activity was determined by measuring the decomposition of hydrogen peroxide at 240 nm, according to the method of Aebi (1983) and was expressed as k (g protein $^{-1}$ ), where k is the first-order rate constant (13). Protein concentrations were measured according to Lowry et al. (1951) (14). GSH-Px activity was determined using the method of Beutler (1975), which records at 340 nm the disappearance of NADPH and was expressed as U/g protein (15).

### Evaluation of sperm parameters

The epididymal sperm concentration was determined with a hemocytometer using a modified method described by Turk et al. (16) and Sonmez et al. (17). The percentage of forward progressive sperm motility was assessed using a light microscope with heated stage as described by Sonmez et al. (18).

Three different fields in each sample were evaluated under a light microscope at 400 magnifications. The mean of these three values was used as the final motility score. To detect the percentage of morphologically abnormal spermatozoa, the slides stained with eosinenigrosin (1.67% eosin, 10% nigrosin and 0.1 M sodium citrate) and evaluated under a light microscope at 400 magnifications.

### Statistical analysis

All statistical analyzes were performed using SPSS 22.0 (Statistical Package for Social Sciences) software. Results were presented as the means  $\pm$  standard deviation. Probability values (p) less than 0.05 were accepted as statistically significant. Statistical differences of multiple groups with normal distribution were measured by one-way analysis of variance (ANOVA) followed by Tukey's multiple comparison test.



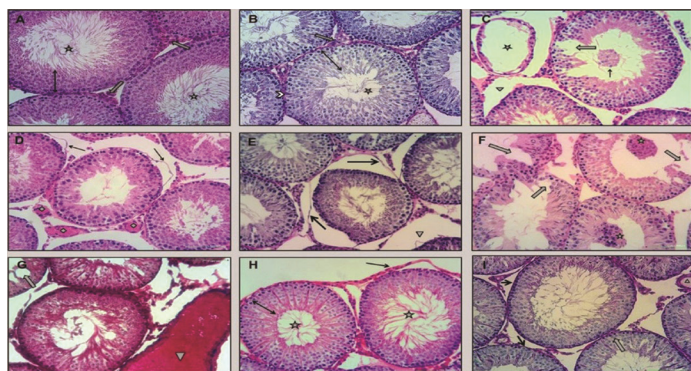
## RESULTS

### Histological evaluation

The histological examination by light microscope of rat testis tissues showed normal morphology in the control group (Figure 1A, 1B).

When TS group compared with control group; degeneration in seminiferous tubule germinative epithelium, separation in basement membranes, vascular congestion, atrophic tubules, edema in interstitial area and immature cell debris in tubule lumen were detected (Figure 1C, 1D, 1E).

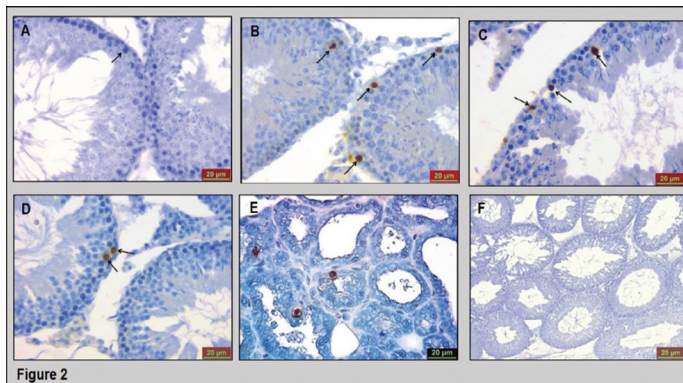
On the other hand, in TS+C group the similar findings were detected with the TS group (Figure 1F, 1G). The significant improvements were observed in germinative epithelium degeneration, separation of seminiferous tubule basement membranes, vascular congestion and interstitial edema in TS+EA group (Figure 1H, 1I). The results of the histological scoring of the testis tissues are shown in Figure 4A.



**Figure 1.** Photomicrographs of testis sections (scale bars: 20 micrometer) showing: (A) control group normal seminiferous tubule germinative epithelium (double-headed arrow), sperms (star), Leydig cells (thick arrow) (H&E); (B) control group normal seminiferous tubule germinative epithelium (double-headed arrow), sperms (star), basement membrane (arrowhead) (PAS); (C) TS group atrophic tubules (star), edema in interstitial area (trigon), degeneration in seminiferous tubule germinative epithelium (thick arrow) and immature cell debris in tubule lumen (thin arrow) (H&E); (D) TS group separation in basement membranes (arrow), vascular congestion (tetragon) (H&E); (E) TS group separation in basement membranes (arrow) and edema in interstitial area (trigon) (PAS); (F) TS+C group degeneration in seminiferous tubule germinative epithelium (thick arrow) and immature cell debris in tubule lumen (star) (H&E); (G) TS+C group vascular congestion (trigon) (Masson's Trichrome); (H) TS+EA group normal sperms (star), basement membranes (thin arrow) and seminiferous tubule germinative epithelium (double-headed arrow) (H&E); (I) TS+EA group normal basement membranes (thin arrow) and seminiferous tubule germinative epithelium (thick arrow) and decreased vascular congestion (trigon) (PAS).

### Evaluation of apoptosis in testis tissues

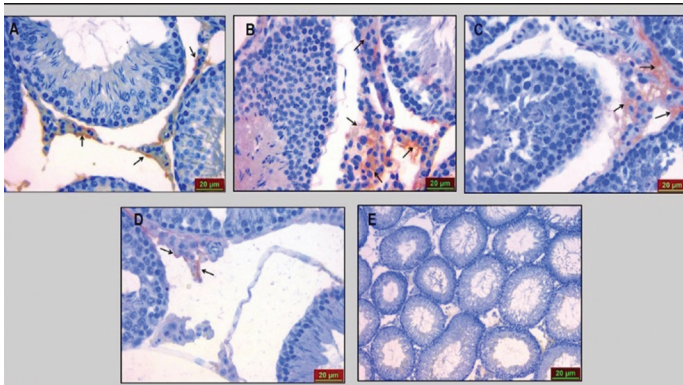
In TUNEL positive cell numbers in TS and TS+C groups compared to the control group, a significant increase was detected. The number of TUNEL positive cells was evaluated in TS+EA group similar to control group (Figure 2). The results of the apoptotic index are shown in Figure 4B.



**Figure 2.** TUNEL findings of the groups. (A) Control group, a TUNEL positive cell (arrow), (B) TS group, numerous TUNEL positive cells (arrows), (C) TS+C group, numerous TUNEL positive cells (arrows), (D) TS+EA group, a few TUNEL positive cells (arrows), (E) Positive control (breast tissue), (F) Negative control.

### Immunohistochemical findings- eNOS immunoreactivity

eNOS immunoreactivity was observed only in the interstitial area of the testis. Significantly increased eNOS immunoreactivity was observed in TS and TS+C group compared with the control group. On the other hand, eNOS immunoreactivity decreased in TS+EA group similar to control group (Figure 3). The results of the eNOS immunoreactivity histoscore are shown in Figure 4B.



**Figure 3.** eNOS immunoreactivity of the groups. (A) Control, (B) TS, (C) TS+C, (D) TS+EA, (E) Negative control.

### Biochemical Results

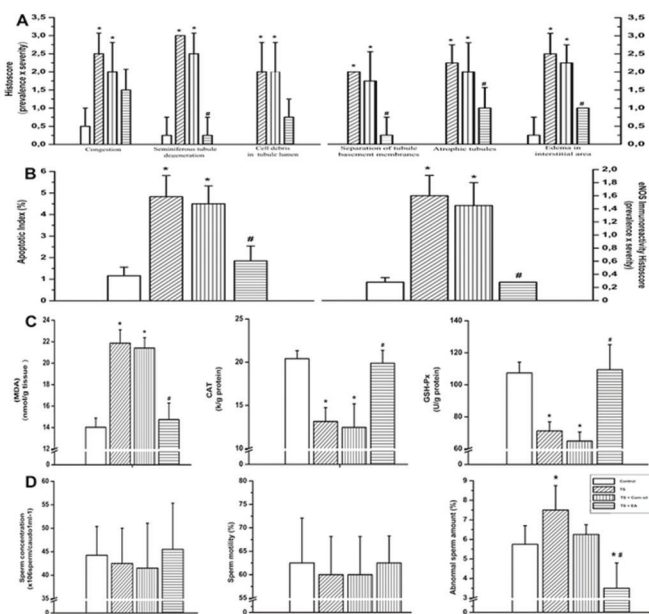
The levels of MDA, CAT and GSH-Px activities were shown in Figure 4C. In TS and TS+C groups compared with the control group a significantly increase was detected in the levels of MDA.

It was found that ellagic acid administration reduced the MDA levels similar to the control group. CAT and GSH-Px enzyme activities in TS and TS+C groups were significantly decreased compared to the control group. Also significantly increase in CAT and GSH-Px enzyme activities was detected in TS+EA group compared with TS and TS+C groups.

### Sperm Analyzes

The difference of sperm motility and sperm concentration among the groups wasn't found significantly. A significant increase in abnormal sperm amount was detected in TS

group compared with control group. The reduction in the amount of abnormal sperm was found in TS+EA group compared with TS group. The results of sperm motility, sperm concentration and abnormal sperm amount are shown in Figure 4D.



**Figure 4.** (A) The histological scores of groups, (B) The apoptotic index and eNOS immunoreactivity histoscore of groups, (C) Testes tissue MDA, CAT and GSH-Px levels, (D) Sperm motility, sperm concentration and abnormal sperm amount of groups.

**DISCUSSION**

Smoking may decrease the sperm count, affect the development and quality of sperm and reduce the volume of semen (19). Toxins found in tobacco smoke such as nicotine, cadmium, benzo pyrene and related by-products can damage the genetic material in sperm cells (20).

Yamamoto et al. (21) reported that exposed to tobacco smoke decreased the sperm amount, motility and fertilization capacity. Kapawa et al. (22) detected that exposed to tobacco smoke for 10 weeks decreased in the percentage of motile sperm.

In this study, the difference of sperm motility and sperm concentration among the groups wasn't found statistically significant. On the other hand, the increasing of abnormal sperm number was detected in TS group compared with the control group.

Spermatogenic cell degeneration and seminiferous tubule germinative epithelium degradation have been detected in testis tissues of Wistar rats exposed to tobacco smoke 2 h/day during 60 days (23).

In the present study, there were seminiferous tubule germinative epithelium degeneration, basement membranes separation, vascular congestion, atrophic

tubules and edema in interstitial area in TS group.

When the external stimuli disrupting the internal balance of testis, apoptosis occurs in high levels. Infertility and deterioration of spermatogenesis may occur depending on this condition (24-26). Rajpurkar et al. (27) reported that exposure to tobacco smoke caused an increase in apoptotic index in peripubertal period of Sprague- Dawley rats. In another study conducted on rats exposed to tobacco smoke 3 h/day for 8 weeks seminiferous tubule degeneration, increase in atrophic tubules number and apoptotic index were observed (28). In this study it was also found that exposed to tobacco smoke significantly increased the apoptotic index.

As we showed by TUNEL, there are increased apoptotic index in some germinal series. On the other hand, cellular debris, edema and separation of the basement membranes are patterns of the necrosis. Even if cell death mechanisms and morphological changes of apoptosis and necrosis differ, apoptotic pathway can be induced a necrotic phenotype by alteration of the availability of intracellular ATP and caspases. Therefore, we believe that apoptosis is much more responsible for tobacco smoke-induced testicular damage.

The correlation among the increased apoptotic germ cells and NOS activity concurrent with decreased total antioxidant capacity has been reported (29). It was revealed that eNOS immunoreactivity increased in testicular damage induced by cadmium (30). In our study it was also detected that increased eNOS immunoreactivity exposed to tobacco smoke.

Spermatozoa are very sensitive to ROS-induced damage because of polyunsaturated fatty acids (PUFA) in plasma membranes and a few scavenging enzymes in cytoplasm (31,32). Increasing free radicals can induce lipid peroxidation that causes deterioration by oxidizing polyunsaturated fatty acids. Peroxidation of sperm lipids can damage the matrix of spermatozoa membran lipids. Loss of intracellular ATP cause the reduction sperm motility, axonal injury and defective sperm neck (33,34). Tobacco smoke contains a high concentration of reactive oxygen species (ROS) and these radicals give rise to oxidative stress by impairing oxidant- antioxidant balance (35). Defense mechanism develops against oxidative damage by using different antioxidant enzymes if ROS accumulation occurs. CAT and GSH-Px are two important enzymes in this pathway (36). It is evaluated that exposed to tobacco smoke for 30 min four times a day caused to increase in MDA levels and decrease in CAT and GSH-Px levels (37). There is no information found in literature how EA play a role against the effect of tobacco smoke exposure on testes. But it is reported that EA is a power antioxidant (38).

It was observed that increase in the percentage of abnormal sperm, necrosis in spermatogenic cells, tubular degeneration and atrophy, interstitial edema, vascular congestion, immature cell debris in testicular damage



caused by 15 mg/kg cyclosporin-A and 7mg/kg cisplatin. It has been reported that 10mg/kg ellagic acid exhibit protective effect on testes by providing reduction many of these findings. Also, in the same study application of cyclosporin-A caused increasing in MDA-level, decreasing in GSH-Px and CAT levels. It was reported that EA administration inhibited the oxidative stress-induced tissue damage by preventing this changes (39,34). Administration of 2mg/kg EA reduced lipid peroxidation and decreased apoptotic cell number by protective effects against to testicular damage formed by adriamisin (40).

The findings of our study are in agreement with the literature. According to our results it was found that tobacco smoke exposure increased the lipid peroxidation and reduced antioxidant enzymes CAT and GSH-Px levels, as well as the EA application reduced lipid peroxidation and increased antioxidant enzyme levels in the testicular tissue.

## CONCLUSION

Ellagic acid decreased abnormal sperm number and ameliorated the seminiferous tubule degeneration, vascular congestion, interstitial edema and seminiferous tubule basement membrane separations, likewise decreased lipid peroxidation and increased antioxidant enzyme activities in rat testes exposed to tobacco smoke due to its antioxidant effects. Ellagic acid can be useful for the protection from adverse effects of tobacco smoke.

## REFERENCES

1. The Tobacco Atlas. World Health Organization. Brighton, 2002;32-3.
2. Sabanegh Jr ES, Agarwal A. Male infertility. In: Wein A, ed. Campbell-Walsh Urology. Philadelphia, Elsevier Saunders, 2011;616-47.
3. Soares SR, Simon C, Remohí J, Pellicer A. Cigarette smoking affects uterine receptiveness. Hum Reprod 2007;22(2):543-7.
4. Shiraishi K, Naito K. Nitric oxide produced in the testis is involved in dilatation of the internal spermatic vein that compromises spermatogenesis in infertile men with varicocele. BJU Int 2007;99(5):1086-90.
5. Singh K, Khanna AK, Visen PK, Chander R. Protective effect of ellagic acid on t-butyl hydroperoxide induced lipid peroxidation in isolated rat hepatocytes. Indian J Exp Biol 1999;37(9):939-40.
6. Khanduja KL, Avti PK, Kumar S, Mittal N, Sohi KK, Pathak CM. Anti-apoptotic activity of caffeic acid, ellagic acid and ferulic acid in normal human peripheral blood mononuclear cells: a Bcl-2 independent mechanism. Biochim Biophys Acta 2006;1760(2):283-9.
7. Turk G, Ceribasi AO, Sakin F, Sonmez M, Atessahin A. Antiperoxidative and anti-apoptotic effects of lycopene and ellagic acid on cyclophosphamide-induced testicular lipid peroxidation and apoptosis. Reprod Fertil Dev 2010;22(4):587-96.
8. Li TM, Chen GW, Su CC, Lin JG, Yeh CC, Cheng KC, et al. Ellagic acid induced p53/p21 expression, G1 arrest and apoptosis in human bladder cancer T24 cells. Anticancer Res 2005;25(2A):971-9.
9. Abuelsaad AS, Mohamed I, Allam G, Al-Solumani AA. Antimicrobial and immunomodulating activities of

- hesperidin and ellagic acid against diarrheic aeromonas hydrophila in a murine model. Life Sci 2013;93(20):714-22.
10. Promsong A, Chung Wo, Sathakarn S, Nittayananta W. Ellagic acid modulates the expression of oral innate immune mediators: potential role in mucosal protection. J Oral Pathol Med 2015;44(3):214-21.
11. Mates JM, Sanchez-Jimenez F. Antioxidant enzymes and their implications in pathophysiological processes. Front Biosci 1999;15(4):D339-45.
12. Placer ZA, Cushman LL, Johnson BC. Estimation of product of lipid peroxidation (malonyl dialdehyde) in biochemical systems. Anal Biochem 1966;16(2):359-64.
13. Aebi H. Catalase. In: Bergmeyer HU, ed. Methods in Enzymatic Analysis. New York: Academic Press, 1983:276-86.
14. Lowry OH, Rosebrough NJ, Farr AL, Randall RJ. Protein measurement with folin phenol reagent. J Biol Chem 1951;193(1):265-75.
15. Beutler E. Red cell metabolism. In: A Manual of Biochemical Methods. New York: Grune Stroutan 1975:67-9.
16. Turk G, Atessahin A, Sonmez M, Yuce A, Ceribasi AO. Lycopene protects against cyclosporine A-induced testicular toxicity in rats. Theriogenology 2007;67(4):778-85.
17. Sonmez M, Yuce A, Turk G. The protective effects of melatonin and vitamin E on antioxidant enzyme activities and epididymal sperm characteristics of homocysteine treated male rats. Reprod Toxicol 2007;23(2):226-31.
18. Sonmez M, Turk G, Yuce A. The effect of ascorbic acid supplementation on sperm quality, lipid peroxidation and testosterone levels of male Wistar rats. Theriogenology 2005;63(7):2063-72.
19. U.S. Department of Health and Human Services, Centers for Disease Control and Prevention, National Center for Chronic Disease Prevention and Health Promotion, Office on Smoking and Health, 2004.
20. British Medical Association. Smoking and reproductive life: The impact of smoking on sexual, reproductive and child health. Board of Science and Education and Tobacco Control Resource Centre, February 2004.
21. Yamamoto Y, Isoyama E, Sorkitis N, Miyagawa I. Effects of smoking on testicular function and fertilizing potential in rats. Urol Res 1998;26(1):45-8.
22. Kapawa A, Giannakis D, Tsoukanelis K, Kanakas N, Baltogiannis D, Agapitos E, et al. Effects of paternal cigarette smoking on testicular function, sperm fertilizing capacity, embryonic development and blastocyst capacity for implantation in rats. Andrologia 2004;36(2):57-68.
23. Guven MC, Can B, Ergun A, Saran Y, Aydos K. Ultrastructural effects of cigarette smoke on rat testis. Eur Urol 1999;36(8):645-9.
24. Kerr JF, Wyllie AH, Currie AR. Apoptosis. A basic biological phenomenon with wide ranging implications in tissue kinetics. Br J Cancer 1972;26(4):239-57.
25. Cohen JJ. Overview: Mechanisms of apoptosis. Immunol Today 1993;14(3):126-30.
26. Korsmeyer SJ. Regulators of cell death. Trends Genet 1995;11(3):101-5.
27. Rajpurkar A, Jiang Y, Dhabuwala CB, Dunbar JC, Li H. Cigarette smoking induces apoptosis in rat testis. J Environ Pathol Toxicol Oncol 2002;21(3):243-8.
28. Ozkan L, Yardimoglu M, Ozkurkcuoglu C. Protective effects of pentoxifylline on the seminiferous tubules morphology in smoking rats. Research Web Pub 2013;1:1-7.
29. Shikone T, Billig H, Hsueh AJ. Experimentally induced cryptorchidism increases apoptosis in rat testis. Biol Reprod 1994;51(5):865-72.

30. Sonmez MF, Tascioglu S. Protective effects of grape seed extract on cadmium-induced testicular damage, apoptosis, and endothelial nitric oxide synthases expression in rats. *Toxicol Ind Health* 2016;32(8):1486-94.
31. Aitken RJ, McLaughlin EA. Molecular mechanisms of sperm capacitation: progesterone induced secondary calcium oscillations reflect the attainment of a capacitated state. *Soc Reprod Fertil Suppl* 2007;63:273-93.
32. Agarwal A, Makker K, Sharma R. Clinical relevance of oxidative stress in male factor infertility: an update. *Am J Reprod Immunol* 2008;59(1):2-11.
33. Turk G, Atessahin A, Sonmez M, Yuce A, Ceribası AO. Lycopene protects against cyclosporine A-induced testicular toxicity in rats. *Theriogenology* 2007;67(4):778-85.
34. Turk G, Atessahin A, Sonmez M, Ceribası AO, Yüce A. Improvement of cisplatin induced injuries to spermquality, the oxidant-antioxidant system, and the histologic structure of the rat testis by ellagic acid. *Fertil Steril* 2008;89(Suppl 5):1474-81.
35. Junqueira LC, Carneiro J. *Basic Histology*. Nobel Tıp Kitabevi, İstanbul 2009;418-27.
36. Mates JM. Effects of antioxidant enzymes in the molecular control of reactive oxygen species toxicology. *Toxicology* 2000;153(1-3):83-104.
37. Ozyurt H, Pekmez H, Parlaktas BS, Kus I, Ozyurt B, Sarsilmaz M. Oxidative stress in testicular tissues of rats exposed to cigarette smoke and protective effects of caffeic acid phenethyl ester. *Asian J Androl* 2006;8(2):189-93.
38. Zafrilla P, Ferreres F, Tomás-Barberán FA. Effect of processing and storage on the antioxidant ellagic acid derivatives and flavonoids of red raspberry (*Rubus idaeus*) jams. *J Agric Food Chem* 2001;49(8):3651-5.
39. Turk G, Ceribası AO, Sakin F, Sonmez M, Atessahin A. Antiperoxidative and anti-apoptotic effects of lycopene and ellagic acid on cyclophosphamide-induced testicular lipid peroxidation and apoptosis. *Reprod Fertil Dev* 2010;22(Suppl 4):587-96.
40. Ceribası AO, Sakin F, Turk G, Sonmez M, Atessahin A. Impact of ellagic acid on adriamycin-induced testicular histopathological lesions, apoptosis, lipid peroxidation and sperm damages. *Exp Toxicol Pathol* 2012;648(7-8):717-24.