

Complicated retrocaecal appendicitis resulting in mortality in a schizophrenic patient

Serdar Kirmizi

Denizli State Hospital, Gastroenterology Surgery, Denizli, Turkey

Abstract

Acute appendicitis is the most common urgent surgical condition observed in patients over 65 years of age after biliary tract diseases and gastrointestinal obstructions. Ileo-caecal position of the appendix determines the possible clinical condition. The findings for peritonitis in retrocaecal appendicitis are indefinite, and diagnosis would be more difficult if advanced age and psychiatric disorders are also present in addition to these indefinite findings. A 67-year-old female patient with schizophrenia who had percutaneous drainage due to retroperitoneal abscess was referred to our clinic. Diffuse retroperitoneal abscess and perforated retrocaecal appendicitis were detected during laparotomy. The patient lost her life due to multiple organ failure after three weeks. As in the present case, an interrogator approach and an early diagnosis and treatment in old patients with psychiatric disorders would reduce the mortality.

Keywords: Schizophrenic; Retroperitoneal Abscess; Retrocaecal Appendicitis.

INTRODUCTION

An important cause for retroperitoneal abscess is retrocaecal appendicitis. Classical symptoms, patient's history and physical examination are usually sufficient for diagnosis; however, an atypical clinical presentation of retrocaecal appendicitis without any finding of peritonitis would make the diagnosis difficult. The addition of a psychiatric disorder into the clinical presentation may create a more difficult condition and increase morbidity and mortality. A case with retroperitoneal abscess in a 67-year-old patient who was diagnosed with retrocaecal appendicitis and resulted in mortality was presented in this article.

CASE REPORT

A 67-year-old female patient was referred to our clinic due to retroperitoneal abscess. Findings, such as confusion, subcutaneous edema on right lumbar area, percutaneous drainage and morbid obesity (Body mass index 37kg/m²) were detected in physical examination. Based on the patient's history, it was found that she had diabetes mellitus type-2 and schizophrenia. It was also found that she had previously undergone a surgery due to perforation of peptic ulcer and another surgery because of trauma-dependent right hip fracture. Diffuse right retroperitoneal abscess extending from right pelvic site to diaphragm

was detected in Computed Tomography (CT) of Abdomen and Thorax (Figure 1-2).

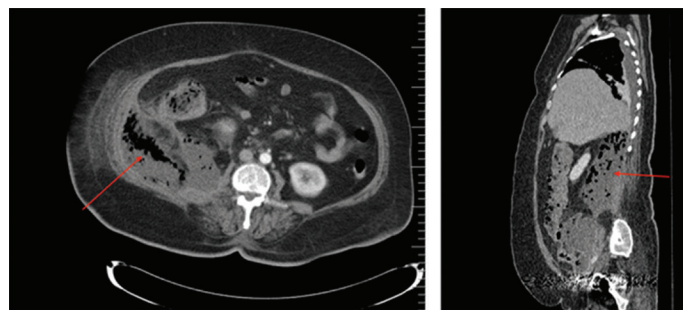


Figure 1-2. Invasion of retroperitoneal abscess on abdomino-axial and Thoraco-abdominal slices at sagittal plane.

Since percutaneous drainage was insufficient and the patient was in a septic condition, laparoscopic abscess drainage procedure was planned. Laparoscopy was performed to the patient. First, the right colon was deviated to the medial side from hepatic flexura. Then, the abscess was drained. Food residues which were considered to be the result of upper gastrointestinal perforation were observed; therefore, laparotomy was decided. Following the laparotomy, it was seen that there was not any abscess or food residues in intraperitoneal site. Kocher's maneuver was performed and no perforation was

Received: 08.05.2017 Accepted: 23.06.2017

Corresponding Author: Serdar Kirmizi, Gastroenterology Surgery, Denizli State Hospital, Denizli, Turkey
E-mail: drserdarkirmizi@hotmail.com

detected in dueodenum. When the cecum was deviated to the medial side, appendix could not be found due to necrosis; however, perforated retrocaecal appendix stump was observed (Figure 3).

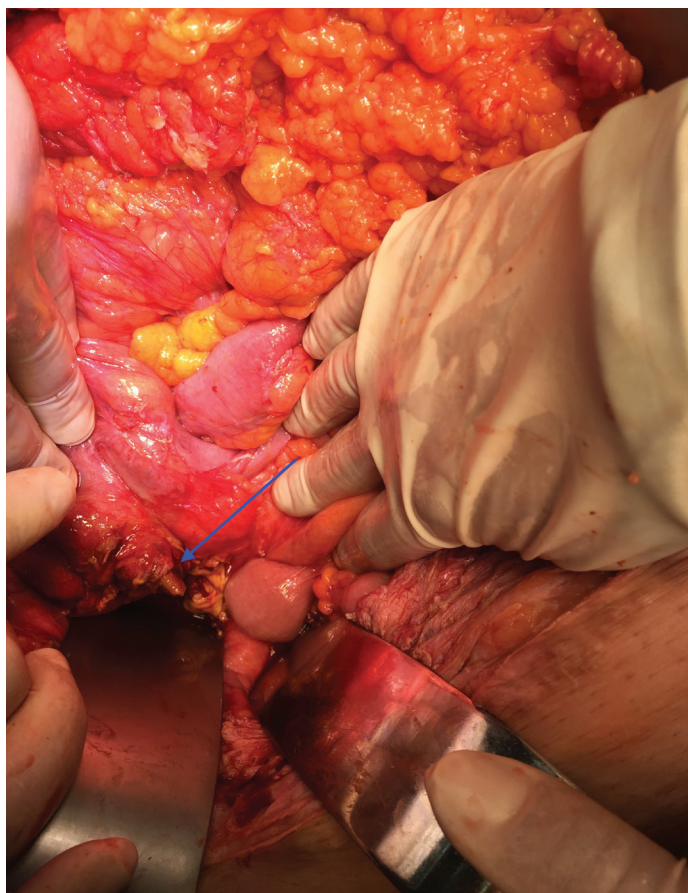

Figure 3. Intraoperative appearance of appendix body.

Primary repair and omentoplasty were applied and multiple drain was placed. The patient was monitored in intensive care unit and CT appearance of retroperitoneal site was normal at 7th and 14th days (Figure 4-5) in the post-surgery period. However, the patient lost her life due to sepsis and multiple organ failure after three weeks.

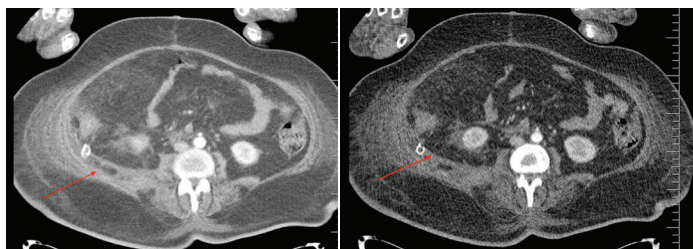


Figure 4-5. Retroperitoneal abscess completely disappeared on abdominal CT at postoperative days 7 and 14.

DISCUSSIONS

Acute appendicitis is the most common cause for acute abdomen requiring surgery in general population; however, biliary tract pathologies, gastrointestinal obstructions are more commonly observed among the patients over 65 years of age (1). Despite the medical and technological

developments, there is no diagnostic method that yields a hundred-percent accuracy. Therefore, a detailed investigation of a patient's history as well as a careful physical examination are quite essential in both elder patients and patients with psychiatric disorders. Laboratory and imaging tests are generally used to support clinical findings and eliminate differential diagnosis. Ileo-caecal position of the appendix changes according to shape and position of the caecum during embryologic development. It may exist on different positions from subhepatic site to pelvic area.

The most common position of the appendix is intraabdominal location and the second most common one is retrocaecal site (2). Some articles specified that retrocaecal appendicitis was detected in 25 to 65 per cent of the general population (3). Retroperitoneal appendicitis may cause abscess formation extending from diaphragm to the scrotum and even to the thighs. Retroperitoneal abscesses are rare conditions detected in middle-aged men in general (4).

Primary and secondary causes of retroperitoneal abscess were defined in the literature. The primary causes mostly appear as a result of the invasion of the pathogen agent to lumbar bone, muscle and soft tissues through hematogenous tract. The secondary causes stem from genitourinary and gastrointestinal organs in retroperitoneal site (5). Diabetes, malignency, gastrointestinal and genitourinary procedures or operations are the risk factors. First approach for treatment is percutaneous drainage. However, if the cause is considered to be gastrointestinal origin, laparotomy is recommended. In elder patients, the progression of perforated appendicitis is worse and the risk of perforation is higher. Almost half of the patients may be misdiagnosed and more than 25 per cent are diagnosed too late (6). In such poor conditions, existence of a psychiatric disorder may create a difficult case to resolve. Jen Huoy Tsay et al. found in their research that the risk for perforated appendicitis among the patients with schizophrenia is 2.83 times more common than normal population (7).

Ultrasonographic diagnosis and percutaneous drainage are also useful; however, tomography is more comprehensive. Sensitivity and specificity of computed tomography are higher and they provide determination of the complications. Thickening on appendix wall, contrast uptake, lumen dilatation, density increase on adjacent fat tissue and inflammation findings support diagnosis of appendicitis (8). However, appendix was completely necrotized in our case and thus this may contribute to misdiagnosis.

In the last five years, a total of 4345 patients have been operated on acute appendicitis at our hospital. Of those operations, 3455 of them were open appendectomy and 890 were laparoscopic appendectomy. 59 of these patients were found to be schizophrenic. Thirteen patients, one of whom was schizophrenic, died due to acute appendicitis complications.

CONCLUSION

A sceptic approach to elder and schizophrenic patients who have complaints of abdominal pain coupled with early intervention and treatment would reduce mortality rates.

REFERENCES

1. Konan A, Hayran M, Kilic YA, Karakoç D, Kaynaroglu V. Scoring systems in the diagnosis of acute appendicitis in the elderly. *Ulus Travma Acil Cerrahi Derg* 2011;17(5):396-400.
2. Ong EM, Venkatesh SK. Ascending retrocecal appendicitis presenting with right upper abdominal pain: utility of computed tomography. *World J Gastroenterol* 2009;15(28):3576-9.
3. Rao PM, Rhea JT, Novelline RA, Mostafavi AA, Lawrason JN, McCabe CJ. Helical CT combined with contrast material administered only through the colon for imaging of suspected appendicitis. *AJR Am J Roentgenol* 1997;169(5):1275-80.
4. Huang SH, Lo WO, Lin CM, Hsieh TS, Wang SF, Tsai SW. Retroperitoneal abscess: 7-year experience of 29 cases in a tertiary care center in Taiwan. *Urol Sci*, 2015;26(3):218-21.
5. Capitán Manjón C, Tejido Sánchez A, Piedra Lara JD, Martínez Silva V, Cruceyra Betriu G, Rosino Sánchez A, et al. Retroperitoneal abscesses. *Scand J Urol Nephrol*, 2003;37(2):139-44.
6. Storm-Dickerson TL, Horattas MC. What have we learned over the past 20 years about appendicitis in the elderly? *Am J Surg* 2003;185(3):198-201.
7. Tsay JH, Lee CH, Hsu YJ, Wang PJ, Bai YM, Chou YJ, et al. Disparities in appendicitis rupture rate among mentally ill patients. *BMC Public Health* 2007;7(1):331.
8. Cobben LP, Bakker OJ, Puylaert JB, Kingma LM, Blickman JG. Imaging of patients with clinically suspected appendicitis in the Netherlands: conclusions of a survey *Br J Radiol* 2009;82(978):482-5.