

The maxillonasal dysplasia

Medhini Madi, Subhas G Babu, Supriya Bhat, Ananya Madiyal

Department of Oral Medicine and Radiology A.B. Shetty Memorial Institute of Dental Sciences NITTE University, Deralakatte, Mangalore: 575018

Dear Editor,

Maxillonasal dysplasia also called Binder's syndrome is a congenital deformity characterized by nasomaxillary hypoplasia that is attributed to underdeveloped mid-facial skeleton (1). They have a characteristic appearance that is effortlessly identifiable (2). Binder, who first defined this syndrome as a distinct clinical entity in 1962, attributed the cause of this syndrome to the disturbance of the prosencephalic induction center during embryonic life (3). Noyes in 1939 described the salient features of Binder's syndrome (4). Binder reported 3 cases and presented 6 characteristic features for this syndrome (5). Arhinoid face, abnormal position of the nasal bones, intermaxillary hypoplasia with consecutive malocclusion, reduced or absent anterior nasal spine, atrophy of the nasal mucosa and absence of the frontal sinus.

The third month of pregnancy marks the period in which the process of nose formation generally takes place (6). There is equal predilection for males and females. This syndrome is rare, which may be a reason for the dearth of information regarding its true cause, patterns of inheritance and actual prevalence (7).

A 19 year old female patient visited the Department of Oral Medicine and Radiology with a chief complaint of defective nose since birth. Patient complained of associated nasal twang in the tone of her voice. Patient gave a history of irregularly placed upper and lower front teeth since the time of its eruption. Prenatal, natal, post-natal history and family history was non-contributory.

On extraoral examination patient was found to have concave facial profile, absent nasofrontal angle, hypoplastic nose with flattened alae and nasal tip, flattening of right and left cheek. There is a palpable depression in the anterior nasal floor and localized maxillary hypoplasia in the alar base region. Nose was hypoplastic, with flattened alae and short columella. The nostrils are half-moon shaped when viewed from below, increased mandible gonial angle,

flattened chin, relative mandibular prognathism, convex contour of the upper lip, hypertelorism, poorly developed philtral crests, and presence of hypoplastic premaxilla.

Intraoral examination revealed flattening of the maxillary base, shortening of dental arch, decay in relation to 36,37, crossbite with respect to right and left mandibular canine and left mandibular premolar. There is also anterior open bite in relation to 31, 32, 33 and 34 and Angles Class I malocclusion (Figure 1).

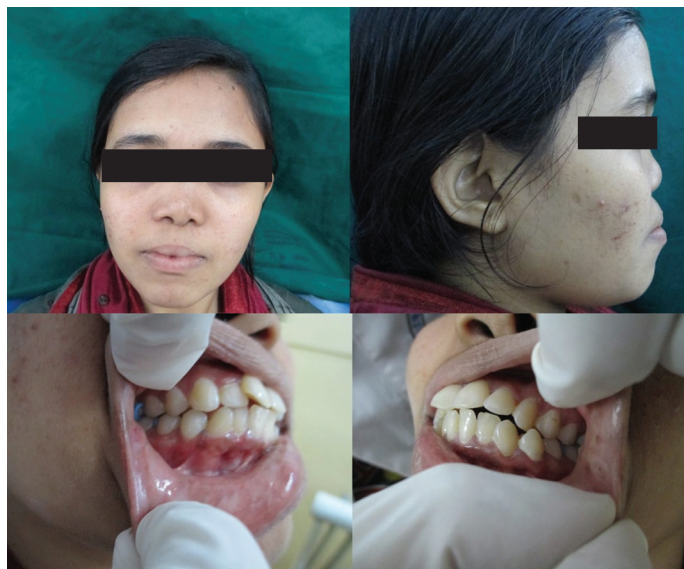

Figure 1. Photograph Showing The Extroral And Intraoral Features of Binder's Syndrome

Panoramic radiograph reveals normal condylar and coronoid process, full complement of maxillary and mandibular teeth, rotated 33,43 and mesioangular impacted 48. Lateral cephalogram shows hypoplasia of the anterior nasal spine, thinness of the labial plate of the alveolar bone over the upper incisors, increase in the nasomaxillary angle, increased gonial angle, proclination of the incisors, retrognathic maxilla, increased height of

Received: 05.07.2017 Accepted: 26.07.2017

Corresponding Author: Medhini Madi, Department of Oral Medicine and Radiology A.B. Shetty Memorial Institute of Dental Sciences NITTE University, Deralakatte, Mangalore: 575018, E-mail: medhkat@gmail.com

lower third of the face and decreased anterior cranial base measurements. PA Skull radiograph reveals hypoplastic frontal sinuses (Figure 2).

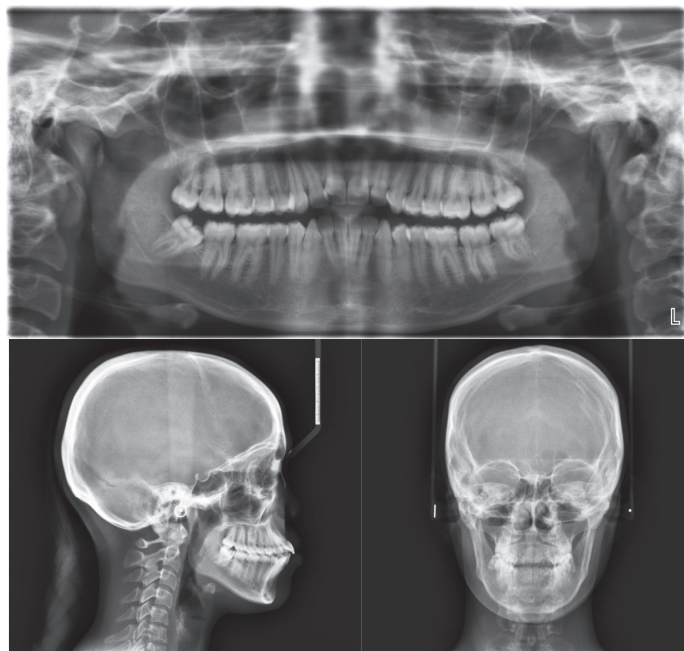


Figure 2. Panoramic Radiograph, Lateral Cephalogram And Postero-Anterior Radiographic View Of The Skull Revealing Radiographic Changes In Binder's Syndrome

Based on clinical and radiographic features, a diagnosis of Binder's syndrome was arrived at. Warfarin embryopathy, Down syndrome, Apert syndrome, Stickler syndrome, Keutel syndrome and acrodysostosis were considered as differential diagnosis.

Majority of cases of Maxillonasal dysplasia are isolated. Few cases have been reported where positive family history was stated in 36% of the subjects Therefore the inheritance pattern may be either autosomal recessive with reduced penetrance or multifactorial in nature. There are reports that Binder's syndrome has a direct relationship with vitamin K deficiency (8).

Arhinoid face with a vertical and flattened nose, mid-face hypoplasia, reduced nasal spine, atrophied nasal mucosa, malocclusion, lack of frontal sinus are the most common features. There may be concave facial profile, reduced naso-frontal angle, hypertelorism and short columella. When observed from below, the nostrils, have a semi-lunar or a half moon or crescent shape. In severe cases, it may be triangular in shape. According to Holmstroem et al in normal human beings naso-labial angle is 103–117°, while in Binder's syndrome it has a value of 76–88° (6,7).

The anterior crest that separates the floor of nasal cavity is absent, and there is a hypoplastic or absent anterior nasal spine resulting in a flat facial profile without a nasal prominence. Short anterior cranial base, posteriorly positioned maxilla, which leads to Class III malocclusion and relative prognathism is seen. Some patients may present a cleft palate (7).

Binder's syndrome can be easily diagnosed by using 2D and 3D ultrasonography, from the commencement of the 21st week of pregnancy. Several syndromes are considered among the differential diagnosis of Binder's syndrome (Table 1) (9).

Table 1. Differential Diagnosis of Binder's Syndrome (9)

Differential Diagnosis	Clinical Features
Chondroplasia punctata	flat nose, flat face, scoliosis, shortening of ribs
Robinow syndrome	flat face, hypertelorism, short arms, short stature, macrocephaly, mid-face hypoplasia, brachydactyly, clinodactyly, large nasal bridge, short upturned nose
Aarskog syndrome	flat nose, hypertelorism, clinodactyly, brachydactyly, poorly developed mid-section of face, short fingers and toes with mild webbing, small nose with nostrils tipped forwards
Crouzon syndrome	Mid-facial hypoplasia, hypertelorism, short occipital-frontal diameter, craniosynostosis, prominent nasal bridge, strabismus,
Apert syndrome	flat nose, hypertelorism, hypoplastic maxilla, craniosynostosis, flat occiput, short occipital-frontal diameter, syndactyly, ventriculomegaly, deformity of the hands and feet, with symmetric syndactyly of the second, third and fourth digits
Achondroplasia	Depressed nasal bridge, mid-facial retrusion, megaloccephaly, short fingers, small stature, large head, frontal bossing,
Fetal warfarin syndrome	flat face, stippled epiphyses, hypoplasia of nasal bridge, pectus carinatum, congenital heart defects, telebrachydactyly
Rudiger syndrome	flat nose, short digits
Stickler syndrome	flat face, micrognathia, cleft palate, talipes, osteochondroplasia
Down syndrome	flat nose, flat face, macroglossia, congenital heart diseases, short stature, brushfield spots, microgenia, dermatoglyphs, upslanting palpebral fissures, epicanthic folds, brachycephaly
Keutel syndrome	flat nose, abnormal cartilage calcification, neural hearing loss, peripheral pulmonary stenoses, brachytelephalangism, brachytelephalangism, sloping forehead, midface hypoplasia and receding chin
Desbuquois dysplasia	flat nose, flat face, "monkey-like" appearance, advanced bone maturation, vertebral changes, short stature, kyphoscoliosis

On the basis of the degree of facial deformity, orthodontic procedures and surgical treatments can be planned and is tailor made for the particular individual. Augmentation of the premaxilla is essential. Nasal augmentation and lengthening of the columella with autogenous costal cartilage grafts must be done for effective treatment. Grafts must be carved from a central segment and dipped in 0.9% of NaCl solution to prevent warping and to reduce rate of resorption. Cartilage grafts with slots helps in better fixation of the grafts.

Augmentation is enough to give an aesthetically appealing and acceptable facial profile in mild to moderate cases (10).

REFERENCES

1. Demas PN, Braun TW. Simultaneous reconstruction of maxillary and nasal deformity in a patient with Binder's syndrome (Maxillonasal dysplasia). *J Oral Maxillofac Surg* 1992;50(1):83-6.
2. McCollum AG, Wolford LM. Binder syndrome: Literature review and long-term follow-up on two cases. *Int J Adult Orthod Orthognath Surg* 1998;13(1):45-58.
3. Holmstrom H, Kahnberg KE. Surgical approach in severe cases of maxillonasal dysplasia (Binder's syndrome). *Swed Dent J* 1988;12(1-2):3-10.
4. Noyes FB. Case report. *Angle Orthod* 1939;9:160-5.
5. Binder KH. Dysostosis maxillo-nasalis, ein archinencephaler Missbildungskomplex. *Deutsche Zahnarztliche Zeitschrift* 1962;17:438-44.
6. Nedev PK. The Binder syndrome: review of the literature and case report. *Int J Pediatr Otorhinolaryngol* 2008;72(10):1573-6.
7. Quarrell OW, Koch M, Hughes HE. Maxillonasal dysplasia (Binder's Syndrome). *J Med Genet* 1990;27(6):384-7.
8. Olow-Nordenram M, Valentin J. An etiologic study of maxillonasal dysplasia--Binder's syndrome. *Scand J Dent Res* 1988;96(1):69-74.
9. Cook K, Prefumo F, Presti F, Homfray T, Campbell S. The prenatal diagnosis of Binder syndrome before 24 weeks of gestation: a case report. *Ultrasound Obstet Gynecol* 2000;16(6):578-81.
10. Bhatt YC, Vyas KA, Tandale MS, Panse NS, Bakshi HS, Srivastava RK. Maxillonasal dysplasia (Binder's syndrome) and its treatment with costal cartilage graft: A follow-up study. *Indian J Plast Surg* 2008;41(2):151-9.