

Clinical results of anterior cruciate ligament reconstruction with bone-patellar tendon-bone autograft: A prospective study

Okan Aslanturk¹, Emre Ergen², Ozgur Yilmaz³, Ayse Cemile Gormeli⁴, Gokay Gormeli⁵

¹Malatya Educational Research Hospital Department of Orthopedic and Trauma Surgery, Malatya, Turkey

²Inonu University Faculty of Medicine, Department of Orthopedic and Trauma Surgery, Malatya, Turkey

³Mus State Hospital Orthopedic and Trauma Surgery, Malatya, Turkey

⁴Inonu University Faculty of Medicine, Department of Radiology, Malatya, Turkey

⁵Istinye University, Liv Hospital, Orthopedic and Trauma Surgery, Istanbul Turkey

Copyright © 2018 by authors and Annals of Medical Research Publishing Inc.

Abstract

Aim: Anterior cruciate ligament(ACL) injury is the most common ligament injury of knee. Gold standard treatment of ACL rupture is reconstruction of ligament with autograft or allograft. There is still controversy in graft choice in literature. In this study, we aimed to present prospective follow-up results of patients who were reconstructed with bone-patellar tendon-bone autograft for ACL rupture.

Material and Methods: Twenty-seven patients were operated for ACL rupture with bone-patellar tendon-bone(B-PT-B) autograft ACL reconstruction. Patients were followed for at least 2 years. Patients were evaluated preoperatively and postoperatively with Lysholm knee function score, IKDC objective score and Tegner activity level scale. Development of arthritis were evaluated radiologically.

Results: All of operated patients were male. The mean age of the patients was 25.4 (range 19-35 years). The mean follow-up time was 27.9 (range 24-30 months). There was a statistically significant increase in all postoperative knee scores. Hematoma, requiring surgical drainage, developed in two patients. Six patients had anterior knee pain while kneeling at final follow up.

Conclusion: ACL rupture causes knee instability that can lead early knee arthritis and meniscal injuries. Patients with ACL rupture showed increased knee stability and functional scores after reconstruction. Anterior cruciate ligament reconstruction with B-PT-B autograft incorporates and heals faster with low rerupture and complication rate.

Keywords: Anterior Cruciate Ligament Rupture; Knee Arthroscopy; Sport Injury.

INTRODUCTION

The prevalence of anterior cruciate ligament (ACL) rupture has been increasing due to the increase in participation in sports activities (1). ACL reconstruction is gold standard treatment due to ACL rupture causes knee instability and limitations in daily activities if not treated (2).

Different graft (bone-patellar tendon-bone, semitendinosus, autograft or allograft etc.) and fixation (endobutton, interference screw etc.) techniques have been reported with good results in literature (2-5). Superiority of any graft or fixation technique is still in controversy (4-5). In all surgical techniques, the main goal of reconstruction is to provide stability for good function and to protect the knee from meniscus tears, developing cartilage damage and osteoarthritis in long term. In this prospective study, we aimed to present short term results of ACL reconstruction with bone-patellar tendon-bone (B-PT-B) and interference screw patients with ACL rupture with an instable knee joint.

MATERIAL and METHODS

After Inonu University Ethics Committee approval had been taken, 27 consecutive ACL reconstruction using B-PT-B autograft were performed at Turgut Ozal Medical Center of Inonu University, Faculty of Medicine. All patients had been informed and given written informed consent before surgery. Patients with at least 24 months follow-ups and age between 18 and 35 were included to study.

Lysholm knee, IKDC subjective knee evaluation form and Tegner knee activity scores were measured before surgery and at last follow up. Radiography was obtained after surgery to assess degenerative changes of knee joint.

Surgical Technique

All surgeries performed by the same surgeon (G.G.) under spinal anesthesia. After standard arthroscopic examination of knee, remnant of ruptured ACL was removed by using

Received: 28.01.2018 Accepted: 11.03.2018 Available online: 16.03.2018

Corresponding Author: Okan Aslanturk, Malatya Educational Research Hospital Department of Orthopedic and Trauma Surgery, Malatya, Turkey
E-mail: okaslanturk@hotmail.com

arthroscopic shaver. Partial meniscectomy or meniscus repair, if possible, performed patients with concomitant meniscus injury. Then, 8 cm longitudinal incision was made over patellar tendon between lower pole of patella and tuberositas tibia (Figure 1).

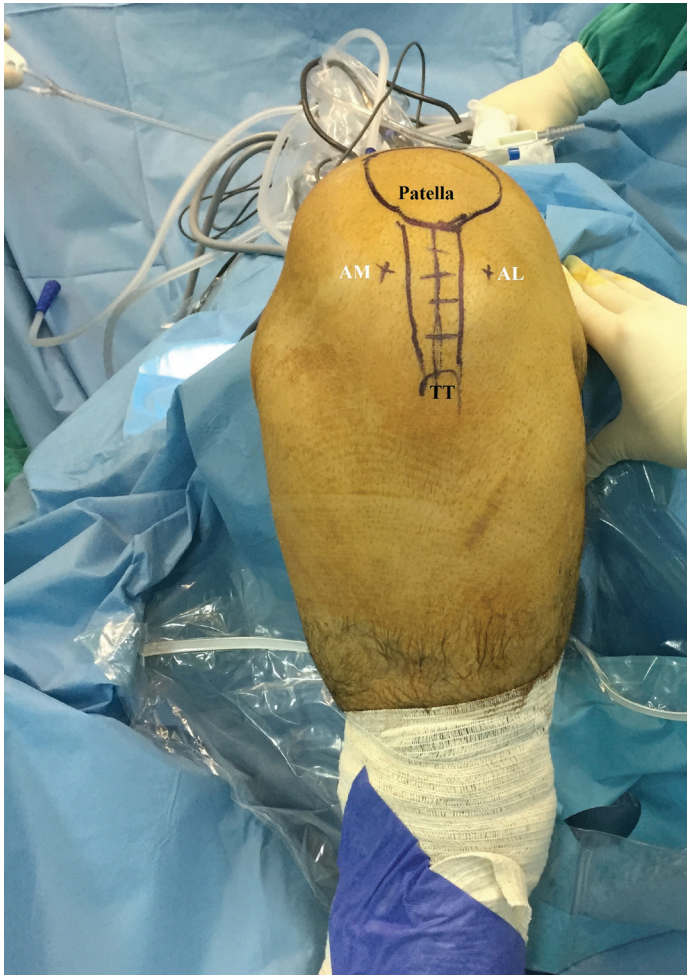


Figure 1. Marking the landmarks. AM: anteromedial portal, AL: anterolateral, TT: tuberositas tibia

A 10 mm width tendon strip was harvested from mid- 1/3 of patellar tendon with 2x1x1 cm bone blocks both from tuberositas tibia and patella (Figure 2).

Two drill holes were made on bone blocks using 2.0 mm drills on back table. 2.0 ethibond sutures were passed through drill holes. Meanwhile, a femoral tunnel was made on lateral femoral condyle in direction of 11 o'clock at right side or 1 o'clock at left side. Passing suture was placed to femoral tunnel over guiding wire (Figure 3).

A tibial tunnel was made with tibial guide set at 550. Then, the passing suture was passed from tibial tunnel with a suture grasper or a prop.

BTB graft had been loaded to passing suture (Figure 4) and was placed in tibial and femoral tunnels and secured with titanium or bioabsorbable interference screw in both tunnels under proper tension of graft.

Paratenon of patella tendon repaired with interrupted sutures. A hemovac drain was placed into knee and removed 24 hour after surgery.

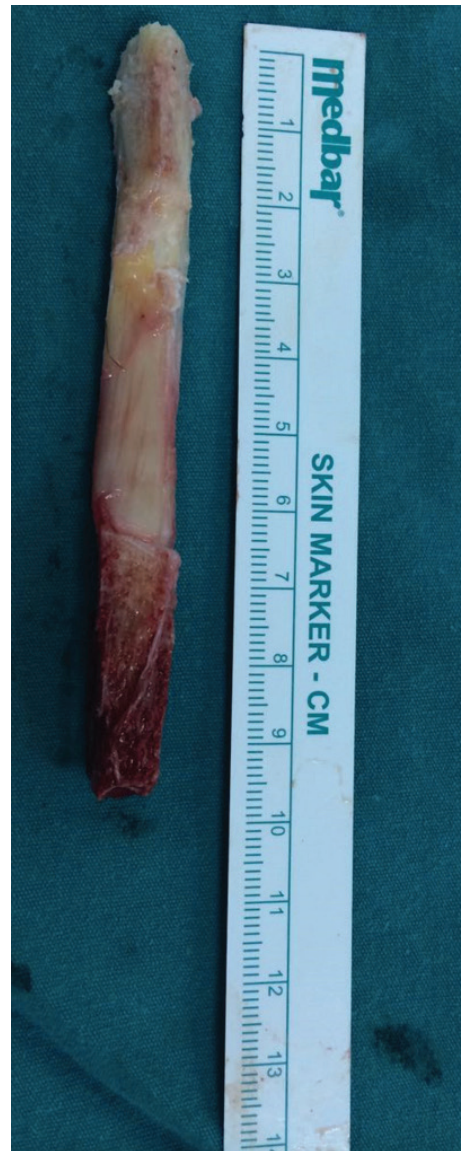

Figure 2. Harvested BTB autograft

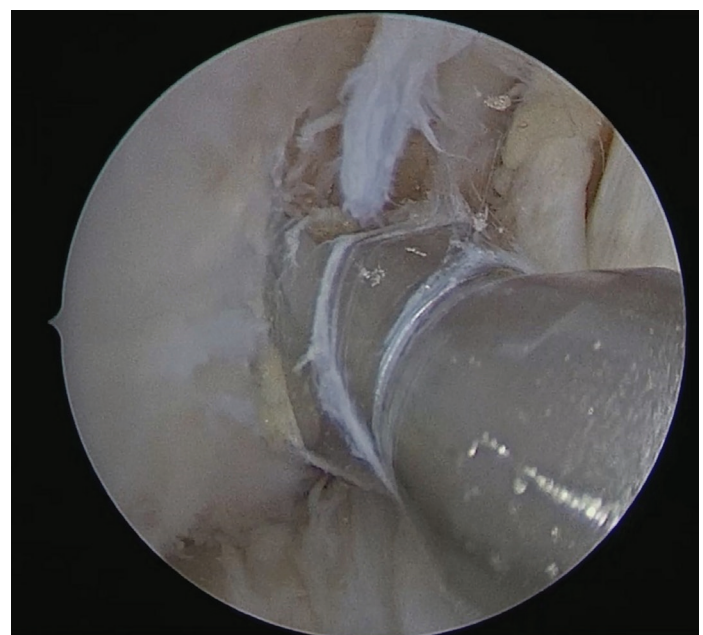


Figure 3. Preparation of femoral tunnel

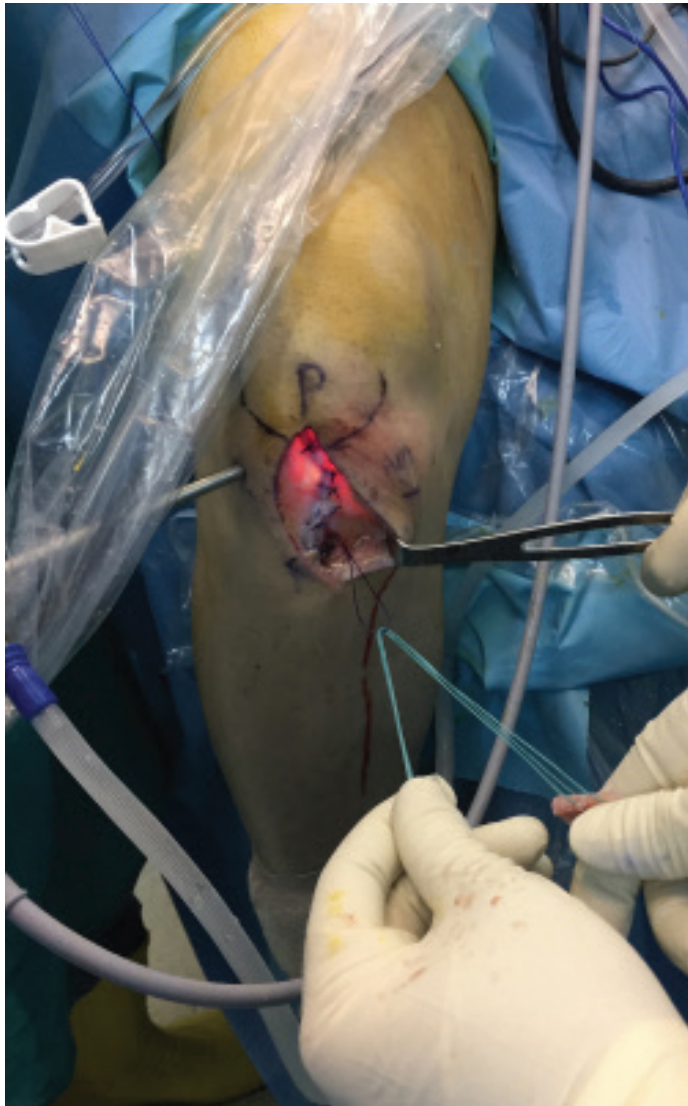


Figure 4. Loading graft to passing suture

Rehabilitation

All patients placed into a knee brace for 4 weeks. Closed-chain exercises were started the day after surgery. All patients underwent same rehabilitation protocol. Full weight bearing was allowed immediately. One hundred and twenty degrees of knee flexion was aimed in 6 weeks. Running was allowed at 3 months post-operatively and contact sports were allowed at 6 months after surgery.

Statistical Analysis

Power analysis was used to determine number of cases with PASS 11. Statistical analysis was performed with SPSS 22.0 (IBM SPSS Statistics for Windows, Version 22.0. Armonk, NY: IBM Corp.) with preoperative and 2 years postoperative data. Normal distribution of data was tested with Kolmogorov-Smirnov test. Paired-samples t test were used for comparison of data's. A $p < 0,05$ was accepted as statistically significant with a confidence interval of 95%.

RESULTS

Twenty three of 27 patients with at least 24 months follow up were included to study. Four patients lost follow-up. Mean follow up time was 27.9 months (range, 24-30

months). All patients were male. In 12 patient's right knee and in 11 patients left knee were affected. Mean age of patients was 25,4 years (range, 19-35).

Mechanism of injury was due to contact sport in 17 patients, traffic accident in 2 patients, skiing in 1 patient, falling from high in 1 patient and direct trauma to knee in 1 patient. Time from initial trauma to surgery was 14,9 months (ranging 1-48 months).

Six patients had concomitant meniscal injury; 4 were medial meniscus and 2 were lateral meniscus tear. Three of them treated with repair with all inside technique and other 3 were treated with partial meniscectomy during the ACL reconstruction.

Lysholm knee , IKDC subjective knee evaluation form and Tegner knee activity scores improved statistically significantly after surgery compared with preoperative values. All patients returned their pre-injury activity levels (Table 1).

Table 1. Preoperative and post-operative knee scores

	Preoperative (\pm SD)	Postoperative (\pm SD)	p
Lysholm	50,35(\pm 19,413)	89,96(\pm 13,546)	$p < 0,001$
IKDC-S	41,67(\pm 17,798)	84,22(\pm 16,909)	$p < 0,001$
Tegner	2,65(\pm 2,328)	5,35(\pm 1,555)	$p < 0,001$

SD: Standard Deviation

Hematoma on anterior knee was detected as early complication in 2 patients and treated with drainage. Six patients had anterior knee pain while kneeling at last follow-up.

DISCUSSION

ACL injury is the most common knee ligament injury (6). ACL provides stability with resisting anterior-posterior translation and rotational subluxation (7). ACL rupture causes knee instability that can lead early knee arthritis and meniscal injuries (8). The gold standard treatment of ACL rupture is ACL reconstruction. In this prospective study, we evaluated clinical results of ACL reconstruction with BTB autograft in short term. Limitations of our study were small number of subjects, short follow-up time, and having no comparison group.

Graft choice in ACL reconstruction is still controversial (4,5,9,10,11). Each type of graft has advantages and disadvantages. Advantages of autografts have been reported as faster graft incorporation, initial strength, cost affectivity (12). Donor site morbidity and longer surgery time are disadvantages of autografts (12). Allografts have advantages like shorter surgery time and no donor site morbidity, hence longer incorporation time, risk of disease transmission and higher rate of early graft failure are disadvantages (11,12).

In a meta-analysis, Krauther et al. reported statistically significantly lower Lysholm knee scores and higher failure rates in allograft group (13). In another study; higher early failure has been reported in allograft group, though no

rerupture was seen in autograft group in 8,6 years follow up (14). In our series, we also have no rerupture in final follow-up.

Rodriguez et al. reported rerupture rate 8,2% with BTB autograft in 15 years follow-up (15). They also reported 98% patient satisfaction and 90% of patients returned to pre-injury activity levels. Arthritic changes reported in 25% of patients (15). In our study, all patients returned to pre-injury activity levels. We haven't seen any arthritic changes in final follow-up but this was probably due to our short term follow-up. In another study, echogenicity of donor side of patellar tendon at ultrasound examination was similar to nonoperated side in %70 of patients at 6 months post-operatively and in all patients at 12 months postoperatively (16).

CONCLUSION

In conclusion, BTB autograft for ACL reconstruction is a good option with low rates of failure and complication. ACL is important for knee stability especially in young active individuals. It should be remembered arthritic changes can be seen in long term after ACL injury even knee is stable.

Competing interests: The authors declare that they have no competing interest.

Financial Disclosure: There are no financial supports

Ethical approval: This work has been approved by the Institutional Review Board

REFERENCES

1. Janssen KW, Orchard JW, Driscoll TR, Van Mechelen W. High incidence and costs for anterior cruciate ligament reconstructions performed in Australia from 2003-2004 to 2007-2008: time for an anterior cruciate ligament register by Scandinavian model?. *Scand J Med Sci Sports* 2012;22(4):495-501.
2. Mariscalco MW, Magnussen RA, Mehta D, Hewett TE, Flanigan DC, Kaeding CC. Autograft versus nonirradiated allograft tissue for anterior cruciate ligament reconstruction: A systematic review. *Am J Sports Med* 2014;42(2):492-9
3. Hospodar SJ, Miller MD. Controversies in ACL reconstruction: bone-patellar tendon-bone anterior cruciate ligament reconstruction remains the gold standard. *Sports Med Arthrosc Rev* 2009;17(4):242-6.
4. Dheerendra SK, Khan WS, Singhal R, Shivarathre DG, Pydisetty R, Johnstone D. Anterior cruciate ligament graft choices: a review of current concepts. *Open Orthop J* 2012;6:281-6.
5. Lord B, Grice J, Cox G, Yassen S, Wilson A. Anterior cruciate ligament reconstruction-evolution and current concepts. *Orthopaedics and Trauma* 2014;29(1):12-23
6. Mall NA, Chalmers PN, Moric M, Tanaka MJ, Cole BJ, Bach BR, et al. Incidence and trends of anterior cruciate ligament reconstruction in the United States. *Am J Sports Med* 2014;42(10):2363-70.
7. Shaerf DA, Pastides PS, Sarraf KM, Willis-Owen CA. Anterior cruciate ligament reconstruction best practice: A review of graft choice. *World J Orthop* 2014;5(1):23-9.
8. Granan LP, Bahr R, Lie SA, Engebretsen L. Timing of anterior cruciate ligament reconstructive surgery and risk of cartilage lesions and meniscal tears: a cohort study based on the Norwegian National Knee Ligament Registry. *Am J Sports Med* 2009;37(5):955-61.
9. Almqvist KF, Willaert P, De Brabandere S, Criel K, Verdonk R. A long-term study of anterior cruciate ligament allograft reconstruction. *Knee Surg Sports Traumatol Arthrosc* 2009;17(7):818-22.
10. Mehran N, Skendzel JG, Lesniak BP, Bedi A. Contemporary Graft Options in Anterior Cruciate Ligament Reconstruction. *Operative Techniques in Sports Medicine* 2013;21(1):10-8.
11. Sun K, Tian SQ, Zhang, JH, Xia CS, Zhang CL, Yu TB. Anterior cruciate ligament reconstruction with bone-patellar tendon-bone autograft versus allograft. *Arthroscopy* 2009;25(7):750-9.
12. McDermott ID. Graft options for ACL reconstructive surgery. *Orthopaedics and Trauma* 2013;27(3):156-63.
13. Kraeutler MJ, Bravman JT, McCarty EC. Bone-patellar tendon-bone autograft versus allograft in outcomes of anterior cruciate ligament reconstruction: A meta-analysis of 5182 patients. *Am J Sports Med* 2013;41(10):2439-48.
14. Steadman JR, Matheny LM, Hurst JM, Briggs KK. Patient-centered outcomes and revision rate in patients undergoing acl reconstruction using bone-patellar tendon-bone autograft compared with bone-patellar tendon-bone allograft: a matched case-control study. *Arthroscopy* 2015;31(12):2320-6.
15. Rodríguez-Merchán EC, Durán D, Revilla C, Gómez-Cardero P, Martínez-Lloreda A, Bello S. Arthroscopic BPTB graft reconstruction in ACL ruptures: 15-year results and survival. *Knee* 2014;21(5):902-5.
16. Yazdanshenas H, Madadi F, Madadi F, Washington ER 3rd, Jones K, Shamie AN. Patellar tendon donor-site healing during six and twelve months after Anterior Cruciate Ligament Reconstruction. *J Orthop* 2015;12(4):179-83.