

# Amyand hernia

Huseyin Kocaaslan<sup>1</sup>, Dincer Ozgor<sup>1</sup>, Suleyman Koc<sup>2</sup>, Mustafa Ates<sup>1</sup>, Abuzer Dirican<sup>1</sup>

<sup>1</sup>Inonu University Faculty of Medicine, Department of General Surgery, Malatya, Turkey

<sup>2</sup>Antalya Education Research Hospital, General Surgery Clinic, Antalya, Turkey

Copyright © 2018 by authors and Annals of Medical Research Publishing Inc.

## Dear Editor,

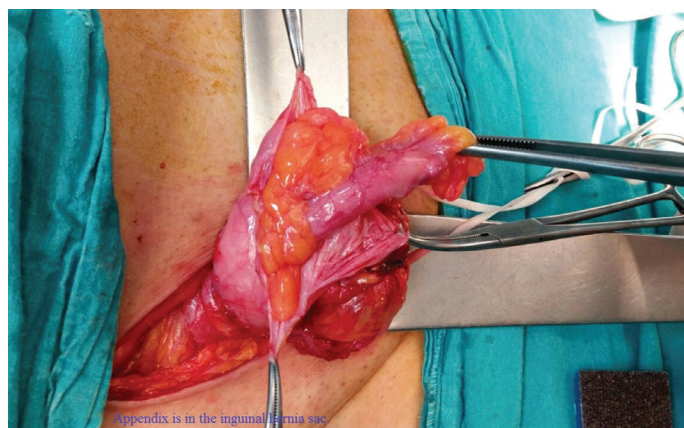
The presence of a vermiform appendix in an inguinal hernia sac, termed Amyand hernia, was first described by Claudius Amyand in 1735 (1). It constitutes less than 1% of inguinal hernias in adults, and the incidence of having an inflamed appendix in the inguinal hernia (0.1%) is even lower (2). It is usually located on the right side of the lower abdomen. However, few case reports of left-sided Amyand hernia have been reported describing association with situs inversus, intestinal malrotation, and mobile cecum (3).

As the diagnosis of inguinal hernia is usually based on a physical examination, pre-operative imaging is not routinely performed. So, Amyand hernia is often an incidental finding during inguinal hernia surgery (4,5). There are few case reports and little consensus on how surgeons should manage Amyand hernia. There exists an ongoing debate whether an appendectomy is required and also suture versus mesh repair should be preferred. (4-10).

A 55-year-old diabetic male presented with one month of history of bilateral groin pain and swelling. He has been taking antibiotics for 3 weeks for the left groin abscess. He had a history of left inguinal hernia repair with implantation of prosthetic mesh 6 years ago. On examination, his vital signs were stable. He had a reducible right inguinal bulge and a purulent discharge from his left groin, both of which were minimally tender to palpation.

Laboratory studies revealed leukocytosis (white blood cell count, 11.600/ $\mu$ L). The elective surgery was planned for both inguinal hernia on the right side and mesh-related infection on the left side. The infected mesh was removed completely through the previous incision and the fascia was reinforced with polypropylene sutures.

The wound was allowed to heal by secondary intention. The right inguinal groin was explored through an oblique incision. An inflamed and edematous vermiform appendix adhered to the hernia sac was seen (Figure 1).



**Figure 1.** The inflamed vermiform appendix within the inguinal hernia sac

Appendectomy and Bassini repair without prosthetic mesh were performed. Systemic antibiotics were also used. The patient was discharged on the second day and remained uneventful for a further 12 months of follow-up.

There is no consensus on the treatment approaches for Amyand hernia. In this case antibiotics taken for mesh infection may have masked the clinical signs of acute appendicitis. As the patient had diabetes mellitus and previous mesh-related infection appendectomy and hernia repair without prosthetic mesh were performed to avoid potential complications.

*Competing interests: The authors declare that they have no competing interest.*

## REFERENCES

1. Amyand C. Of an inguinal rupture, with a pin in the appendix caeci incrusted with stone, and some observations on wound in the guts. *Phil Trans R Soc Lond* 1736; 39: 329-42.
2. Smith-Singares E, Boachie JA, Iglesias IM. A rare case of appendicitis incarcerated in an inguinal hernia. *Journal of Surgical Case Reports* 2016;2016(6):rjv096.
3. Mewa Kinoo S, Aboobakar MR, Singh B. Amyand's Hernia: A Serendipitous Diagnosis. *Case Reports in Surgery* 2013;2013:125095.

**Received:** 03.12.2017 **Accepted:** 15.02.2018 **Available online:** 02.03.2018

**Corresponding Author:** Huseyin Kocaaslan, Inonu University Faculty of Medicine, Department of General Surgery, Malatya, Turkey  
E-mail: huseyinkocaaslan@hotmail.com

4. Kwok CM, Su CH, Kwang WK, Chiu YC. Amyand's Hernia -Case Report and Review of the Literature. *Case Rep Gastroenterol* 2007;1(1):65-70.
5. Hutchinson R. Amyand's hernia. *JR Soc Med* 1993;86(2):104-5.
6. Sahu D, Swain S, Wani M, Reddy PK. Amyand's hernia: Our experience in the laparoscopic era. *J Minim Access Surgery* 2015;11(2):151-3.
7. Velimezis G, Vassos N, Kapogiannatos G, Koronakis D, Perrakis E, Perrakis A. Incarcerated recurrent inguinal hernia containing an acute appendicitis (Amyand hernia): an extremely rare surgical situation. *Arch Med Sci* 2017;13(3): 702-4.
8. Sharma H, Gupta A, Shekhawat NS, Memon B, Memon MA. Amyand's hernia: A report of 18 consecutive patients over a 15-year period. *Hernia* 2007;11(1):31-5.
9. Salemis NS, Nisotakis K, Nazos K, Stavrinou P, Tsohataridis E. Perforated appendix and periappendicular abscess within an inguinal hernia. *Hernia* 2006;10(6):528-30.
10. Ofili OP. Simultaneous appendectomy and inguinal herniorrhaphy could be beneficial. *Ethiop Med J* 1991;29(1):37-8.