

# Evaluation of the relationship between concha bullosa and nasal septum deviation with diameter of nasolacrimal duct

Mehmet Sirik, Ibrahim Inan

Adiyaman University Faculty of Medicine, Department of Radiology, Adiyaman, Turkey  
Biruni University Hospital Department of Radiology, Istanbul, Turkey

Copyright © 2019 by authors and Annals of Medical Research Publishing Inc.

## Abstract

**Aim:** The aim of this study was to evaluate the effect of concha bullosa (CB) and nasal septal deviation (NSD) on the diameter nasolacrimal duct (NLD).

**Material and Methods:** A total of 103 patients who underwent paranasal sinus (PNS) computed tomography (CT) between January 2018 and May 2018 were included in the study. Coronal and axial CT images of the patients were evaluated for the presence of CB and NSD. Left and right NLD diameters were measured from axial CT plane. To ensure standardization, the NLD diameters measurement was performed from the CT sections at the level of the inferior border of bilateral bulboculi in all patients. The relationship between the CB, NSD and NLD was statistically analyzed.

**Results:** Of the 103 patients included in the study, 51 (49.5%) were males and 52 (50.5%) were females. The minimum age of the patients was 18 years, the maximum age was 79 years and the median age was 38 years. Forty patients (38.8%) had CB and 63 patients (61.2%) had no CB. Nasal septum was in the midline in 39 patients (37.9%) and NSD was present in 64 patients (62.1%). The median NLD diameter was 5.8 mm on the right and left side. NLD diameter was significantly smaller in females than males ( $p < 0.05$ ). There was no statistically significant relationship between CB, NSD and the NLD diameter.

**Conclusion:** In our study, there was no significant effect of the presence of concha bullosa and nasal septum deviation on the nasolacrimal duct diameter

**Keywords:** Nasolacrimal Duct; Concha Bullosa; Nasal Septum.

## INTRODUCTION

In the evaluation of periorbital and paranasal area pathologies, CT imaging has been frequently used in recent years because of its easy accessibility, detailed imaging of periorbital anatomy and short screening time. The tear drainage system starts from the punctum and continues with lacrimal canaliculus to tear sac and ends with the nasolacrimal canal at the meatus nasi inferior (1). There are many studies describing the relationship between the detailed anatomy and variations of the nasolacrimal drainage system and nasolacrimal flow problems using CT imaging (2). Most of these studies focused on parameters such as NLD diameter, NLD area and volume, or the angle between the NLD and the nasal base. In our study, we aimed to evaluate the effects of concha bullosa and nasal septum deviation on NLD diameter and the relationship with drainage system pathologies.

## MATERIAL and METHODS

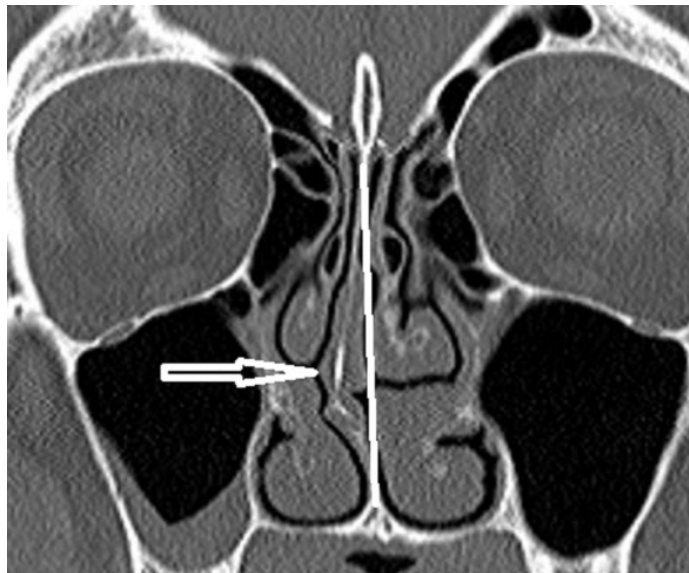
Our study was approved by the local ethics committee (2018/4-25). A total of 103 patients who underwent paranasal sinus computed tomography between January 2018 and May 2018 due to any clinical complaint were included in the study. Patients who had trauma, operated for these areas, with known NLD pathology and who were not suitable for CT images measurements due to artifact and/or position were excluded from the study. The paranasal sinus CT scan was performed using a 64-sectional CT (Aquilion, Toshiba, Japan) using bone window, using 120 kV / 80mAs values, axial, coronal and sagittal plane reformed images of 3 mm thickness. CT evaluation and measurements were performed by a single experienced radiologist. To ensure standardization, the NLD diameters measurement was performed from the CT sections at the level of the inferior border of bilateral bulboculi in all patients (Figure 1). Patients with

Received: 23.10.2018 Accepted: 21.11.2018 Available online: 26.11.2018

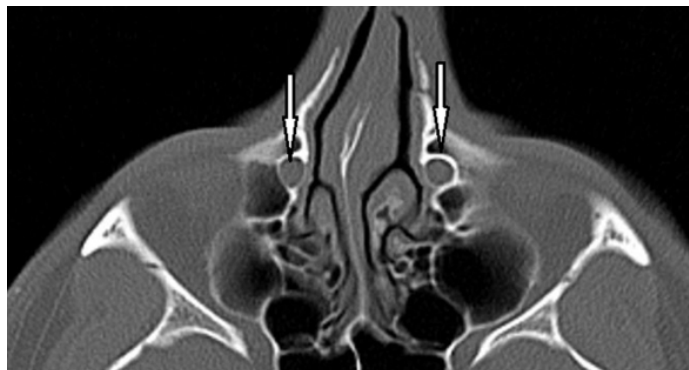Corresponding Author: Mehmet Sirik, Adiyaman University Faculty of Medicine, Department of Radiology, Adiyaman, Turkey

E-mail: dr.mmtsrk@gmail.com

middle turbinate pneumatization were defined as CB. For the diagnosis of NSD the line drawn from crista galli to maxillary crest was taken as reference. It was defined as a deviation or a right-sided or left-sided deviation (Figure 2).



**Figure 1.** The coronal plane PNS CT image shows the deviation of the nasal septum to the right



**Figure 2.** Bilateral NLD at the level of the orbital base in the axial plane PNS CT image

The patients with right-sided and left-sided NSD were included in different groups to analyze the relationship between the side of NSD and other parameters. SPSS 21.0 software (IBM Corp. New York, USA) was used for statistical analysis. Categorical data are expressed as

number and percentage, and non-parametric numerical data by median, minimum and maximum. Pearson's Chi-Square and Fisher's exact test were used for the comparison of categorical data and Mann-Whitney U and Kruskal-Wallis test was used to compare the numerical data between groups. p value was statistically significant under 0.05.

**RESULTS**

A total of 103 patients were included in the study, of which 51 (49.5%) were males and 52 (50.5%) were females. The minimum age was 18 years, the maximum age was 79 years and the median age was 38 years. The NLD diameter was the same in the right and left sides in 5 (4.9%) patients. NLD diameter was wide on the right side in 52 (50.5%) patients, and it was wide on the left side in 46 (44.7%) patients. NLD diameters were measured, on the right side minimum 3.3 mm, maximum 10.2 and median 5.8 mm; on the left side; minimum 3.5 mm, maximum 11.6 mm, and median 5.8 mm. NLD diameters were significantly smaller in females than males ( $p < 0.05$ ). While CB was not present in 63 (61.2%) patients, it was present in 40 (38.8%) patients (11 in the right, 9 in the left and 20 in the bilateral). There was no statistically significant relationship between NLD diameters in patients with and without CB when compared to the presence of CB and the diameters of NLD ( $p = 0.632$  for right and  $p = 0.319$  for left NLD), (Table 1-2).

NSD was not present in 39 (37.9%) patients, 33 (34%) patients had right and 29 (28.2%) patients had left deviation. There was no statistically significant relationship between NLD diameters in patients with and without deviation ( $p = 0.699$  for right and  $p = 0.6$  for left NLD), (Table 3-4).

		concha bullosa			
		absent	Right	Left	bilateral
<b>Nasolacrimal duct width</b>	Symmetrical	2	1	0	2
	Right wider	35	5	5	7
	Left wider	26	5	4	11
<b>Total</b>	63	11	9	20	
<b>p=0.634</b>					

	Absent	Concha bullosa median value. (min-max)			p
		Right	Left	Bilateral	
<b>Right nasolacrimal canal width (mm)</b>	5.8 (3.3-10.2)	6.0 (4.5-7.7)	5.1 (4.0-8.2)	6.1 (4.5-7.7)	0.632
<b>Left nasolacrimal canal width (mm)</b>	5.5 (3.5-11.6)	5.7 (4.5-7.7)	5.5 (3.6-7.6)	6.3 (4.8-8.0)	0.319

**Table 3. Comparison of nasal septum deviation and nasolacrimal duct width**

		Septum deviation		
		Absent	Right	Left
Nasolacrimal canal width	Symmetrical	3	2	0
	Right wider	23	15	14
	Left wider	13	18	15
<b>Total</b>		<b>39</b>	<b>35</b>	<b>29</b>
<b>p=0.298</b>				

**Table 4. Comparison of numerical parameters of nasal septum deviation with nasolacrimal duct widths**

	Septum deviation			p
	Absent	Right	Left	
Right nasolacrimal canal width (mm)	5.8 (4.0-10.2)	5.9 (4.5-7.7)	5.8 (3.3-9.8)	0.699
Left nasolacrimal canal width (mm)	5.8 (3.6-11.6)	5.8 (3.8-8.0)	5.7 (3.5-8.1)	0.6

## DISCUSSION

NSD and CB are the most common variations of the nasal region (3). The most common anatomic variation of the nose is NSD (57.6%) and the second most common is the CB (33.8%) (4). Nasal septum is an important structure in the inner part of the nasal that has physiological, supportive and airway regulatory role (3,5). NSD is defined as the asymmetric curvature of the septum to any side (6). Childhood nasal trauma, irregular growth of maxillary bone, asymmetry of the maxillary sinuses and nasal concha, genetic and environmental factors are among the possible risk factors for NSD (7). The prevalence of NSD in the population varies from 18.8% to 75.1% in different sources (3,5). In our study, 62.1% of patients had NSD in accordance with the literature. Another common anatomic variation in the nasal area is concha bullosa which may develop in any of the three conchae, but this term is often used for the pneumatization of the middle nasal turbinate (3-5,8). CB is the most common variation of the osteomeatal complex region (9). Although the causes of concha pneumatization are not known, developmental causes, trauma, abnormalities in the growth of paranasal bone structures, adenoid hypertrophy and NSD are possible factors (10). The incidence of concha bullosa was defined in a wide range between 13.2% and 72.2% in different sources (6,8). In our study, in accordance with the literature, 38.8% of the patients had CB. The increase in the concha size due to the presence of concha bullosa may cause nasal physiology to deteriorate by narrowing the nasal cavity. In addition to obstruction of the nasal air passage, infection due to impaired mucus drainage and ciliary functions in nasal cavity and paranasal sinuses may occur (11).

Pathological conditions such as mucosal and soft tissue inflammation, abscess development and tumor infiltration in NLD may occur due to trauma-related injuries of

the nasolacrimal drainage system. These pathological processes usually result in stenosis or obstruction in NLD. Various procedures such as endoscopy, balloon dilatation, stent and laser applications are frequently applied in such cases (12). It is important to know the diameter and length of NLD for the selection of the appropriate treatment procedure and successful treatment of NLD pathologies. CT imaging is commonly used to study the general anatomy of the nasolacrimal drainage system and thin-section axial CT is an effective imaging method for assessing the nasolacrimal drainage system and surrounding tissue structures (12,13).

Although there have been some studies evaluating the relationship between NSD, CB and their relationship with other pathologies of the paranasal region, we have not found any research on the possible effects of NSD and CB on NLD diameter in the literature.

Stallman et al. found a strong association between CB and contralateral NSD, but did not find a statistically significant association between NSD and CB and any paranasal sinus disease (8).

In another study that investigating the relationship between CB and NSD and maxillary sinusitis, no statistically significant relationship was found between the parameters (6).

Paksoy et al. in their that study investigating the effects of CB on nasal pathologies, did not find a significant difference between the symptoms and distribution of nasal pathologies in patients according to CB size (4).

Keles et al. supported the existence of a significant relationship between NSD and contralateral CB in their study (5).

Janssen et al. Reported that small NLD diameter and primary acquired nasolacrimal duct obstruction were etiologically related (14). In the same study, NLD diameter did not differ significantly between males and females but in another study (15), NLD diameter was found to be smaller in females. In our study, NLD diameter was significantly smaller in women.

Among our limitations the low number of cases, as well as the control-comparative prospective studies in which cases with nasolacrimal canal pathology are evaluated, can make a more meaningful contribution.

## CONCLUSION

In conclusion, there was no statistically significant relationship between the presence of concha bullosa and nasal septum deviation and nasolacrimal duct diameter. We believe that these variations are not an important factor related to the pathologies of nasolacrimal drainage system.

*Acknowledgements: We are grateful to Associate Prof. I. Hakan Bucak for support with the statistical analysis.*

*Competing interests: The authors declare that they have no competing interest.*

*Financial Disclosure: There are no financial supports*

*Ethical approval: Ethical approval: Our study was approved by the local ethics committee(2018/4-25).*

*Mehmet Sirik ORCID: 0000-0002-5543-3634*

*Ibrahim Inan ORCID: 0000-0003-2136-3604*

## REFERENCES

1. Nuhođlu F, Özdemir FE, Buyrukcu AT, ve ark. Epiforası olan olgularda lakrimal sintigrafi ve dakriyosistografinin yeri; JAREM 2012;2:68-70.
2. Craig N Czyz, Thomas S Bacon, Andrew W Stacey, et al. Nasolacrimal system aeration on computed tomographic imaging: effects of patient positioning and scan orientation. Clin Ophthalmol 2015;9:469-73
3. Karazincir S, Okuyucu S, Balcı A, ve ark. Konka bülloza septal deviasyon ilişkisi. KBB-Forum 2007;6:19-21.
4. Paksoy M, Şanlı A, Evren C, ve ark. Konka bullozanın nazal patolojilerdeki rolü. Kulak Burun Bogaz Ihtis Derg 2008;8: 238-41.
5. Keles B, Öztürk K, Ünaldi D, et al. Is there any relationship between nasal septal deviation and concha bullosa. Eur J Gen Med 2010;7:359-64.
6. Smith KD, Edwards PC, Saini TS, et al. The prevalence of concha bullosa and nasal septal deviation and their relationship to maxillary sinusitis by volumetric tomography. Int J Dent 2010;2010:404982.
7. Blaugrund SM. The nasal septum and concha bullosa. Otolaryngol Clin North Am 1989;22:291-6.
8. Stallman JS, Lobo JN, Som PM, The incidence of concha bullosa and its relationship to nasal septal deviation and paranasal sinus disease. AJNR Am J Neuroradiol. 2004;25;1613-8.
9. Tonai A, Baba S. Anatomic variations of the bone in sinonasal CT, Acta Otolaryngol Suppl 1996;525:9-13.
10. Aktas D, Kalciođlu MT, Kutlu R, et al. The relationship between the concha bullosa, nasal septal deviation and sinusitis. Rhinology 2003;41:103-6.
11. San Turhan, Erdođan B, Taşel B. Konka bülloza tipleri ile sinonazal patolojiler arasındaki ilişki. Göztepe Tıp Derg 2013;28:132-5.
12. Groell R, Schaffler GJ, Uggowitzer M, et al. CT-anatomy of the nasolacrimal sac and duct. Surg Radiol Anat 1997;19:189-91.
13. Lefebvre DR, Freitag SK. Update on imaging of the lacrimal drainage system. In: Seminars in ophthalmology. Taylor Francis 2012. p. 175-86.
14. Janssen AG, Mansour K, Bos JJ, et al. Diameter of the bony lacrimal canal: normal values and values related to nasolacrimal duct obstruction: assessment with CT. AJNR Am J neuroradiol 2001;22:845-50.
15. Shigeta KI, Takegoshi H, Kikuchi S. Sex and age differences in the bony nasolacrimal canal: an anatomical study. Arch Ophthalmol 2007;125:1677-81.