

# Management of corneal pannus caused by late stage complication of honey bee sting

Tongabay Cumurcu

Inonu University Faculty of Medicine Department of, Ophthalmology, Malatya, Turkey

Copyright © 2019 by authors and Annals of Medical Research Publishing Inc.

## Dear Editor,

Bee stings of the cornea are rarely reported, but have the potential for causing serious ophthalmologic injuries. The effects of bee sting corneal injury is often a challenging one to tackle, causing decreasing effects to vision despite sufficient medical and surgical treatment. Ocular bee sting injuries involving the cornea commonly present with corneal edema, infiltrates, striate keratopathy, and bullous keratitis, anterior uveitis, hyphemia, iris atrophy, cataract, optic neuritis, and ophthalmoplegia (1).

We present a case of corneal bee sting associated corneal pannus and discuss the pathologic mechanisms of injury, evaluation, and treatment of this uncommon presentation.

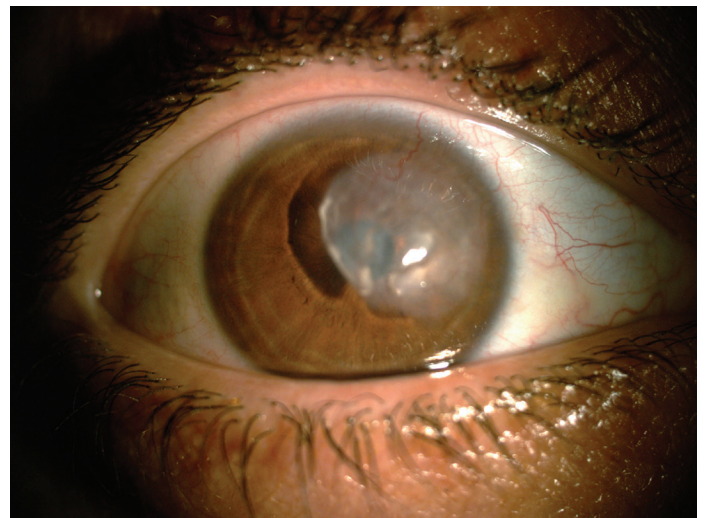
A 34-year-old male presented with low vision in right eye for 1 year after he sustained bee sting injury. The patient uses a few drops after the event but his eyesight declined steadily. In addition, he had realized increasing an opacity in his right eye in this process. The patient was referred from state hospital for keratoplasty.

During the examination, right eye best corrected visual acuity (BCVA) was counting fingers at 2 meters. Slit lamp examination revealed diffuse, large superficial stromal pannus was seen at 12-4 o'clock quadrant. The pupil area was also closed by the pannus (Figure 1).

There was no anterior chamber inflammation and iris atrophy. There was also no cataract. The posterior segment could not be visualized due to corneal pannus. Therefore, a B-scan ultrasound of the globe was normal. Intraocular pressure (IOP) was measured 12 mmHg by Goldman Applanation tonometer but it was unreliable, so it was measured by Schiottz tonometry and revealed similar results were obtained.

We have performed corneal lamellar keratectomy and then 0.2% mitomycin-C administrated during 5 minutes to this

area and 25 mg/mL limbal subconjunctival bevacizumab injection and amnion membrane transplantation was conducted on scarring area.



**Figure 1.** Corneal pannus due to bee sting.

At the first week follow-up, the corneal lesion had begun healed and amnion membrane had also begun to melt. BCVA had improved to 20/200 (Figure 2). At the 3<sup>th</sup> month follow-up, the corneal lesion had healed completely at the site of the pannus and BCVA had improved to 20/20 (Figure 3).

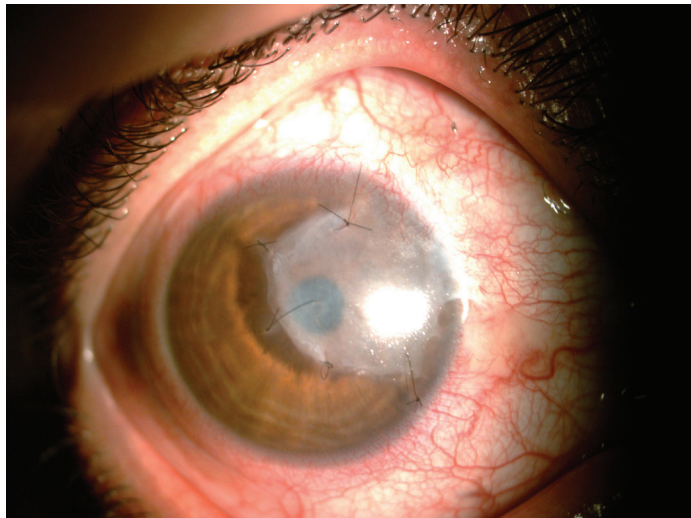
Although we have seen many cases of acute stage management of corneal bee sting in the literature, we did not find any demonstration of corneal pannus management with late complication. We know that the majority of ophthalmic complications following corneal bee sting are suggested to be caused as a result of immunologic or toxic reactions to chemical mediators of the injected venom (2). In our case, this pannus and corneal vascularization might be caused by an immunologic reaction to the venom

**Received:** 07.01.01.2019 **Accepted:** 16.01.2019 **Available online:** 25.01.2019

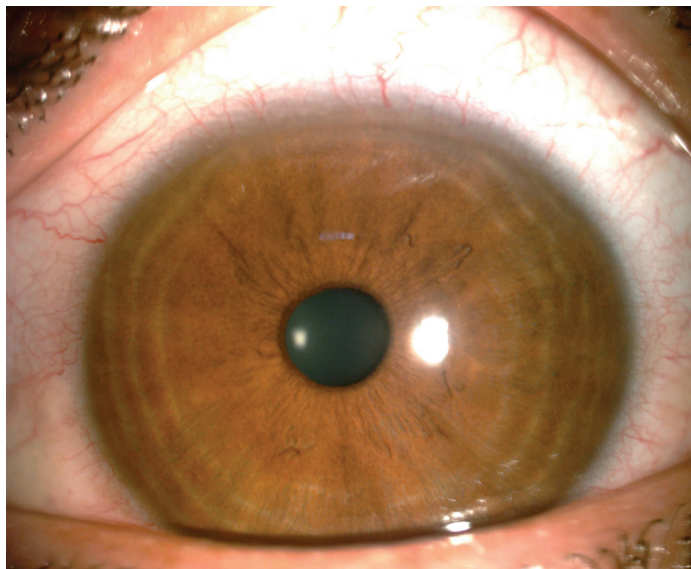
**Corresponding Author:** Tongabay Cumurcu, Inonu University Faculty of Medicine Department of, Ophthalmology, Malatya, Turkey

**E-mail:** tongabay@superonline.com

toxic materials. Otherwise, the stinger may embedded into the cornea or conjunctiva and cause to infiltration, inflammation and/or corneal edema (3).



**Figure 2.** At the first week follow-up, the corneal lesion had begun healed and amnion membrane had also began to melted



**Figure 3.** At the 3th month follow-up, the corneal lesion had healed completely at the site of the pannus

Teoh SC et al. have reported that intractable glaucoma after corneal honey bee sitting (4). So, we want to be sure about IOP and it was normal. In addition, some reports was mentioned to corneal edema and decompensation

due to honey bee sitting, fortunately cornea was clear in our case except pannus area (2,4,5).

Our case had been referred from state hospital for keratoplasty but the pannus and corneal vascularization were seen as superficial and anterior stromal placement. So, we have planned to lamellar keratectomy and amnion membrane transplantation at this site for regular and fast corneal wound healing. Meanwhile we have performed subconjunctival bevacizumab injection for regression of corneal and limbal vascularization. The efficiency of bevacizumab in subconjunctival and intrastromal injection has been reported; the dose of 25 mg/mL appears to be effective and well tolerated in several studies (6,7). We have also administered 0.2% mitomycin-C administrated during 5 minutes perioperative after lamellar keratectomy for inhibition of cellular proliferation and migration (8).

Postoperative follow-up local or general complications were not observed. At the end of three months corneal lesion had healed completely and BCVA had improved to 20/20.

*Competing interests:* The authors declare that they have no competing interest.

*Financial Disclosure:* There are no financial supports

Tongabay Cumurcu ORCID: 0000-0003-0339-4140

## REFERENCES

1. Ang WJ, Md Kadir SZ, Fadzillah AJ, et al. A Case Series of Bee Sting Keratopathy With Different Outcomes in Malaysia. *Cureus* 2017;9:e1035.
2. Gürlü VP, Erda N. Corneal bee sting-induced endothelial changes. *Cornea* 2006;25:981-3.
3. Jain V, Shome D, Natarajan S. Corneal bee sting misdiagnosed as viral keratitis. *Cornea* 2007;26:1277-8.
4. Teoh SC, Lee JJ, Fam HB. Corneal honeybee sting. *Can J Ophthalmol* 2005;40:469-71.
5. Sedaghat MR, Mazouchi M, Poor SS. Corneal bee-sting causing visual complications: A case report. *Iran J Ophthalmol* 2012;24:66-70.
6. Mohammadpour M. Deep intrastromal injection of bevacizumab for the management of corneal neovascularization. *Cornea* 2013;32:109-10.
7. Hamdan J, Boulze M, Aziz A, et al. Corneal neovascularisation treatments compared: Subconjunctival bevacizumab injections and/or photodynamic therapy. *J Fr Ophthalmol*. 2015;38:924-33.
8. Cao D, Chu WK, Ng TK, et al. Cellular proliferation and migration of human pterygium cells: mitomycin versus small-molecule inhibitors. *Cornea* 2018;37:760-6.