

# The effect of oral puerarin administration on wound healing in diabetic rat model

Akif Turer<sup>1</sup>, Mehmet Emin Onger<sup>2</sup>

<sup>1</sup>Bulent Ecevit University, Faculty of Dentistry, Department of Oral and Maxillofacial Surgery, Zonguldak, Turkey

<sup>2</sup>Ondokuz Mayıs University, Faculty of Medicine Department of Histology and Embryology, Samsun, Turkey

Copyright © 2018 by authors and Annals of Medical Research Publishing Inc.

## Abstract

**Aim:** The aim of this study is to examine the effect of the oral administration of puerarin on wound healing in diabetic rat.

**Material and methods:** Twenty-four rats were divided into three groups: Group 1 (n:8) non diabetic control (NDC), group 2 (n:8) diabetic control (DC), group 3 (n:8) diabetic puerarine (DP). Rats Group DC and DP were injected a single dose 200 mg/kg streptozin solution for diabetic model. A full thickness linear incision was made in the paravertebral region of the rats and the wound edges were covered with a sterile plaster. In Group NDC and DC, rats were given saline solution for 7 days. In Group DP, rats were given 200 mg/kg puerarin with oral gavage for 7 days. All animals were euthanized at 7 days postoperative. Connective tissue volumes and new vessel formation were measured with stereological analysis

**Results:** Stereologic analysis showed that Group NDC and DP had significantly more connective tissue volume at 7 days compared with group DC. New vessel formation volumes were also significantly lesser in group DC. Connective tissue and new vessel volumes difference were not statistically significant between group NDC and DP.

**Conclusion:** Orally administered puerarin enhances new vessel formation and support wound healing in diabetic rats.

**Keywords:** Diabetes Mellitus; Puerarin; Wound Healing

## INTRODUCTION

Diabetes mellitus is a disease affecting millions of people worldwide and increasing day by day. Diabetes is a common disease characterized by elevated levels of free glucose as a result of diminished levels of insulin (1). In diabetes, the microvessels are damaged and the blood flow of the tissue decreases. In case of insufficient blood flow, there is a delay in wound healing with ischemic areas. In diabetic patients, ischemia related non-healing wounds can cause tissue or organ loss (2). Wound healing is a complex mechanism with different steps. Soft tissue healing has three phases such as inflammatory, proliferation and maturation. The problem that occurs in any of these phases may cause delay in wound healing. Inflammation, foreign body and systemic diseases such as diabetes can be among the reasons for delaying wound healing (3).

Delay in wound healing in diabetic patients may lead to

major problems in oral and maxillofacial surgery. Soft tissue healing problems may negatively affect the operations such as grafting during implant surgery. Clinicians also investigated different methods to reduce the negative effects or complications of diabetes mellitus. Mostafavinia et al. examined the effects of photobiomodulation on tibial bone defect in streptozotocin (STZ)-induced type 1 diabetes mellitus in rats (4). Heshmati and Namazi reviewed effects of black seed on diabetes mellitus and metabolic parameters (5).

In Diabetes mellitus, addition to medical therapy, diet and alternative treatment methods may be used (6). Puerarin is isolated from the body of *Pueraria lobata* plant. It has been used for many years in alternative Chinese medicine. It is a major isoflavone phytoestrogen that is used in a variety of medical situations due to beneficial effects such as vasodilatation, antioxidant, anticancer, anti-inflammatory, reducing fever, providing bone formation and decrease insulin resistance (7). Puerarin has been

Received: 04.05.2018 Accepted: 26.07.2018 Available online: 01.08.2018

Corresponding Author: Akif Turer, Bulent Ecevit University, Faculty of Dentistry, Department of Oral and Maxillofacial Surgery, Zonguldak, Turkey, E-mail: akifturer@gmail.com

used in China for diabetes mellitus (DM) treatment since the early 1990s. Although studies showed that puerarin has positive effects on diabetes and also inhibits different diabetic complications (8,9), to our knowledge there is no study about effect of puerarin on soft tissue healing in diabetic rat model.

The aim of this study is to evaluate the effect of puerarin on wound healing in diabetic rat model.

## MATERIALS AND METHODS

### Animals and experimental design

This study was approved by the Animal Experimentation Committee of Bülent Ecevit University, Zonguldak, Turkey with a protocol number 2015-19-02/09. 6-8 week-old twenty-four rats were used in this study. Cages of all animals were in rooms with temperature of  $22 \pm 1$  C and humidity rate of 40-60%. Twelve h of day and 12 h of night standardization was configured by illumination system. Rats were divided into three groups. Group 1 (n:8) non diabetic control (NDC), group 2 (n:8) diabetic control (DC), group 3 (n:8) diabetic puerarin (DP).

### Surgical procedure

Animal laboratory was used for surgical operations. Anesthesia was performed with intraperitoneal injection of 35 mg/kg ketamine hydrochloride (10% Ketasol; Richter Pharma AG, Wels, Austria) and 3 mg/kg xylazine hydrochloride (Rom-puns, Bayer, Leverkusen, Germany). Under sterile conditions, a full thickness linear incision was made in the paravertebral region of the rats. The wound edges were covered with a sterile plaster. All animals were sacrificed at day 7 after surgery. The wound area was examined by stereological analyses. In group DP, all rats were given 200 mg puerarin (diluted in distilled water) (99%) (Sigma-Aldrich, St Louis, MO) by oral gavage method for 7 days after diabetic model preparation.

### Diabetic rat model

Diabetes was induced by a single intraperitoneal injection of Streptozocin (STZ) solution (200mg/kg). Rats were fasted for 16 hours prior to injection. Freshly prepared 0.1M Citrate buffer was added to streptozotocin powder (Sigma 85882) with final concentration of 20 mg/ml. On the first day of the injection the rats were fed with 10% sucrose. The next day rats were fed with fresh water only. Body weight and blood glucose were measured after injection at least once daily and if necessary, more frequent measurements were made. Blood glucose levels were measured by using tail vein and recorded with a blood glucometer and test strips (ACCU-CHEK Active, Roche Diagnostics, Mannheim, Germany). Rats with fasting glucose levels  $\geq 16$  mmol/L were considered diabetic.

### Tissue Process and Stereological Methods

Samples were prepared using standard histological procedures. After fixation in 10% formalin for 10 days, the samples were gradually dehydrated in an ethanol series (70%, 80%, 96%, and 100%), placed in xylene for clearing, and then embedded in paraffin. The tissue blocks were sectioned at 5  $\mu$ m on a microtome (Leica RM2255, Germany) and stained with hematoxylin-eosin.

The sections selected and stained with hematoxylin and eosin were photographed using a stereology analysis system (Stereoin- vestigator 9.0; Microbrightfield, Williston, VT) and a light micro- scope (M4000 B; Leica Instruments) equipped with a digital color camera (Microbrightfield). The unbiased Cavalieri method was applied to the light microscopy images to stereologically estimate the volume of connective tissue and new blood vessel formation using point-counting test grids. The point density of the point-counting grids was designed to obtain an appropriate coefficient of error for the area of interest in the images of the serial sections. The grid, with its systematic array of points was placed randomly on the image shown on the screen of a personal computer. The coefficient of error and coefficient of variation were estimated according to the formula of Gundersen and Jensen (10).

### Statistical Analyses

The Shapiro–Wilk test was used to evaluate the normal distribution of the data. The stereological data was analyzed with the Kruskal–Wallis non-parametric test followed by post hoc group comparisons with the Bonferroni-adjusted Mann – Whitney U test, after the normality test of the data failed. For the Bonferroni correction, a  $1/4$  0.05/3  $1/4$  0.016 was considered to indicate statistical significance. All tests were performed using SPSS ver. 19.0 (SPSS, Chicago, IL).  $P < 0.05$  was considered to indicate statistical significance.

## RESULTS

There was no wound dehiscence or wound infection in surgical site. All rats tolerated surgery and postsurgical period without complication.

### Histological evaluation

In non-diabetic control group (NDC), almost completely re-epithelization was observed. Connective tissue and collagen formation was determined. Newly formed blood vessels were present in the wound site.

In diabetic group (DP), the incision line was detectable, no re-epithelization was observed. Inflammatory cells were observed with connective tissue. A small number of vascularization was observed in wound area.

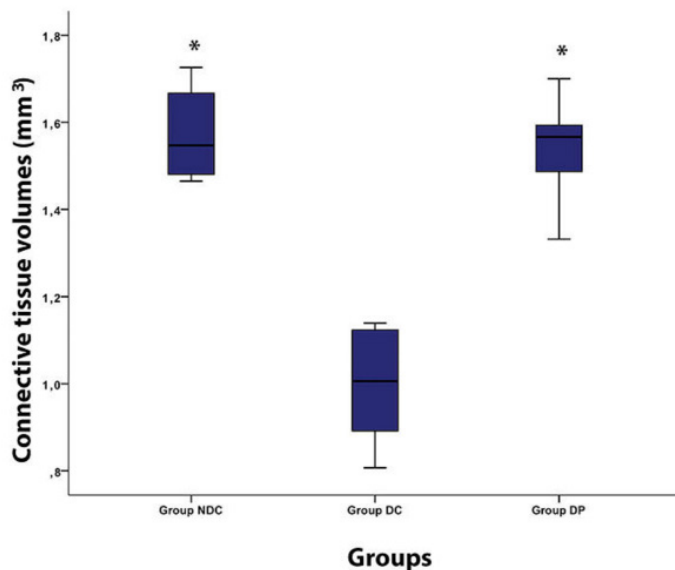
In diabetic puerarin group (DPG), according to diabetic group more re-epithelization was observed. Infiltration cells were observed and the newly formed blood vessels were more than the diabetic group.

### Stereological analysis

The connective tissue volumes for groups NDC and DP were 1,57 0,1 mm<sup>3</sup> and 1,54 0,1 mm<sup>3</sup> respectively. For both groups, it was a statistically significant difference between group DC with a mean connective tissue volume, 0,99 mm<sup>3</sup> ( $p$  0,05). Although connective tissue volume in group NDC was more greater than group DP, the difference was not statistically significant (Figure 1).

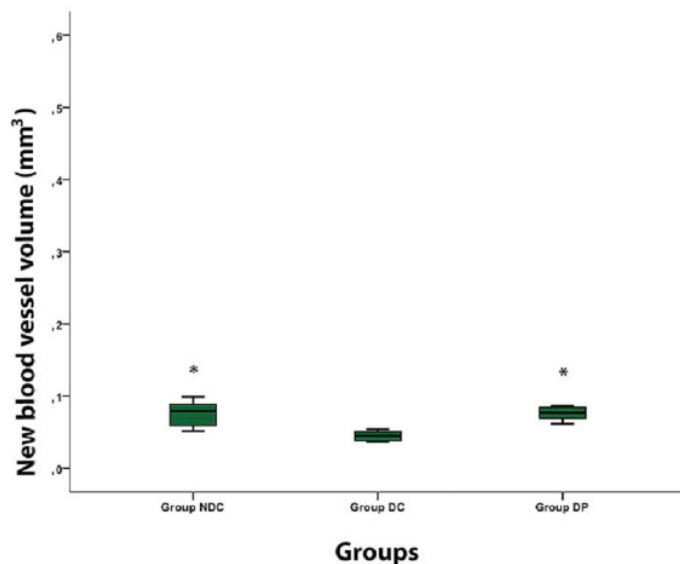
New vessel volume in groups NDC was 0,076 0,017 mm<sup>3</sup> and it was superior than in group DP (0,075 0,009 mm<sup>3</sup>)

but the difference was not statistically significant ( $p > 0,05$ ). In group DC mean new vessel volume was  $0,044 \pm 0,006 \text{ mm}^3$  and it was significantly lesser than other groups (Figure 2).



**Figure 1.** The connective tissue volume ( $\text{mm}^3$ ) from stereological analysis in defects

\*Statistically significant difference from Diabetic Control group (group DC) (Bonferroni-adjusted Mann–Whitney U test)



**Figure 2.** The new vessel volume ( $\text{mm}^3$ ) from stereological analysis in defects

\*Statistically significant difference from Diabetic Control group (group DC) (Bonferroni-adjusted Mann–Whitney U test)

## DISCUSSION

In our study, we hypothesized that oral administered puerarin may have positive effect on angiogenesis and soft tissue healing in diabetic rats. After linear paravertebral incision, we applied sterile plaster on wound area and administered puerarin by oral gavage method. The data

were analyzed by stereological methods.

We choose rat as an experimental model in our study. There are some reasons to prefer rat model in animal studies such as; physiologically similar to human, easy to feed and it is cheap (11). Although different methods are mentioned in literature to obtain the diabetic rat model, STZ injection is the one of the most common method. In literature there are different methods and doses for STZ injection (12-14). We used Deeds et al. (14) method for diabetic rat model preparation with a single dose of 200 mg STZ injection. Blood glucose measurement verified the diabetic rat model.

In diabetic patients, although there are many complications, one of the most important is impaired soft tissue healing due to the micro deterioration of vascular structure (2). Soft tissue healing is so important in oral and maxillofacial surgery and directly affects the success of operation. Especially in cases like dental implant surgery or graft operations that primary wound healing is important, inadequate soft tissue healing in diabetic patients may lead problems (15).

Clinicians investigated different methods or agents to prevent the adverse effects of complications in diabetes patients. Hong et al. showed positive effect of recombinant human epidermal growth factor on wound healing in diabetic rats (16). Vascular endothelial growth factor (VEGF) was used to treat wound healing in diabetic rats. VEGF-treated wounds were observed early re-epithelization and increased neovascularization (17). Marston used Dermagraft for tissue engineering on soft tissue healing in diabetes mellitus (18). Besides all these materials or agents, herbal products have been used for years on wound healing in diabetic patients. The minimal toxic effects, less favorable side-effects and ease of preparation are the main advantages of these products (19).

In literature, there are studies that used different plant products such as kaempferol, watercress and yerba mate to reduce diabetic complications (20-22). We examined the effect of puerarin on wound healing in diabetic rats. Puerarin is isolated from the body of *Pueraria lobata* plant. It has been used for many years in alternative Chinese medicine (7). In literature, there are studies that showed different beneficial effects of puerarin. Li et al. (23) showed that intraperitoneal injection of puerarin alleviated acute liver injury and reduced plasma alanine aminotransferase and aspartate aminotransferase levels. Yin et al. (24) investigated different doses of puerarin on diabetic cardiomyopathy. 100 mg/kg and 200 mg/kg puerarin have protective effect on diabetic cardiomyopathy and inflammation. In another study, the effects of three different doses of puerarin on atopic dermatitis were examined. Results showed that puerarin has positive effect on skin lesion by regulating different atopic and inflammatory mediators (25). In our study, 200 mg/kg puerarin were given by daily oral gavage method for 7 days. Puerarin dose was decided according to previous

study results that examined effect of puerarine in diabetic rats (24). According to our knowledge there is no study about effect of puerarine on soft tissue healing.

Stereological advantages over conventional histological examination methods and the most important of these advantages is inclusion of third dimension. This factor increases reliability (26). In our study we choose stereological methods for analyses of wound healing. According to stereological analyses oral puerarine reduced the negative effect of diabetes as similar to literature. Wound healing and newly formed blood vessel formation in the healthy control group were better than diabetic group using puerarine, but no statistically significant was found between them. When diabetic rat models were compared, it was observed that wound healing and new blood vessel values of puerarine group were significantly higher.

## CONCLUSION

As a conclusion that orally administered puerarin has beneficial effects on wound healing in diabetic rats. Further investigations aimed at finding optimal doses and maximize the anabolic actions of puerarin on soft tissue are required.

*Competing interests: The authors declare that they have no competing interest.*

*Financial Disclosure: There are no financial supports*

*Ethical approval: This work has been approved by the Institutional Review Board.*

## REFERENCES

1. Bullard KM, Cowie CC, Lessem SE, et al. Prevalence of Diagnosed Diabetes in Adults by Diabetes Type -United States, 2016. *MMWR Morb Mortal Wkly Rep.* 2018;67:359-61.
2. Strain WD, Paldánus PM. Diabetes, cardiovascular disease and the microcirculation. *Cardiovasc Diabetol.* 2018;17:57.
3. Andersson L, Andreasen JO. Soft tissue injuries. In: Andreasen JO, Andreasen FM, Andersson L, eds. *Textbook and color atlas of traumatic injuries to the teeth*, 4th edition. Oxford; Blackwell Munksgaard; 2007. p. 577-97.
4. Mostafavinia A, Masteri Farahani R, Abdollahifar MA, et al. Evaluation of the effects of photobiomodulation on partial osteotomy in streptozotocin-induced diabetes in rats. *Photomed Laser Surg.* 2018;31.
5. Heshmati J, Namazi N. Effects of black seed (*Nigella sativa*) on metabolic parameters in diabetes mellitus: a systematic review. *Complement Ther Med.* 2015;23:275-82.
6. Majid SA, Khorasgani MR, Emami SH, et al. Study of Diabetic cutaneous wound healing in rats treated with *Lactobacillus Casei* and its Exopolysaccharide. *International Journal of Advanced Biotechnology and Research.* 2016;7:2083-92.
7. Zhou YX, Zhang H, Peng C. Puerarin: a review of pharmacological effects. *Phytother Res.* 2014;28:961-75
8. Hu W, Yang X, Zhe C, et al. Puerarin inhibits iNOS, COX-2 and CRP expression via suppression of NF- $\kappa$ B activation in LPS-induced RAW264.7 macrophage cells. *Pharmacol Rep.* 2011;63:781-9.
9. Zhang W, Liu CQ, Wang PW, et al. Puerarin improves insulin resistance and modulates adipokine expression in rats fed a high-fat diet. *Eur J Pharmacol.* 2010;649:398-402.
10. Gundersen HJ, Jensen EB, Kiou K, et al. The efficiency of systematic sampling in stereology--reconsidered. *J Microsc.* 1999;193:199-211.
11. Kochi G, Sato S, Fukuyama T, et al. Analysis on the guided bone augmentation in the rat calvarium using a microfocus computerized tomography analysis. *Oral Surg Oral Med Oral Pathol Oral Radiol Endod.* 2009;107:42-8.
12. Ritarwan K, Lelo A, Pane YS, et al. Increasing Atherosclerosis in Streptozotocin-Induced Diabetes into Four Groups of Mice. *Open Access Maced J Med Sci.* 2018;6:287-92.
13. Mayyas F, Jaradat R, Alzoubi KH. Cardiac effects of fish oil in a rat model of streptozotocin-induced diabetes. *Nutr Metab Cardiovasc Dis.* 2018;28:592-99.
14. Deeds MC, Anderson JM, Armstrong AS, et al. Single dose streptozotocin-induced diabetes: considerations for study design in islet transplantation models. *Lab Anim.* 2011;45:131-40.
15. Hasegawa H, Ozawa S, Hashimoto K, et al. Type 2 diabetes impairs implant osseointegration capacity in rats. *Int J Oral Maxillofac Implants.* 2008;23:237-46.
16. Hong JP, Jung HD, Kim YW. Recombinant human epidermal growth factor (EGF) to enhance healing for diabetic foot ulcers. *Ann Plast Surg.* 2006;56:394-8.
17. Galiano RD, Tepper OM, Pelo CR, et al. Topical vascular endothelial growth factor accelerates diabetic wound healing through increased angiogenesis and by mobilizing and recruiting bone marrow-derived cells. *Am J Pathol.* 2004;164:1935-47.
18. Marston WA. Dermagraft, a bioengineered human dermal equivalent for the treatment of chronic nonhealing diabetic foot ulcer. *Expert Rev Med Devices.* 2004;1:21-31.
19. Micera A, Vigneti E, Pickholtz D, et al. Nerve growth factor displays stimulatory effects on human skin and lung fibroblasts, demonstrating a direct role for this factor in tissue repair. *Proc Natl Acad Sci U S A.* 2001;98:6162-7.
20. Al-Numair KS, Chandramohan G, Veeramani C, et al. Ameliorative effect of kaempferol, a flavonoid, on oxidative stress in streptozotocin-induced diabetic rats. *Redox Rep.* 2015;20:198-209.
21. Hadjzadeh MA, Rajaei Z, Moradi R, et al. Effects of Hydroalcoholic Extract Of Watercress (*Nasturtium Officinale*) Leaves On Serum Glucose And Lipid Levels In Diabetic Rats. *Indian J Physiol Pharmacol.* 2015;59:223-30.
22. Rocha DS, Casagrande L, Model JFA, et al. Effect of yerba mate (*Ilex paraguariensis*) extract on the metabolism of diabetic rats. *Biomed Pharmacother.* 2018;105:370-6.
23. Li L, Yin H, Zhao Y, et al. Protective role of puerarin on LPS/D-Gal induced acute liver injury via restoring autophagy. *Am J Transl Res.* 2018;10:957-65.
24. Yin MS, Zhang YC, Xu SH, et al. Puerarin prevents diabetic cardiomyopathy in vivo and in vitro by inhibition of inflammation. *J Asian Nat Prod Res.* 2018;11:1-8.
25. Lee JH, Jeon YD, Lee YM, et al. The suppressive effect of puerarin on atopic dermatitis-like skin lesions through regulation of inflammatory mediators in vitro and in vivo. *Biochem Biophys Res Commun.* 2018;498:707-14.
26. Novaes RD, Penitente AR, Talvani A, Use of fluorescence in a modified disector method to estimate the number of myocytes in cardiac tissue. *Arq Bras Cardiol.* 2012;98:252-8.