

# Comparison of the microvessel density of gastric regions in normal and sleeve gastrectomized rats

Suleyman Orman<sup>1</sup>, Sinan Yol<sup>2</sup>, Huseyin Uzun<sup>3</sup>, Ayse Bahar Ceyran<sup>4</sup>

<sup>1</sup>Istanbul Medeniyet University Goztepe Training and Research Hospital, Department of Gastrointestinal Surgery, Istanbul, Turkey

<sup>2</sup>VM Medical Park Hospital, Department of Gastrointestinal Surgery, Istanbul, Turkey

<sup>3</sup>Istanbul NB Kadikoy Hospital, Department of General Surgery, Istanbul, Turkey

<sup>4</sup>Istanbul Bilim University, Faculty of Medicine, Department of Pathology, Istanbul, Turkey

Copyright © 2018 by authors and Annals of Medical Research Publishing Inc.

## Abstract

**Aim:** Background: The aim of this study is to compare the microvessel densities of different normal gastric regions and to determine the effects of sleeve gastrectomy on the microvessel density of tissues alongside the remnant stomach.

**Material and Methods:** Twenty male Wistar albino rats were divided into two groups. Rats in the control group were immediately sleeve gastrectomized under anesthesia and a wedge resection of the esophagogastric junction (EGJ), the fundus, corpus and antral gastric regions was performed, before sacrifice. Meanwhile, rats in the experiment group also underwent sleeve gastrectomy but were not sacrificed until the 5<sup>th</sup> postoperative day. At this point, gastric tissues alongside the sleeve gastrectomy area were then wedge-resected. The microvessel densities of these two groups were evaluated and compared.

**Results:** When comparing distinctive gastric regions within the control group, the microvessel density of the esophagogastric junction was found to be less than in the corpus or fundus (20.04±4.45; 36.28±9.98, 39.4±9.57; p < 0.01). When comparing the control and experiment groups, No significant difference in the microvessel density of the esophagogastric junction was found (20.04 ± 4.45, 24.63 ± 8.91, p > 0.05). The sleeve gastrectomy also had no significant effect on the microvessel densities at the esophagogastric junction or corpus (24.63±8.91, 22.24±7.63; p > 0.05).

**Conclusion:** The esophagogastric junction has a lower microvessel density than the corpus in a normal stomach. Sleeve gastrectomy has no adverse effect on the microvessel density of the esophagogastric junction.

**Keywords:** Sleeve Gastrectomy; Microvessel Density; Rat.

## INTRODUCTION

Sleeve gastrectomy (SG) is an effective surgical procedure for treating the frequently seen health problem of morbid obesity (1,2). However, SG is not exempt from complications. Cut surface leakage, which is one of the most feared and fatal complications, is seen in 0-7% of patients (3). This kind of leakage is commonly located at the proximal part of the cut surface, beside the esophagogastric junction (EGJ) (4).

Hematopoietic progenitor cell antigen, cluster of differentiation 34 (CD34), is one of a family of transmembrane sialomucin proteins that show expression on vascular tissue (5).

Anti-CD34 is an endothelial cell-specific antibody which can gauge microvessel density (MVD) in various tissues with great sensitivity. Determining the number of

microvessels by counting the endothelial cells in hotspot areas is now the preferred method for vascular density assessment in several studies (6-8,11).

The second aim of the present study was to investigate the effect of sleeve gastrectomy on the MVD of gastric regions. Hence, the MVD of normal gastric regions was compared to that of tissues alongside the cut-surface healing area of there mnant stomach 5 days after sleeve gastrectomy.

## MATERIAL and METHODS

Our study used twenty male albino Wistar rats, weighing 300-350g, according to a protocol reviewed and approved by the Animal Committee of Istanbul University School of Medicine, Istanbul; and it was carried out at the Istanbul University Aziz Sancar Experimental Medicine Research Institute. All animals were managed in accordance with

**Received:** 31.07.2018 **Accepted:** 11.08.2018 **Available online:** 29.08.2018

**Corresponding Author:** Suleyman Orman, Istanbul Medeniyet University Goztepe Training and Research Hospital, Department of Gastrointestinal Surgery, Istanbul, Turkey, **E-mail:** suleymanorm@hotmail.com

the recommendations of the National Institute of Health Guidelines for the Care and Use of Laboratory Animals.

### Animals and Experiment Design

The animals were housed in stainless steel cages under carefully controlled temperature ( $23\pm 2$  °C) and humidity conditions, with 12h dark/light cycles. The rats were randomly assigned to two groups; control (n=10) and experiment (n=10) groups.

### Surgical Procedures

All rats were subjected to water-only fasting for 6 hours preoperatively. Thirty minutes before surgery, 30 mg/kg ceftriaxone was injected intramuscularly. All surgical procedures were performed under aseptic conditions, using 2.5% povidone-iodine for skin disinfection after skin hair removal. Rats were anesthetized with ketamine hydrochloride (50 mg/kg) and xylazine (5 mg/kg) intraperitoneally, and were kept on a warm pad throughout the experiment, to maintain a constant body temperature of 37 °C. A 2.5-3 cm long midline incision was made to sufficiently expose the stomach. Sleeve gastrectomies were performed as described in our previous paper (9).

Briefly, the area for resection (about 70% of the stomach) was defined with vascular forceps to include most of the fundus and then the SG was carried out. Regional wedge resections were performed immediately on rats in the control group, who were then sacrificed. In the experiment group, gastrorrhaphy was carried out using an invaginating continuous polyglactin 910 (Vicryl® 5-0; Ethicon, São Paulo) hand-sewn suture (Schimieden pattern). The laparotomy was closed with a continuous single-plane hand-sewn suture of polyglactin 910 (Vicryl® 3-0; Ethicon, São Paulo). The rats in this group were housed separately after the operation and kept hydrated with injections of 5 ml saline solution to the subcutaneous tissue.

In all rats, esophagogastric junction (EGJ), fundus, corpus and antral gastric regions' wedge resections with full layers were performed from the stomach remaining after resection. Rats in the experiment group were sacrificed on the 5<sup>th</sup> postoperative day after full layer wedge resections had been performed.

### Postoperative treatment

After surgery, the experiment rats' body temperature was restored by heating lamp. After the operation, no water was given for the first 4 hours, and then free access was given. Upon resuming oral nutrition, all animals were assigned a liquid diet (10% dextrose) for 3 days, after which standard feed was given for the remaining 2 days. Daily observations of the rats' health status were made.

### Histopathology

Histopathological evaluation was performed by a single, 'blinded' pathologist. Tissue samples were 10% formaldehyde-fixed and paraffin-embedded. The paraffin blocks were cut at a thickness of 4 mm and two serial sections for each case were prepared for staining with anti-CD34. Immunohemagglutination (IHA) tests were performed as previously described (8). The tissues of each rat at 5 separate large magnification areas (x400) (LMA) were examined. Quantitative vessel counts for

MVD (number/mm<sup>2</sup>) assessment were performed by the method described by Vermeulen et al (10). Numbers of vessels stained with anti-CD34 were categorized as 1, 2 or 3 positive. (1 positive: 10-24 vessels / LMA; 2 positive: 25-49 vessels / LMA; 3 positive: 50 and more vessels / LMA).

### Statistical Analysis

NCSS (Number Cruncher Statistical System) 2007 (Kaysville, Utah, USA) program was used for statistical analysis. When evaluating study data, for comparisons of quantitative data as well as descriptive statistical methods, frequency and ratio were used. The Mann Whitney U test was used for descriptive statistical methods of the two groups as well as for quantitative data without normal distribution. The Wilcoxon Signed Ranks test was used for intra-group comparison of abnormally distributed parameters. A p value <0.05 was considered statistically significant.

## RESULTS

Nine rats from the experiment group survived, with one dying on the day of operation from anesthesia-related causes.

The distribution of anti-CD34 staining patterns in each group is given in Table 1.

### Comparison of MVDs at different regions of the normal stomach and the sleeve gastrectomy

In the EGJ region, there was no statistically significant difference between the MVDs of the control and experiment groups, ( $20.04\pm 4.45$ ,  $24.63\pm 8.91$ , respectively;  $p>0.05$ ) (Table 2).

However, in the corpus and antrum areas, MVDs of the control group were significantly higher than in the experiment group (corpus -  $36.28\pm 9.98$ ,  $22.24\pm 7.63$ ;  $p<0.01$ ; antrum -  $20.44\pm 5.21$ ,  $15.21\pm 4.48$ ;  $p<0.05$ ).

### Comparison of MVDs at different gastric regions in the control group

There was a statistically significant difference between MVD levels at the EGJ and corpus areas ( $20.04\pm 4.45$ ,  $36.28\pm 9.98$ ;  $p<0.01$ ) within the control group. The EGJ also had a lower (++) staining rate than the corpus.

A statistically significant difference between MVD levels at the EGJ and fundus areas ( $20.04\pm 4.45$ ,  $39.4\pm 9.57$ ;  $p<0.01$ ) was also noted. EGJ staining was found to be lower (++) than in the fundus (+++) (Table 1,3) (Figure 1).

However, there was no statistically significant difference between MVD levels at the EGJ and antrum areas ( $20.04\pm 4.45$ ,  $20.44\pm 5.21$ ;  $p>0.05$ ).

### Comparison of MVDs at different gastric regions in the experiment group

In the experiment group, there was no statistically significant difference between MVD levels at the EGJ and corpus areas ( $24.63\pm 8.91$ ,  $22.24\pm 7.63$ ;  $p>0.05$ ). However, there was a statistically significant difference between MVD levels in the EGJ and the antrum ( $24.63\pm 8.91$ ,  $15.21\pm 4.48$ ;  $p<0.05$ ). Also, EGJ (++) staining was found to be higher than that of the antrum (Table 1,4) (Figure 2).

**Table 1. Distribution of anti-CD34 staining patterns in control and experiment groups according to gastric region**

| Region | Anti-CD34 pattern | Control Group (n=10) | Experiment Group (n=9) |
|--------|-------------------|----------------------|------------------------|
| EGJ    | (+)               | 9 (90.0)             | 5 (55.6)               |
|        | (++)              | 1 (10.0)             | 4 (44.4)               |
|        | (+)               | 0 (0)                | 6 (66.7)               |
| Corpus | (++)              | 9 (90.0)             | 3 (33.3)               |
|        | (+++)             | 1 (10.0)             | 0 (0)                  |
|        | (+)               | 8 (80.0)             | 9 (100.0)              |
| Antrum | (++)              | 2 (20.0)             | 0 (0)                  |
|        | (+)               | 1 (10.0)             | -                      |
|        | (++)              | 6 (60.0)             | -                      |
| Fundus | (+)               | 1 (10.0)             | -                      |
|        | (++)              | 6 (60.0)             | -                      |
|        | (+++)             | 3 (30.0)             | -                      |

**Table 2. Comparison of MVDs in the control and experiment groups according to gastric region**

| Region |                   | Control Group          | Experiment Group       | P        |
|--------|-------------------|------------------------|------------------------|----------|
| EGJ    | Min–Max (Mean±SD) | 13-28.2 (20.04±4.45)   | 13.3-37.2 (24.63±8.91) | a0.220   |
| Corpus | Min–Max (Mean±SD) | 24.2-53.6 (36.28±9.98) | 12-36.6 (22.24±7.63)   | b0.003** |
| Antrum | Min–Max (Mean±SD) | 14-29 (20.44±5.21)     | 10.5-23.6 (15.21±4.48) | a0.022*  |
| Fundus | Min–Max (Mean±SD) | 26.2-53.6 (39.4±9.57)  | -                      | -        |

<sup>a</sup>Mann Whitney U Test \*p<0.05 \*\*p<0.01

**Table 3. Comparison of MVDs in the control group according to gastric region**

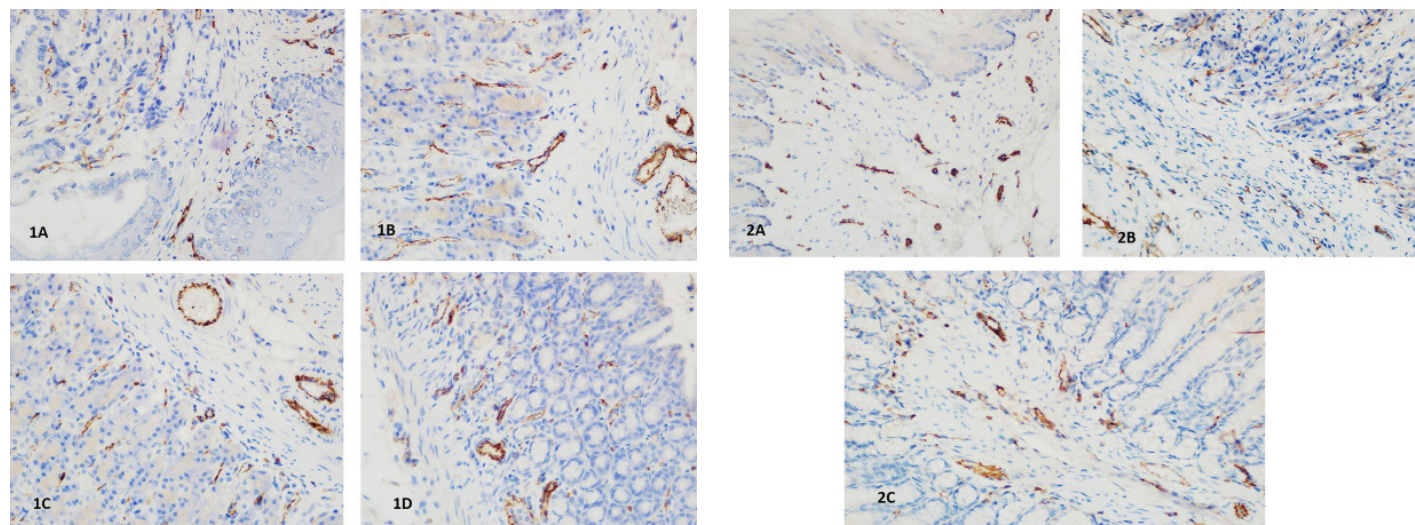
|         | EGJ        | Corpus     | Antrum     | Fundus     | EGJ- Corpus: p | EGJ- Antrum: p | EGJ- Fundus: p |
|---------|------------|------------|------------|------------|----------------|----------------|----------------|
| Min-Max | 13-28.2    | 24.2-53.6  | 14-29      | 26.2 -53.6 | 0.005*         | 0.798          | 0.005*         |
| Mean±SD | 20.04±4.45 | 36.28±9.98 | 20.44±5.21 | 39.4±9.57  |                |                |                |

Wilcoxon Signed Ranks Test \*p<0.01

**Table 4. Comparison of MVDs in the experiment group according to gastric region**

|         | EGJ        | Corpus     | Antrum     | EGJ-Corpus; p | EGJ-Antrum; p |
|---------|------------|------------|------------|---------------|---------------|
| Min-Max | 13.3-37.2  | 12-36.6    | 10.5-23.6  | 0.236         | 0.021*        |
| Mean±SD | 24.63±8.91 | 22.24±7.63 | 15.21±4.48 |               |               |

Wilcoxon Signed Ranks Test \*p<0.05



**Figure 1.** In the control group, microscopic appearance of rats' vascular structures, following staining with anti-CD34. **1A)** Esophagogastric junction, **1B)** Fundus, **1C)** Corpus, **1D)** Antrum. Example of 2 positive staining of anti-CD34 with vessel sections following lamina propria, x400

**Figure 2.** In the experiment group, microscopic appearance of rats' vascular structures, following staining with anti-CD34. **2A)** Esophagogastric junction, **2B)** Corpus, **2C)** Antrum. Example of 2 positive staining of anti-CD34 with vessel sections following lamina propria, x400



## DISCUSSION

In obesity surgery, SG leakage is a rare but unsurprising complication (3). Leakages are commonly located at the proximal part of the cut surface of the sleeve gastrectomy, next to the EGJ (4).

Leakages after sleeve gastrectomy are categorized as either mechanical-tissular causes that usually appear within 2 days or ischemic causes that appear within 5 days of surgery (11,12). Successful wound healing depends upon angiogenesis. Clinically, angiogenesis first becomes visible in the wound bed at 3<sup>rd</sup>–5<sup>th</sup> day after injury (13). In a study, on the development of the quail embryo, angiogenesis commenced on the 3<sup>rd</sup> day of surgery (14). In another study, MVD measurement of a healing rat colon anastomosis was performed on the 7<sup>th</sup> postoperative day (15). In our study, the 5<sup>th</sup> postoperative day was selected for the evaluation of MVD.

The vascular supply distribution of the remnant stomach alters after sleeve gastrectomy. Measurement of the overall vasculature of different tissues and distribution of MVD is commonly evaluated using the anti-CD34 IHA method (6-8,10). MVD has been seen to increase in many gastrointestinal and breast tumors (16-20) but decrease in bile duct injuries and chronic radiation proctitis (21,22). It is accepted that an increase in MVD is more favorable for wound healing and it has been shown that external influences can change MVD, as in the effect of Lugol's solution on Grave's disease (22,23). In our study, MVD was measured at several different regions in order to more accurately evaluate the vascular supply of the stomach and investigate any effect sleeve gastrectomy might have.

After SG surgery, the second most frequent cause of death is cut-surface leakage and the mortality rate is serious (24). A gastric wall perfusion study, using computed tomography, demonstrated that the blood supply to the EGJ was inferior to that of other areas of the stomach (25). Most obesity surgeons believe that avoiding the EGJ during SG is more judicious for ischemic reasons (26). According to our study, the EGJ had a lower MVD than the corpus in normal stomachs; a result which is compatible with previous studies. However, in the experiment group there was no statistically significant difference between MVD levels at the EGJ and corpus regions. This result raises questions about the ischemic mechanism and the adverse effect of sleeve gastrectomy on the vascular supply at the EGJ region. As there was no statistically significant difference between the MVD levels at the EGJ of each group, the increase in the MVD in the experiment group may be due to compensatory mechanisms of the wound healing process. According to these results, it may be speculated that inappropriate surgical technique plays a more significant role in leakages after sleeve gastrectomy than the naturally reduced vascularization of the EGJ region. The ischemia of the sleeve gastrectomy cut surface may be attributed to improper surgical technique rather than natural angiogenic causes.

To the best of our knowledge, this is the first experiment study to examine the effect of SG on MVD; however, the present study has some limitations. First, this is a rat model study which invites reservations about its predictivity for human tissue, although it may provide a good model for further studies. Second, vascularity assessment by using IHA to measure MVD may not give optimal results; further studies are needed to assess MVD with other methods, such as the Western blot method, etc. On the other hand, as this kind of study cannot be carried out on human beings, it is still of value. Despite the limitations, our results may provide a new perspective on which to base future studies.

## CONCLUSION

The EGJ had a lower MVD than the corpus in normal stomachs according to this study. However, in the sleeve gastrectomized group there is no statistically significant difference between MVD levels at the EGJ and corpus regions. The ischemia of the sleeve gastrectomy cut surface may be attributed to improper surgical technique rather than natural angiogenic causes.

*Competing interests: The authors declare that they have no competing interest.*

*Financial Disclosure: There are no financial supports*

*Ethical approval: This work has been approved by the Institutional Review Board. 25.12.2017- 313278*

## REFERENCES

1. Thompson D, Wolf AM. The medical-care cost burden of obesity. *Obes Rev* 2001;2:189-97.
2. Courcoulas AP, Christian NJ, Belle SH, et al. Longitudinal Assessment of Bariatric Surgery (LABS) Consortium. Weight change and health outcomes at 3 years after bariatric surgery among individuals with severe obesity. *JAMA* 2013;310:2416-25.
3. Klimczak T, Klimczak J, Szewczyk T, et al. Endoscopic treatment of leaks after laparoscopic sleeve gastrectomy using MEGA esophageal covered stents. *Surg Endosc* 2018;32:2038-45.
4. Berger ER, Clements RH, Morton JM, et al. The Impact of Different Surgical Techniques on Outcomes in Laparoscopic Sleeve Gastrectomies: The First Report from the Metabolic and Bariatric Surgery Accreditation and Quality Improvement Program (MBSAQIP). *Ann Surg* 2016;264:464-73.
5. Nielsen JS, McNagny KM. Novel functions of the CD34 family. *J Cell Sci* 2008;121:3683-92.
6. Ramsden JD. Angiogenesis in the thyroid gland. *J Endocrinol* 2000;166:475-80.
7. Turner HE, Harris AL, Melmed S, et al. Angiogenesis in endocrine tumors. *Endocr Rev* 2003;24:600-32.
8. Yan B, Zhou Y, Feng S, et al. B-Elemente-Attenuated Tumor Angiogenesis by Targeting Notch-1 in Gastric Cancer Stem-Like Cells. *Evid Based Complement Alternat Med* 2013;2013:268468.
9. Orman S, Karaman K, Basok BI, et al. Effects of thyroid hormone therapy on cut-surface healing of the remnant stomach with short-term weight loss alterations after sleeve gastrectomy. *J Invest Surg* 2017;16:1-10.
10. Vermeulen PB, Gasparini G, Fox SB, et al. Quantification of angiogenesis in solid human tumours: an international consensus on the methodology and criteria of evaluation. *Eur J Cancer* 1996;32:2474-84.

11. Baker RS, Foote J, Kemmeter P, et al. The science of stapling and leaks. *Obes Surg* 2004;14:1290-8.
12. Lossa A, Abdelgawad M, Watkins BM, et al. Leaks after laparoscopic sleeve gastrectomy: overview of pathogenesis and risk factors. *Langenbecks Arch Surg* 2016;401:757-66.
13. Tonnesen MG, Feng X, Clark RA. Angiogenesis in wound healing. *J Invest Dermatol Symp Proc* 2000;5:40-6.
14. Arcalís T, Carretero A, Navarro M, et al. Vasculogenesis and angiogenesis in the subcardinal venous plexus of quail mesonephros: spatial and temporal morphological analysis. *Anat Embryol* 2002;205:19-28.
15. Yoo JH, Shin JH, An MS, et al. adipose-tissue-derived stem cells enhance the healing of ischemic colonic anastomoses: an experimental study in rats. *J Korean Soc Coloproctol* 2012;28:132-9.
16. Bădescu A, Georgescu CV, Vere CC, et al. Correlations between Her2 oncoprotein, VEGF expression, MVD and clinicopathological parameters in gastric cancer. *Rom J Morphol Embryol* 2012;53:997-1005.
17. Liang P, Ren XC, Gao JB, Chen et al. Iodine concentration in spectral ct: assessment of prognostic determinants in patients with gastric adenocarcinoma. *AJR Am J Roentgenol* 2017;209:1033-8.
18. Zygoń J, Szajewski M, Kruszewski WJ, et al. VEGF, Flt-1, and microvessel density in primary tumors as predictive factors of colorectal cancer prognosis. *Mol Clin Oncol* 2017;6:243-8.
19. Liu H, Wu J, Liu XC, et al. Correlation between microvascular characteristics and the expression of MVD, IGF-1 and STAT3 in the development of colonic polyps carcinogenesis. *Exp Ther Med* 2017;13:49-54.
20. Haisan A, Rogojanu R, Croitoru C, et al. Digital microscopy assessment of angiogenesis in different breast cancer compartments. *Biomed Res Int* 2013;2013:286902.
21. Geng L, Luo D, Zhang HC, et al. Microvessel density at different levels of normal or injured bile duct in dogs and its surgical implications. *Hepatobiliary Pancreat Dis Int* 2011;10:83-7.
22. Wu P, Li L, Wang H, et al. Role of angiogenesis in chronic radiation proctitis: new evidence favoring inhibition of angiogenesis ex vivo. *Dig Dis Sci* 2018;63:113-25.
23. Erbil Y, Ozluk Y, Giriş M, et al. Effect of lugol solution on thyroid gland blood flow and microvessel density in the patients with Graves' disease. *J Clin Endocrinol Metab* 2007;92:2182-9.
24. Jurowich C, Thalheimer A, Seyfried F, et al. Gastric leakage after sleeve gastrectomy-clinical presentation and therapeutic options. *Langenbecks Arch Surg* 2011;396:981-7.
25. Saber AA, Azar N, Dekal M, et al. Computed tomographic scan mapping of gastric wall perfusion and clinical implications. *Am J Surg* 2015;209:999-1006.
26. Rosenthal RJ; International Sleeve Gastrectomy Expert Panel, Diaz AA, et al. International sleeve gastrectomy expert panel consensus statement: best practice guidelines based on experience of >12,000 cases. *Surg Obes Relat Dis* 2012;8:8-19.