

Surgery of Zenker's diverticulum; Single center experience

Sukru Colak, Bunyamin Gurbulak, Ekrem Cakar, Hasan Bektas

Istanbul Training and Research Hospital, Clinic of General Surgery, Istanbul, Turkey

Copyright © 2018 by authors and Annals of Medical Research Publishing Inc.

Abstract

Aim: Zenker's diverticulum is the most frequently seen esophageal diverticula. Zenker's diverticulum should be considered that the patients have symptoms such as dysphagia, regurgitation of undigested food, turbulence sound, chronic cough, weight loss, and halitosis. We aimed to evaluate the patients whom underwent diverticulectomy and cricomyotomy due to Zenker's diverticulum located in the proximal esophagus in terms of demographic features, operative type, postoperative complications and recurrence.

Material and Methods: Between January 2013 and 2018, 10 patients (9 female and 1 male) who underwent surgery due to dysphagia because of the Zenker's diverticulum were evaluated retrospectively. The median age of the patients was 67.5 (47-77). Because of the dysphagia was the most frequently symptom, initial evaluation was performed with upper gastrointestinal system endoscopy (UGSE). All patients were examined barium esophagography and some patients with tomography. Dysphagia levels of the patients were evaluated before and after the operation. Patients were followed-by endoscopy 1 and 6th. months after surgery.

Results: Complications, mortality and morbidity were not seen in postoperative early and late periods. Only 1 patient had recurrence. When compared the dysphasia scores of the patients before and after surgery were significantly improved after operation.

Conclusion: Diverticulectomy and cricomyotomy operations in Zenker's diverticulum are effective and safe procedures.

Keywords: Zenker's Diverticulum; Dysphagia; Cricopharyngeal Myotomy.

INTRODUCTION

Esophageal diverticulae are very rare conditions. Zenker's diverticulum is the most frequently seen esophageal diverticula. The Zenker's diverticulum is caused by increased pressure due to the spasm in the upper sphincter of the esophagus. On the posterior wall of the pharynx in the midline at Killian triangular area, is the outward herniation of the mucosa from the weak point between the transverse fibers of the cricopharyngeus and the oblique fibers of the inferior constrictor. It was described as a pharyngeal pouch by Ludlow in 1769, and then in 1877 by German pathologists Zenker and Ziemssen published a series of 27 patients. Following the publication of this study, the pharyngeal pouch has been called the Zenker's diverticulum (1,2).

The Zenker's diverticulum is an acquired condition and is not a true diverticulum (pseudodiverticulum), and only consist of the mucosa and submucosa layers of the posterior wall of the hypopharyngeal-esophageal component. Zenker's diverticulum should be considered in patients with symptoms such as dysphagia, regurgitation

of undigested food, turbulence sound, chronic cough, weight loss and halitosis. The diagnosis is usually made by barium esophagography and endoscopy. The treatment of the Zenker's diverticulum can be performed in two approaches, endoscopic and open surgery. In this study, we aimed to evaluate the results of surgical treatment of 10 patients who were operated with Zenker's diverticulum diagnosis in our clinic.

MATERIAL and METHODS

Ten patients who diagnosed as Zenker's diverticulum and underwent surgery between January 2013 and 2018 were included in this study. Patients were evaluated according to age, gender, symptoms, duration of symptoms, preoperative diagnostic methods, co-morbid diseases, ASA score (American Society of Anesthesiologists), diverticulum size, surgical technique, duration of surgery, oral feeding, postoperative complications, hospitalization, improvement of symptoms and recurrence rate. All patients were operated under general anesthesia. Patients were intubated in the reverse trendelenburg position to reduce the risk of aspiration. The diverticulum was found

Received: 02.07.2018 Accepted: 13.08.2018 Available online: 07.09.2018

Corresponding Author: Bunyamin Gurbulak, Istanbul Training and Research Hospital, Department of General Surgery, Istanbul, Turkey

E-mail: bgurbulak@gmail.com

with a 10 cm incision parallel to the medial part of the left sternocleidomastoid muscle in cervical region. After the diverticulum was dissected from the surrounding tissues, diverticulectomy was performed with the help of cricophrengeal myotomy and staples. Hemovac drain was used for drainage of operation region. On the first postoperative day, water and liquid foods were started. On the third day, semi-solid foods were started and according to the patients' comorbidities, they were discharged in 4-14 days. A well written informed consent was obtained from all patients included in this study.

RESULTS

Nine of the patients were male and one female and the median age was 67.5 (47-77) years. Dysphagia, odynophagia, weight loss and coughing were common symptoms. The mean duration of symptoms were 16 (3-84) months. One of the patients had partial laryngectomy due to laryngeal tumor. All patients underwent diverticulectomy and cricopharyngeal myotomy. The median diverticulum size was 3.55(1.7-5.5) cm .The median duration of hospitalization was 7 (4-14) day. The median follow-up period of the patients was 19(6-26) months. Nine patients (90%) had complete improvement in their symptoms. A recurrence was detected in the control endoscopy at sixth month of the patient who was operated on because of laryngeal tumor. The patient was reoperated 19 months later with the ear nose throat (ENT) team. Demographic characteristics, ASA score, follow-up periods of patients who were operated on due to Zenker diverticulum were showed in Table 1.

Patients	Age	Gender	ASA Score	Symptom	Follow-up	Follow-up period(Monts)
1	69	M	2	Dysphagia	Disease-free	13
2	62	M	2	Dysphagia	Disease-free	20
3	72	M	2	Dysphagia	Disease-free	6
4	49	M	1	Odynophagia	Disease-free	22
5	77	M	3	Chronic cough	Disease-free	19
6	68	M	2	Dysphagia	Disease-free	18
7	47	M	1	Dysphagia	Disease-free	15
8	53	F	1	Dysphagia	Disease-free	26
9	74	M	3	Weight loss	Recurrence	23
10	67	M	1	Odynophagia	Disease-free	24

The dysphagia score of World Health Organisation was used to assess the degree of dysphagia (Table 2). The

most frequently described symptoms of the patients were dysphagia, odynophagia, chronic cough and weight loss according to frequency.

Dysphgia scale	Stage	Before surgery	After surgery (1. Mounth)	After surgery (6. mounth)
Normal	0	0	10	9
Difficulty in solid food	I	4	0	0
Inability to swallow solid foods	II	4	0	0
Inability to swallow of chopped food	III	2	0	0
Puree and cream can not be swallowed	IV	0	0	0
Liquid and saline can not be swallowed	V	0	0	0

The symptoms of patients spreading over a wide range of time changes from 3 months to 7 years, and the median duration was 16 months. All patients were diagnosed with endoscopy. Barium esophagography was performed in addition to endoscopy for 5 patients. According to barium esophagography the largest diameter of the diverticulum varied between 5.3 to 10.5 cm. The size of the diverticules ranged from 1.7 to 5.5 cm in pathological examination. Computerized tomography (CT) of neck was used for the evaluation of the patient who underwent surgery for laryngeal tumor and had diverticulum. Barium esophagography and CT images of Zenker diverticulum were shown figure 1 and 2. The Body Mass Index of the patients varied between 18-40 kg/m², with a median of 20.85 kg/m². One patient was morbid obese. Two of the patients had advanced chronic obstructing pulmonary disease (COPD). As a result of consultations on pulmonary medicine, they use inhaler treatment for a long time before and after the operation. There were no complications related to hemorrhage, wound infections and surgery that would extend the hospitalization.

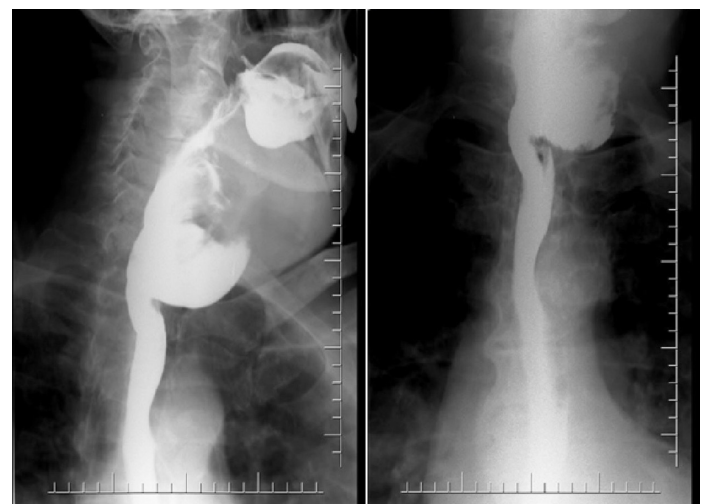


Figure 1. Barium esophagography of Zenker diverticulum

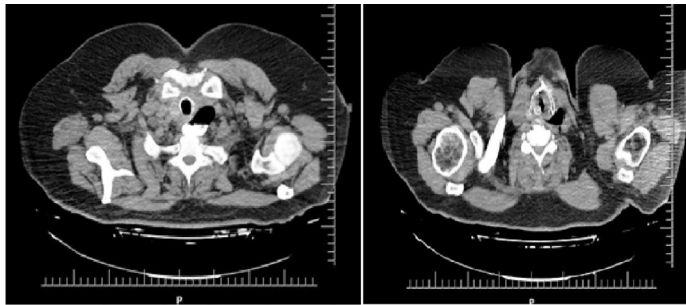


Figure 2. CT images of Zenker diverticulum

DISCUSSION

There are some theories that try to explain the formation of pulsion type diverticula of the esophagus. These theories usually focus on structural and physiological disorders of the cricopharyngeal muscle. Anagiotos A. and his colleagues have reported that the Killian triangle between the oblique fibers of the pharyngeal constrictor muscle and the horizontal running fibers of the cricopharyngeal sphincter plays an important role in the anatomic weakness and the appearance of the diverticulum (3,4). Cook et al. using videoradiography and manometry methods, found that patients with diverticula during food passages had higher pressures than healthy subjects, and that the reduction in upper esophageal opening was due to the disease (5).

Zenker's diverticulum are rare before the age of 40 and generally more common over 70 years and in men (6). The vast majority of Zenker's diverticula extend to the left. Only 10% is localised on the right. Anatomically, this can be explained by the potential gap between the concave of the cervical esophagus and the left carotid artery (7). In our study, the median age of our patients was 67.5 and there was no patient under 40 years old. Again, according to the surgical findings of our patients, it was seen that diverticula localised in the left and posterior side in all patients. Surgical images of cricomyotomy and Zenker diverticulum were shown in Figure 3 and 4.

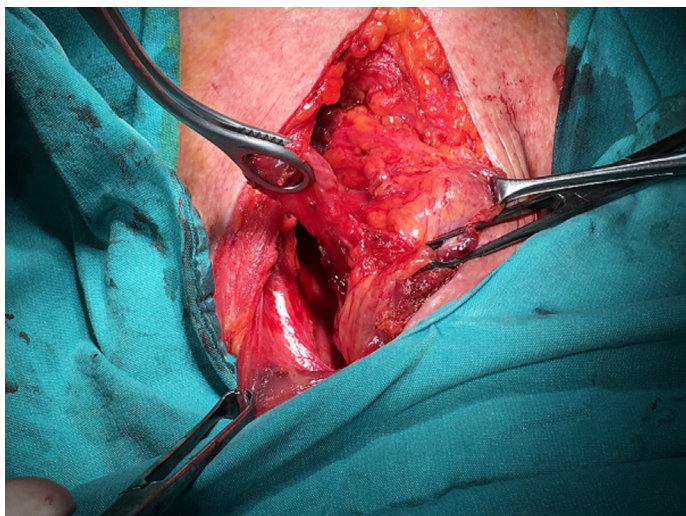


Figure 3. Surgical image of Zenker diverticulum

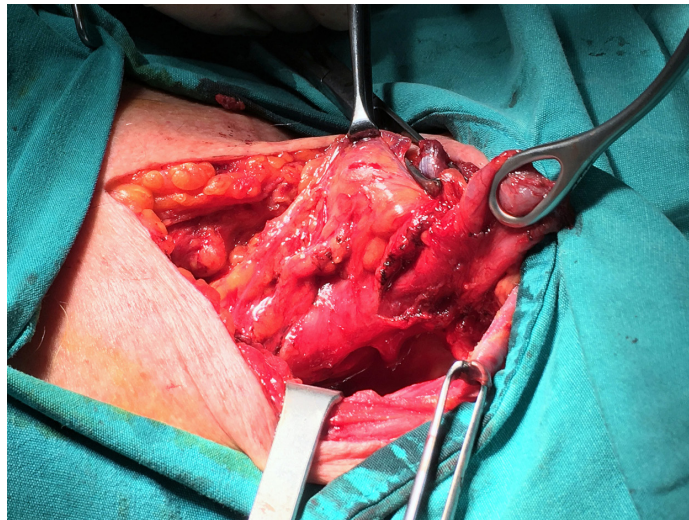


Figure 4. Surgical image of cricomyotomy and Zenker diverticulum

The severity of the symptoms is directly proportional to the size of the diverticulum and can lead to malnutrition in patients. The duration of symptoms during admission may vary from week to years (8). Clinically, there is usually no feature on examination, but rarely, palpation may cause a swelling that is accompanied by vocalization (Boyce sign). Barium esophagography and endoscopy were used to investigate the dysphagia caused by the Zenker's diverticulum. The Zenker's diverticulum can be easily diagnosed by the barium esophagography, which is easily applied and demonstrates the boundaries of the diverticula (9). Despite endoscopy has direct observation and tissue sampling, there is a risk of perforation of diverticulum due to the endoscopy.

Zenker's diverticulum can accompany much pathology. Resouly A. and his colleagues described 20 patients with surgically treated Zenker's diverticulum as having esophageal motility disorder and most of them gastroesophageal reflux disease (10). Rizzetto et al. showed that gastroesophageal reflux / hiatus hernia accompanied the Zenker's diverticulum in 30 (23.4%) out of 128 patients (11). In our study, only 1 patient had hiatal hernia. The Brombart classification is the most commonly used to grade the dimensions of the Zenker's diverticulum by barium esophagography (9).

The changes in the surgical treatment of the Zenker's diverticulum are evolutionary. The initial two-stage operation was later abandoned in favor of a single-stage operation. Cricopharyngeal myotomy has been introduced since it has been recognized that the cricopharyngeal muscle plays a major role in the pathogenesis of diverticula formation and in the development of symptoms. At present there is no consensus on the length of myotomy (12).

Lerut et al. suggested a 5 cm myotomy based on the histological abnormalities extending beyond the cricopharyngeal margin and extending to the striated muscle of the upper esophagus (13). Skinner and Zuckerbraun's experience with the recurrent Zenker's diverticulum indicated that the most important cause of

early recurrence was inadequate myotomy (14). However, in a study involving 888 patients by Mayo clinic, it was stated that myotomy-assisted diverticulectomy did not shown to contribute to healing (15).

In addition, Colombo-Benkman and colleagues emphasize that the fact that in the presence of hypertrophy of the cricopharyngeal muscle fibers, there is no difference between the patients who underwent diverticulectomy and myotomy and only diverticulectomy. They suggested the myotomy should be performed in selected cases (16).

When the review of literature including 2826 patients of 41 studies, it was seen that up to 7 different surgical techniques were applied and the most frequently diverticulectomy and cricopharyngeal myotomy were performed (12). Intraluminal approach with minimally invasive technique and diverticulotomy and myotomy were performed by Dolhman in 1960 and this technique is being applied increasingly (16). Van Overbeek JJ and colleagues reported that 90% of patients achieved good results with this technique (18).

In another study conducted by Van Overbeek JJ. emphasize that this technique is the easiest and most reproducible approach when compared to open surgery (19). Bonavina and his colleagues compared transoral endostapler technique (n = 181) with open stapler resection and cricopharyngeal myotomy (n = 116). The endostapler techniques have some advantages such that the duration of operation, hospitalization and the time of oral feeding were shorter when compared to other techniques. As well as, complications such as leakage from the stapler line and recurrent laryngeal nerve damage were not observed. The 92% of the patients who underwent endostapler were asymptomatic during the 27-month follow-up period and 94% of the patients who underwent open-surgery were asymptomatic during the 48-month follow-up period. It is concluded that the endostapler approach is as safe and effective as the open surgical approach (20). The dimension of the diverticulum is important for which approach to choose.

The limits of endoscopic approach in large sized diverticulum is because of it leaves a wide segment of the unfunctional esophagus and this increase the complication rate and in small sized diverticulum is exploration problems. A surgical approach is recommended like these situations (21,22).

In postoperative period, bleeding, hematoma, abscess, emphysema, wound infection, leakage; esophageal fistula, pneumomediastinum, mediastinitis, esophageal stenosis, dysphagia, regurgitation, persistent diverticulum, mediastinal irritation, chest pain, temporary or permanent recurrent laryngeal nerve paralysis and change of voice can be seen. When stapler was used, in some patient may be seen major and minor complications such as a foreign body sensation in the throat and may require revision surgery.

In literature, fistula development after diverticulectomy and myotomy was reported between 2.1% and 15.4%.

In our series, we used a white-tipped endostapler for all patients, diverticulotomy and cricopharyngeal myotomy performed about 5 cm. None of our patients had fistula, recurrent nerve injury, hematoma and wound infection. We compared only 1 (10%) patients with recurrence, this patient had previously undergone subtotal laryngectomy due to laryngeal tumor and this may be the cause of recurrence.

CONCLUSIONS

As a result, the Zenker's diverticulum is a structural pathological condition that affects the quality of life of the patient and must be treated. Despite the increasing use of intraluminal endoscopic approach in the treatment of symptomatic Zenker's diverticula, surgical approach maintains its importance in relation to diverticula size. Accepted surgical approach is diverticulectomy with cricopharyngeal myotomy with low morbidity, mortality and recurrence rates.

Competing interests: The authors declare that they have no competing interest.

Financial Disclosure: There are no financial supports

Ethical approval: This work has been approved by the Institutional Review Board.

REFERENCES

1. Ludlow A. A case of obstructed deglutition from a preternatural dilatation of and bag formed in the pharynx. *Med Observ Inq Soc Phys* 1769;3:85-101.
2. Zenker FA, von Ziemssen H. *Krankheiten des Oesophagus*. In: von Ziemssen H (ed) *Handbuch der Speciellen Pathologie und Therapie* Vogel, Leipzig 1874;7:1-87.
3. Killian G. Ueber den Mund der Speiseröhre. *Zeitschrift für Ohrenheilkunde und für die Krankheiten der Luftwege* 1908;55:1-41.
4. Anagiotos A, Preuss SF, Koebke J. Morphometric and anthropometric analysis of Killian's triangle. *Laryngoscope* 2010;120:1082-8.
5. Cook IJ, Gabb M, Panagopoulos V, et al. Pharyngeal (Zenker's) diverticulum is a disorder of upper esophageal sphincter opening. *Gastroenterology* 1992;103:1229-35.
6. Maran AG, Wilson JA, Al Muhanna AH. Pharyngeal diverticula. *Clin Otolaryngol Allied Sci* 1986;11:219-25.
7. Westrin KM, Ergun S, Carlsöö B. Zenker's diverticulum - a historical review and trends in therapy. *Acta Otolaryngol* 1996;116:351-60.
8. Bowdler DA. Pharyngeal pouches. In: Kerr A, ed. *Scott Brown's Textbook of Otorhinolaryngology*. 6th ed. Oxford: Butterworth-Heinemann 1997:1-21.
9. Teke Z, Bostancı EB, Aksoy E, et al. Surgical treatment of Zenker's diverticulum. *Turkish journal of Surgery* 2010;26:73-8.
10. Resouly A, Braat J, Jackson A, et al. Pharyngeal pouch: link with reflux and oesophageal dysmotility. *Clinical Otolaryngology and Allied Sciences* 1994;19:241-2.
11. Rizzetto C, Zaninotto G, Costantini M, et al. Zenker's diverticula: feasibility of a tailored approach based on diverticulum size. *J Gastrointest Surg* 2008;12:2057-64.
12. Yuan Y, Zhao YF, Hu Y, et al. Surgical Treatment of Zenker's Diverticulum *Dig Surg* 2013;30:207-18.
13. Lerut T, van Raemdonck D, Guelinckx P, et al. Zenker's diverticulum: is a myotomy of the cricopharyngeus useful? How long should it be? *Hepatogastroenterology* 1992;39:127-31.

14. Skinner KA, Zuckerbraun L. Recurrent Zenker's diverticulum. Treatment with cricopharyngeal myotomy. *Am Surg* 1998;64:192-5.
15. Payne WS. The treatment of pharyngoesophageal diverticulum: the simple and complex. *Hepatogastroenterology* 1992;39:109-14.
16. Colombo-Benkmann M, Unruh V, Krieglstein C, et al. Cricopharyngeal myotomy in the treatment of Zenker's diverticulum. *J Am Coll Surg* 2003;196:370-7.
17. Dohlman G, Mattsson O. The endoscopic operation for hypopharyngeal diverticula: a roentgen cinematographic study. *AMA Arch Otolaryngol* 1960;71:744-52.
18. van Overbeek JJ, Hoeksema PE, Edens ET. Microendoscopic surgery of the hypopharyngeal diverticulum using electrocoagulation or carbon dioxide laser. *Ann Otol Rhinol Laryngol* 1984;93:34-6.
19. Van Overbeek JJ. Meditation on the pathogenesis of hypopharyngeal (Zenker's) diverticulum and a report of endoscopic treatment in 545 patients. *Ann Otol Rhinol Laryngol* 1994;103:178-85.
20. Bonavina L, Bona D, Abraham M, et al. Long-term results of endoscopic and open surgical approach for Zenker diverticulum. *World J Gastroenterol* 2007;13:2586-89
21. Ozgursoy OB, Salassa JR. Functional and manofluorographic outcomes after transoral endoscopic pharyngoesophageal diverticulostomy. *Arch Otolaryngol Head Neck Surg* 2010;136:463-7.
22. Gutschow CA, Hamoir M, Rombaux P, et al. Management of pharyngoesophageal (Zenker's) diverticulum: which technique? *Ann Thorac Surg* 2002;74:1677-82.