

Correlation of stability and complications measurements in traumatic hip dislocation cases associated with posterior wall acetabular fracture

Ali Gulec, Sadettin Ciftci

Selçuk University Faculty of Medicine Department of Orthopaedics and Traumatology, Konya, Turkey

Copyright © 2018 by authors and Annals of Medical Research Publishing Inc.

Abstract

Aim: To evaluate the relationship between stability criteria and complications in traumatic hip dislocations associated with posterior acetabular wall fracture.

Material and Methods: The study retrospectively investigated 18 patients treated for posterior acetabulum fracture dislocation in the orthopedics and traumatology clinic from 2014-2017. All patients had wall defect, acetabular fracture index and coronal posterior acetabular arc angle (PAAA) assessed. Fracture types were determined according to Letournel's definitions.

Results: Preoperative radiological tests found the mean width of intact hip wall was 33.8 mm (range 31-39 mm), mean wall length in fracture hips was 13.7 mm (range 5-21 mm), and mean wall defect was measured as 59.1% (range 37.5-86%). When intact hips were assessed mean coronal PAAA was 54.2 degrees (range 41-65). For fractured hips, coronal PAAA was 18.2 degrees mean (range 6-29). Acetabular fracture index (AFI) was determined as mean 40.8 (range 14-62.5). Regarding complications in the postoperative period, one patient had avascular necrosis of the femoral head and 9 patients had osteoarthritis.

Conclusion: Though Defect percentage, AFI and coronal PAAA values are important proven markers for stability, in our study there was no correlation identified with complications.

Keywords: Acetabular Fracture; Hip Dislocation; Posterior Acetabular Arc Angle; Kocher Langenbeck Approach.

INTRODUCTION

Acetabulum fractures occur in 2-3 people per 100,000 population (1,2). Posterior wall fractures represent 25% of acetabulum fractures (1-3). Dislocations with acetabulum fractures are most often seen as posterior fracture dislocations and represent 64% of all posterior fracture dislocations (4). This clinical situation develops was linked to high energy trauma. Among instability criteria, wall defects involving the posterosuperior acetabulum form more than 50% of situations, with fracture index above 34% (5-7).

Another method determining posterior instability risk is assessment of the posterior acetabular arc angle (PAAA). This angle is assessed vertically in a study and assessed coronally in another study (8,9). Coronal PAAA was determined as a reliable method to determine posterior acetabular fracture dislocation risk without requiring hip evaluation. Coronal PAAA of more than 77 degrees is

stable, while angles lower than 50 degrees are reported as instability (8).

Among the main complications developing after acetabulum fractures, arthrosis, avascular necrosis and limitation of joint movements may be listed. For traumatic joint dislocations, redislocations or subluxations, instability and nerve damage may be added to this event.

Predicting these complications which affect quality of life severely is important to inform the patient and also to reduce these complications to a minimum.

This study compared the general demographic data and clinical outcomes of patients with radiological instability criteria like coronal PAAA, acetabular fracture index and wall defect in 18 operated hips to determine whether there are any correlations with complications.

MATERIAL and METHODS

After receiving relevant permission from Local ethics

Received: 20.09.2018 Accepted: 25.09.2018 Available online: 05.10.2018

Corresponding Author: Ali Gulec, Selçuk University Faculty of Medicine Department of Orthopaedics and Traumatology, Konya, Turkey, E-mail: drag42@gmail.com

committee, the study retrospectively investigated 35 patients treated for posterior acetabulum fracture dislocation in the Orthopedics and Traumatology Clinic of Faculty of Medicine from 2014-2017. The study included all patients treated for isolated posterior acetabulum fracture dislocation developing after acute trauma.

Additional posterior column fracture, femoral head fracture, femoral neck fracture but patients with additional interventions were excluded from the study. Additionally, one patient with bilateral posterior acetabulum fracture dislocation without the ability to determine wall defect was also excluded from the study. A total of 18 patients were included in the study.

For all the patients Kocher-Langenbeck approach was chosen to treat posterior wall injury (10). All the patients were determined to have been administered 25 mg indomethacin prophylaxis 3 times per day to protect against heterotopic ossification (11,12). The general demographic data, fracture types, blood transfusion amount, and complications (avascular necrosis, arthrosis, arthroplasty requirements, neurological injury, infection, mortality) were investigated. Additionally, all patients had wall defect, acetabular fracture index and coronal PAAA assessed (Figure 1). Fracture types were determined according to Letournel's definitions (13). Wall defect was investigated by calculating the width of the intact posterior acetabulum wall (Figure 2).

Coronal PAAA was assessed as described by Harnroongroj et al. (8) (Figure3).

The correlations between wall defect, acetabular fracture index and coronal PAAA with complications were statistically assessed. For statistical assessment, SPSS (Statistical Package for Social Sciences) software (Version 21.0; SPSS Inc, Chicago, IL) was used. In comparisons chi-square test was used.

and one patient had two units of blood transfusion. According to preoperative radiological evaluations the mean width of intact hip wall was 33.8 mm (range 31-39 mm), the mean wall length in fracture hips was 13.7 mm (range 5-21 mm), and the mean wall defect was measured as 59.1% (range 37.5-86%).

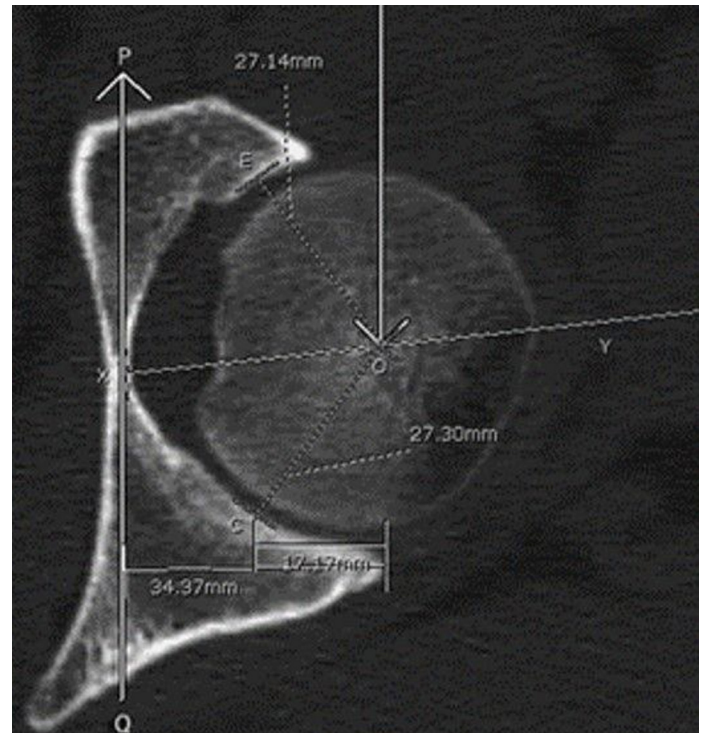


Figure 2. The photograph of computed tomography imaging intact posterior wall (8).

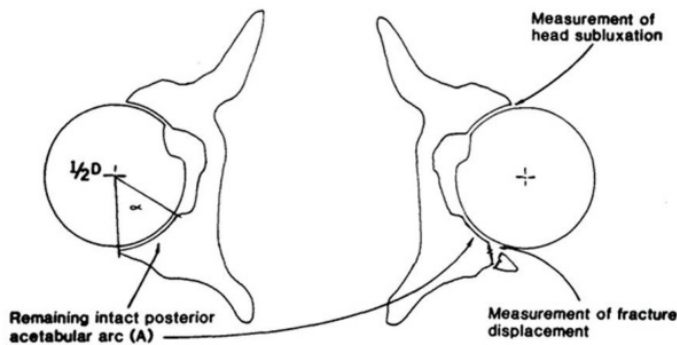


Figure 1. Posterior acetabular Arc Angle (5).

RESULTS

Of the 18 patients included in the study, 3 were females and 15 were males. Mean age was determined as 37.7 years (range 14-48). Seven patients were injured in motor vehicle induced pedestrian accidents, 1 patient had a simple fall and 10 patients were injured by motor vehicle accident. All patients were taken for surgery after preoperative X-ray and tomography tests when general status was stable.

During the perioperative process one patient had 3 units

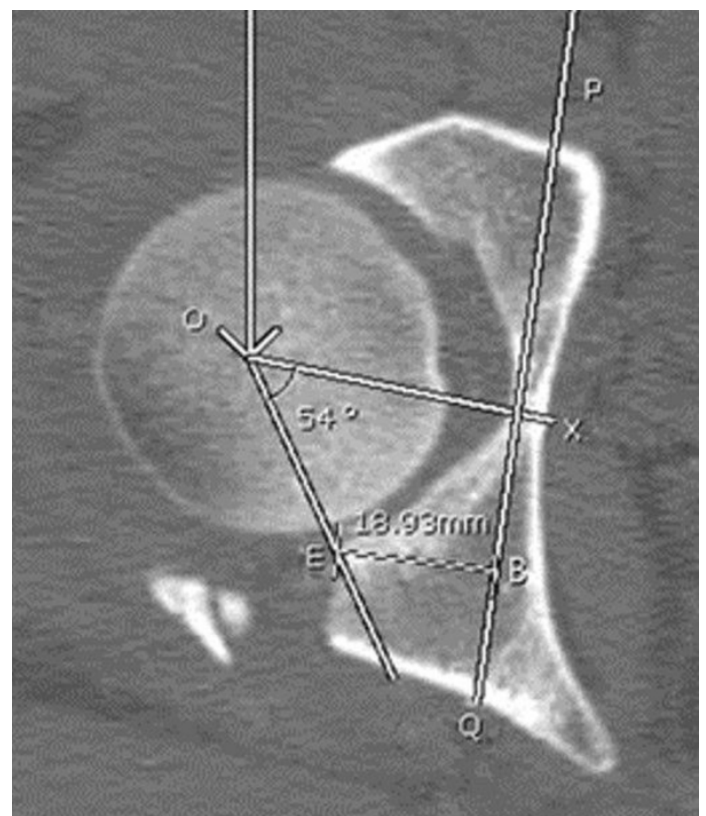


Figure 3. The photograph of computed tomography imaging Coronal PAAA (9).

When intact hips were assessed mean coronal PAAA was 54.2 degrees (range 41-65).

For fractured hips, coronal mean PAAA was 18.2 degrees (range 6-29). (Acetabular fracture index (AFI) was determined as mean 40.8 (range 14-62.5) (Table 1).

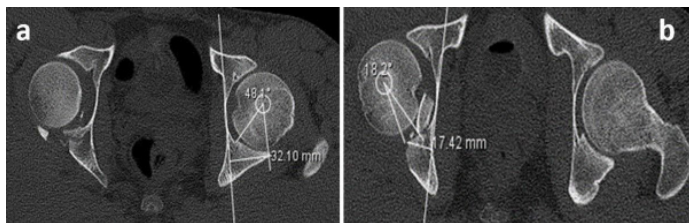


Figure 4a, b. The preoperative measurements. The photograph of computed tomography imaging intact (a) and fracture (b) posterior wall in our case.

When complications identified in the postoperative period were investigated, one patient had femoral head avascular necrosis which did not require surgery. No patient had infection. Three patients were observed to have continued

sciatic nerve field which was present preoperatively. One patient had primary total hip arthroplasty administered due to developing arthrosis. A total of 9 patients developed osteoarthritis with 4 patients in stage 2, 3 patients in stage 3 and 2 patients in stage 4. However, it was determined that only 1 patient was treated with arthroplasty due to arthrosis.

The statistical correlations between preoperative radiological parameters and complications were investigated. The chi-square test was used for statistical analysis of whether AFI, defect percentage and coronal PAAA predicted complications were not identified with a statistically significant correlation ($p=0.225$). Additionally, according to the AFI cut-off value of 42 was determined for our patients, there was no significant correlation between arthrosis and avascular necrosis identified above and below this value ($p=0.412$). Similarly, there was no significant correlation identified between the cut-off values determined for coronal PAAA and acetabular wall length in the fractured hip in terms of arthrosis and avascular necrosis ($p=0.162-0.410$).

Table 1. Demographic data and radiological measurements

	Age	Gender	PAAA (Intact)	PAAA (Fracture)	Posterioracetabular wall (Intact)	Posterioracetabular wall (Fracture)	Arthrosis	Femoralavascular necrosis
1	55	f	54	17	32mm	12mm	absent	absent
2	58	m	60	6	36mm	5mm	absent	absent
3	54	m	57	9	35mm	14mm	present	absent
4	32	m	54	18	32mm	9mm	absent	absent
5	55	m	65	20	39mm	16mm	present	present
6	23	m	51	19	31mm	14mm	absent	absent
7	31	m	62	25	37mm	9mm	absent	absent
8	45	f	55	15	31mm	13mm	present	absent
9	18	m	52	29	32mm	20mm	absent	absent
10	33	m	50	21	37mm	11mm	present	absent
11	22	m	58	10	35mm	10mm	present	absent
12	42	m	51	18	31mm	17mm	present	absent
13	55	m	51	13	35mm	13mm	present	absent
14	14	m	48	18	32mm	17mm	absent	absent
15	15	m	53	23	32mm	17mm	absent	absent
16	46	m	63	21	36mm	12mm	present	absent
17	84	f	41	18	32mm	16mm	present	absent
18	36	m	51	28	34mm	21mm	absent	absent

PAAA: Posterior acetabular arc angle

DISCUSSION

Preoperative assessment of posterior hip fracture dislocations is important in terms of planning treatment but difficult due to the complicated anatomical structure (9). After these injuries there are many factors affecting outcomes (14,15). Briffa et al. in a 257 case-series determined these factors as advanced age, reduction quality, some fracture types and delayed surgery for 45

cases with moderate and poor outcomes (16). Acetabulum fractures are generally encountered in young adult patients and are generally associated with bad functional outcomes and disability (15,17-19). A meta-analysis published by Giannoudis investigated 3670 cases stated that the most common complication was osteoarthritis and this complication occurred in nearly 20% of patients (14). The most common complication in our cases was determined as arthrosis and had a nearly 50% rate. At first glance

the osteoarthritis complication rate may be considered very high, but this rate was determined by considering all radiographic arthrosis degrees. Considering only 1 patient required arthroplasty due to arthrosis, the osteoarthritis complication rate with clinical findings appears to be 5%. However, due to the short follow-up duration, the number of patients with radiographic osteoarthritis requiring arthroplasty could not be predicted so an accurate rate cannot be given. Additionally, we believe this low rate is due to closed reduction performed within the first 3 hours and surgical treatment within the first 24 hours. An article published by Murphy et al. associated advanced age, bad reduction, local complications and heterotopic ossification with poor outcomes and determined that gender, presence of dislocation and sciatic nerve injury were factors not directly associated with poor outcomes (20).

In our retrospective study, there was no statistical correlation identified between bad outcomes and preoperative radiological assessment parameters. We believe this situation may be related to the limited case numbers and that these types of injuries may be a factor on their own.

Before computed tomography (CT), the best assessment was performed with Judet radiography (5). However, direct radiography does not clearly reveal fracture structure, size, and presence of fragments within the joint and is insufficient to plan treatment. CT can take the normal hip as reference to determine fracture fragment percentage and performs more quantitative assessment (6,21). In addition to quantitative assessment, the coronal PAAA value provides quantitative information without assessing the other hip to evaluate the stability of posterior acetabulum fracture dislocations (8). A study by Keith et al. reported that if fracture fragments are less than 20% (defect percentage) of the normal acetabular depth, the hip was stable and did not require intervention. In our cases, the acetabular defect percentage was determined to be minimum 39% and all hips were unstable and were patients admitted to the emergency service with hip fracture dislocations. Harnroongroj et al. reported that in addition to this assessment, coronal PAAA values were beneficial to predict stability without requiring assessment of the normal hip (8,9). Investigations by Harnroongroj et al. found coronal PAAA values of more than 77 degrees instable hips, while hips with less than 50 degrees were unstable (8). In our cases, coronal PAAA values were investigated. According to the investigation, maximum PAAA value was 29, lower than 50 degrees in all cases. Considering that all of our cases were unstable and their injuries requiring surgery, this situation complies with the literature. Calkins investigated the acetabular fracture index and stated that with acetabular fracture index less than 34.3% no hip was stable, and with index more than 55.2% no hip was unstable. When this situation is calculated as defect percentage, hips with defect more than 65.7% are unstable, while hips with defects less than 44.8% are stable. For our cases the AFI value was determined as 62.5 for one patient. Though this situation

is higher than the 55.2% stated by Calkins, it represents an unstable hip. All our measurements were performed by the same orthopedist, but this is acceptable considering there may be intraobserver variation observed in measurements over time.

Another important point when our patients are investigated is whether measurements have predictive value in terms of complications. However, statistical assessment did not reach a significant conclusion for this topic. This situation may be related to the most serious limitation of the study of the low number of cases. Apart from the low number of cases, the retrospective nature of the study and the patients from very different age groups are other limitations leading to different susceptibility to complications.

CONCLUSION

Posterior acetabulum fracture dislocations are associated with high radiological complication rates. The importance of early closed reduction for these injuries is known. Additionally, though defect percentage, AFI and coronal PAAA values are important and proven markers for stability, in our study there was no correlation identified with complications. However, we believe prospective studies with higher case numbers will obtain more accurate results.

Competing interests: The authors declare that they have no competing interest.

Financial Disclosure: There are no financial supports

Ethical approval: Before the study, permissions were obtained from local ethical committee.

REFERENCES

1. Ahmed M, Abuodeh Y, Alhammoud A, et al. Epidemiology of acetabular fractures in Qatar. *Int Orthop* 2018;42:2211-7.
2. Laird, A. and J. Keating, Acetabular fractures: a 16-year prospective epidemiological study. *The Journal of bone and joint surgery. Br* 2005;87:969-73.
3. Moed BR, SEW Carr, SE, Watson MS, et al. Open reduction and internal fixation of posterior wall fractures of the acetabulum. *Clinical Orthopaedics Relat Res* 2000;377:57-67.
4. Larson, CB, Carroll, B. Fracture dislocations of the hip. *Clinical Orthopaedics and Related Research* 1973;92:147-54.
5. Calkins, M.S., et al., Computed tomography evaluation of stability in posterior fracture dislocation of the hip. *Clin orthop Relat Res* 1988;227:152-63.
6. Keith JE Jr, Brashear HR Jr, Guilford WB. Stability of posterior fracture-dislocations of the hip. Quantitative assessment using computed tomography. *J Bone joint Surgery Am* 1988;70:711-4.
7. Moed BR, Ajibade DA, Israel H. Computed tomography as a predictor of hip stability status in posterior wall fractures of the acetabulum. *J Orthopaedic Trauma* 2009;23:7-15.
8. Harnroongroj T, Purinon S, Theerawoot T, et al. Posterior acetabular arc angle of the femoral head assesses instability of posterior fracture-dislocation of the hip. *Int Orthop* 2013;37:1141-5.
9. Harnroongroj H, Kongkhet R, Narumol S, et al. Posterior acetabular arc angle of unstable posterior hip fracture-dislocation. *Int Orthop* 2013;37:2443-9.

10. P Suryanarayan, AR Kesavan, Surgical approaches to the acetabulum. *Indian J Orthop* 2002;36:17-9.
11. Moed, B.R. and D.E. Karges, Prophylactic indomethacin for the prevention of heterotopic ossification after acetabular fracture surgery in high-risk patients. *Jof Orthop Trauma* 1994;8:34-9.
12. Jimenez, M.L. and M.S. Vrahas, Surgical approaches to the acetabulum. *Orthopedic Clinics* 1997; 28:419-34.
13. Letournel, E, Acetabulum fractures: classification and management. *Orthopedic Trauma Directions* 2007;5:27-33.
14. Giannoudis PV, Grotz MR, Papakostidis C, et al, Operative treatment of displaced fractures of the acetabulum: a meta-analysis. *J Bone Joint surg Br* 2005;87:2-9.
15. Giannoudis PV, Nikolaou VS, Kheir E, et al, Factors determining quality of life and level of sporting activity after internal fixation of an isolated acetabular fracture. *J Bone Joint surg Br* 2009;91:1354-9.
16. Briffa, N, Pearce R, Hill AM, et al., Outcomes of acetabular fracture fixation with ten years' follow-up. *J Bone Joint surg Br* 2011;93:229-36.
17. Giannoudis PV, Tzioupis C, Moed BR. Two-level reconstruction of comminuted posterior-wall fractures of the acetabulum. *J Bone Joint surg B* 2007;89:503-9.
18. Rommens PM, MV Giménez, MH Hessmann. Is the posterior wall avulsion the simplest acetabular fracture? *Eur J Trauma* 2000;26:144-54.
19. Beaulé PE, Dorey FJ, Matta JM, Letournel classification for acetabular fractures: assessment of interobserver and intraobserver reliability. *J Bone Joint Surg Am* 2003;85:1704-9.
20. Murphy D, Kaliszer M, Rice J, et al., Outcome after acetabular fracture: prognostic factors and their inter-relationships. *Injury* 2003;34:512-7.
21. Sevimli R, Bilal Ö. Proximal Femoral Nail Applications for the treatment of femur neck fractures. *Van Medical J* 2013;20:207-11.