

# Germ cell testicular tumor showing spontaneous regression

Serhan Cimen<sup>1</sup>, Ali Gunes<sup>2</sup>, Ali Beytur<sup>2</sup>, Hasan Gokce<sup>3</sup>

<sup>1</sup>Malatya Education and Research Hospital Clinic of, Urology, Malatya, Turkey

<sup>2</sup>Inonu University, Faculty of Medicine, Department of, Urology, Malatya, Turkey

<sup>3</sup>Inonu University, Faculty of Medicine, Department of, Pathology, Malatya, Turkey

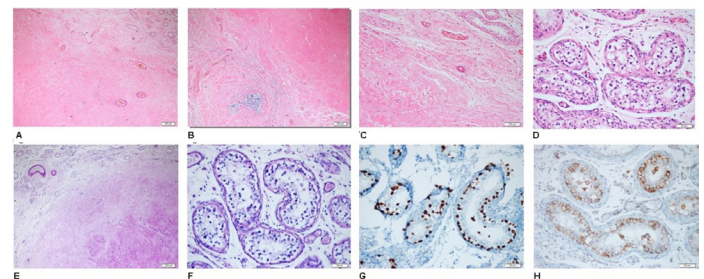
Copyright © 2018 by authors and Annals of Medical Research Publishing Inc.

## Dear Editor,

Germ cell tumors make up a large part of primary testicular tumors. Germ cell tumors of the testicle are among the most spontaneous regressing tumors (1). In the autopsy studies, approximately 1/10 of the patients who died due to metastatic germ cell tumor were observed to have completely regressed tumors (2). The majority of the tumors that have metastasized to isolated regional lymph nodes and retroperitoneal area suggest the presence of a tumor that has been regressed. In literature, primary testicular tumors regression studies have been found to be very limited (3).

Thirty-two-year-old male patient was admitted with swelling and pain in the right testicle and no mass was detected by physical examination. Lactic dehydrogenase (LDH) (269 U/L, N=125-243) levels were high in the patient's blood tests,  $\alpha$ -fetoprotein (AFP) and beta HCG values were found at normal limits. Scrotal ultrasonographic examination revealed hypoechoic nodular area of 19x9 mm at the lower pole in the left testicle parenchyma and was interpreted in favour of tumor. The patient underwent inguinal orchiectomy. Histopathological examination of testicular tissue revealed a nodular lesion of hyaline containing various diameters of vascular structures and scattered mononuclear inflammatory cell infiltration areas in the sections (Figure 1A,1B,1C,1D). It was determined that a portion of the seminiferous tubules around the lesion had increased wall thickness and contained common intracellular germ cell neoplasia areas. No sign of lymphovascular invasion was determined (Figure 1E,1F). No findings were found in favour of residual invasive tumor. When evaluated immunohistochemically, it was found that SALL-4 and CD117 staining was positive in intracellular germ cell neoplasia areas (Figure 1G,1H).

Histopathological findings diagnosed a germ cell tumor that underwent a total spontaneous regression. When the patient applied to the outpatient clinic with a pathologic result, thorax and all abdomen computed tomography revealed multiple lymph nodes in mediastinum, axillary regions and inguinal region. Follow-up and treatment are still ongoing.



**Figure A-B-C-D:** Nodular lesions of hyaline containing different diameters of vascular structures and scattered mononuclear inflammatory cell infiltration areas. (H&E X40, x100x, x200)

**Figure E-F:** Increased wall thickening and widespread IGCN areas in some of the somniferous tubules around the lesion. (PAS + x40, x200)

**Figure G-H:** SALL-4 and CD117 domains of IGCN where staining is positive. (SALL-4, CD117 X200)

The germ cell tumor, which undergo spontaneous regress of the testicle, is very rare. These patients are often diagnosed when metastatic disease is detected. The most common metastases are retroperitoneal lymph nodes. The main complaints of the patients are scrotal pain, abdominal mass and lymphadenopathy. In the studies, testicular atrophy or enduration were found in patients with testicular tumors which showed spontaneous regression (4). In our case, scrotal pain was present.

Although no pathological findings were detected

Received: 08.09.2018 Accepted: 04.10.2018 Available online: 12.10.2018

Corresponding Author: Serhan Cimen, Malatya Education and Research Hospital Clinic of, Urology Malatya, Turkey

E-mail: drserhancimen@hotmail.com

by palpation, suspicious foci were detected in 91% of the patients with ultrasonographic imaging (5). Ultrasonographic hypoechoic field was detected in our case but calcification was not accompanied.

Surgical excision of the primary focal point is recommended even in metastatic cases (6). Histopathological examination of testicular biopsy is recommended to remove the testicle even if only intralobular germ cell neoplasia (IGCN) is present (4). In our case, an orchidectomy was performed as soon as possible without a biopsy. Histopathological examination of orchidectomy materials may detect residual tumor or fibrous tissue or both components together.

Histopathologic examination of these tissues revealed that there were one or more scar tissue in the testis, accompanied by fibrosis, atrophic and hyalinized tubules, psammom, hematoxylic bodies, necrosis areas, lymphoplasmocytic infiltrates in some areas, clusters with Leydig cell, intratubular neoplasia findings in some areas, small vessels are seen after regression due to angiogenesis (7).

Balzer et al. in the study of histopathological findings, found that the most important indicator of regression is intra-tubular germ cell neoplasia as well as scar tissue (8). A large number of intracellular germ cell neoplasia was detected in our case while the nodule was not detected.

In cases of testicular tumors with spontaneous regression, extragonadal metastases are frequently seen in retroperitoneal, mediastinum, liver, lung, or regional lymph nodes (9). In our case, the involvement of regional lymph nodes (inguinal and mediastinal) as well as axillary lymph nodes that had not been previously reported in the literature was also detected.

As a result, testicular germ cell tumors are the most common malignant testicular tumor in young men, although there are other rare malignancies. Although spontaneous regression is frequently seen in these tumors, it should not be forgotten that it can be seen with

metastases in clinical practice. Even without examination, ultrasonography of suspected cases shows hypoechoic area and the accompanying calcification areas, and it causes us to think of spontaneous regression of the germ cell testicular tumor. This is important for the diagnosis and treatment by orchidectomy. In the biopsy materials, the residual tumor and/or fibroblast tissue can be identified. The presence of hematocyclic substances, tubular atrophy and intracorbular germ cell neoplasia in cases where only fibrous tissue is present should be interpreted as a germ cell tumor.

*Competing interests: The authors declare that they have no competing interest.*

*Financial Disclosure: There are no financial supports*

## REFERENCES

1. Yorukoglu K. Histopathologic prognostic factors in testicular tumors. Bull Urooncol 2011;10:91-4.
2. Bar W, Hedinger C. Comparison of histologic types of primary testicular germ cell tumors with their metastases: consequences for the WHO and the British Nomenclatures? Virchhows Arch 1976;370:41-54.
3. Kebapci M, Can C, Isiksoy S, et al. Burned-out tumor of the testis presenting as supraclavicular lymphadenopathy. Eur Radiol 2002;12:371-3.
4. Fabre E, Jira H, Izard V, et al. "Burned-out" primary testicular cancer. BJU Int 2004;94:74-8.
5. Kucukzeybek BB, Sarı A, Ermete M, et al. Metastatic retroperitoneal yolk-sac tumor case report. Turkish J Urology 2007;33:117-20.
6. Simmonds PD, Mead GM, Lee AH, et al. Orchidectomy after chemotherapy in patients with metastatic testicular cancer. Is it indicated? Cancer 1995;75:1018-24.
7. Ozluk Y. Burned-Out" Germ Cell Tumors of the Testis. Bulletin of Urooncology 2014;13:223-7.
8. Balzer B, Ulbright TM. Spontaneous regression of testicular germ cell tumors. An analysis of 42 cases. Am J Surg Pathol 2006;30:858-65.
9. Culhaci N, Erol H, Meteoglu I, et al. Burned-out testis tumor revealed by inguinal lymphadenopathy. Turkish J Urology 2009;35:263-5.