

# Surgical treatment of squamous cell cancer with anal margin localization developed on the background of condyloma acuminata: A case report

 Azmi Lale,  Mesut Yur,  Erhan Aygen

Department of Surgical Oncology, Firat University Medical Faculty Hospital, Elazig, Turkey

Copyright © 2020 by authors and Annals of Medical Research Publishing Inc.

## Abstract

We present the treatment of squamous cell carcinoma (SCC) with anal margin localization on the basis of condyloma acuminata by local excision. A 65-year-old male patient had complaints of bleeding, constipation and itching in the anal area. Physical examination revealed a 5x4 cm ulceration and an irregular mass in the anal margin localization. The incisional biopsy exposed a SCC that developed on the background of condyloma acuminata. Tumor was resected with ulcerated condyloma akumita and the skin defect was successfully repaired with V-Y plasty. In conclusion well differentiated superficial invasive anal carcinomas (T1N0) can be successfully treated by local excision.

**Keywords:** Anal cancer; condyloma acuminata; human papilloma virus; local excision; neoadjuvant chemoradiotherapy

## INTRODUCTION

Abdominoperineal Resection (APR) was the standard treatment for anal region cancers until the development of anal sphincter-preserving neoadjuvant chemotherapy and radiotherapy modalities. Currently, the recommended primary treatment for non-metastatic anal canal cancers is concurrent chemoradiotherapy. APR is now preferred for salvage treatment after neoadjuvant chemo/radiotherapy due to tumor progression or recurrence (1).

In the NCCN guideline, there are only two situations in which local excision may be preferred as the initial treatment for anal region cancers. First; superficial invasive anal SCC (T1N0) with a depth of invasion of  $\leq 3$ mm and a horizontal width of  $\leq 7$ mm with a negative surgical margin of  $\leq 2$ mm; and the second one is a well-differentiated T1N0 perianal SCC with a surgical margin of  $>1$ cm (2).

In this study, we present a case of SCC with anal margin localization on the background of condyloma acuminata which is a rare tumor and we successfully treated with local excision.

## CASE REPORT

A 65-year-old widower male patient presented to our clinic with complaints of constipation and itching in

the anal region for about 2 years, and recently minimal bleeding that caused contamination in his underwear. His medical history included hypertension and type 2 diabetes mellitus. There was no history of abdominal or anorectal disease. Physical examination revealed a 5x4 cm ulceration on the left lateral surface of the perianal region with an anal margin localization on the ulceration floor and an irregularly mass of approximately 5 mm in diameter that was not associated with the anal canal mucosa (Figure 1). No pathology was detected in the digital examination along the anal canal. Incisional biopsies were taken from the mass and histopathological evaluation was performed. The result was reported as a well-differentiated SCC developed on the background of condyloma acuminata. On immunohistochemistry, the specimen stained positive for pancytokeratin and Ki67 %45.

Serum polymerase chain reaction test revealed HPV-DNA type 16 positive. No pathological findings were detected in the procto-sigmoidoscopic evaluation. Perianal superficial ultrasonography (USG) and pelvic magnetic resonance (MR) evaluation showed that the mass was confined to subcutaneous fatty tissue and did not invade the anal sphincter or anal canal. Bilateral superficial inguinal USG and pelvic MRI showed reactive lymph nodes with the largest diameter of 11 mm in the left inguinal region.

**Received:** 04.03.2020 **Accepted:** 30.04.2020 **Available online:** 20.11.2020

**Corresponding Author:** Azmi Lale, Department of Surgical Oncology, Firat University Medical Faculty Hospital, Elazig, Turkey,

**Email:** dr.azmilale@hotmail.com

(Figure 2). PET-CT showed no hypermetabolic activity in inguinal or iliac lymph nodes, anal canal or distant organs. Fine needle aspiration biopsy of left inguinal lymph node was reported as benign cytology.

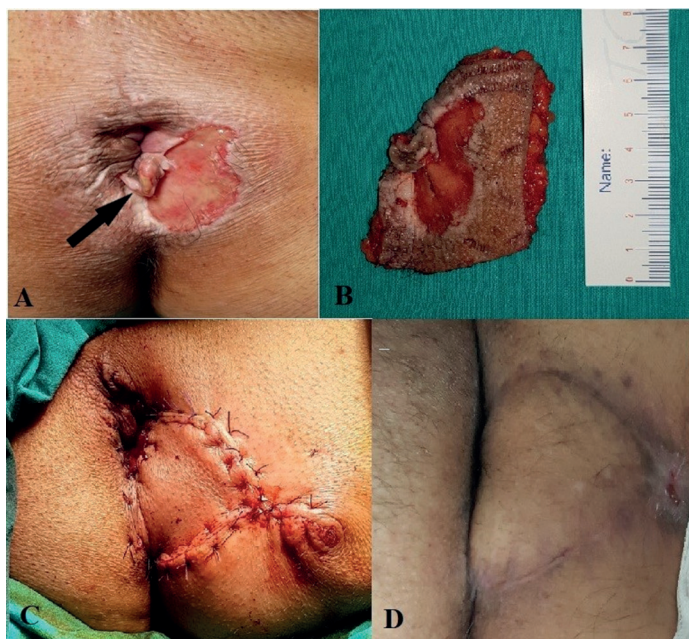


Figure 1: A: T1N0 SCC tumor with anal margin localization on the background of condyloma acuminata causing skin ulceration. B: Specimen image after resection of tumor mass with condyloma acuminata lesion. In order to obtain a negative surgical margin, the resection margins in the anal canal were extended to the dentate line. C: The skin defect was repaired by sliding the flap with V-Y plasty. Flap suturing was performed to the dentate line in the anal canal. D: Postoperative 6th month operation site.

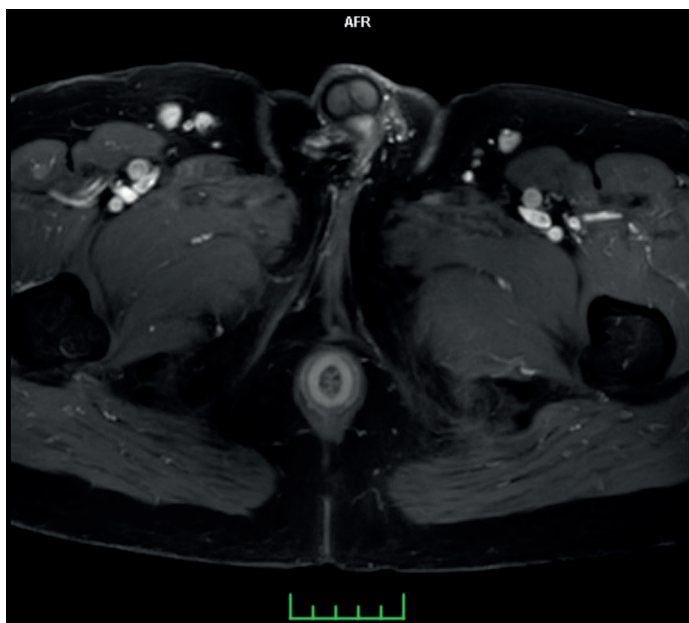


Figure 2. Pelvic MRI. The tumor with anal margin localization is not associated with internal and external sphincters. In the right inguinal superficial region, several lymph nodes with benign character can be seen.

According to AJCC 8th edition data, the patient was accepted as T1N0 and planned to undergo surgery (3).

Only preoperative fleet enema and antibiotic prophylaxis was performed before the surgery. The patient underwent surgery in the lithotomy position under general anesthesia. Mass resection and repair of the skin defect with V-Y plasty were planned as surgical procedures. With a "V" incision, perianal skin excised including ulcers taking into account tumor-free borders of at least 1 cm and anoderm was excised to the dentate line along the anal canal of the tumor site. The flap was slid medially and anastomosed to the dentate line, and the incisions were sutured to form a Y-shaped suture line. There were no complications in the early and postoperative periods. Oral feeding was started at the same day of surgery and he was discharged on the 4th day by prescribing topical trichloroacetic acid for the treatment of remaining condyloma foci after surgery in the perianal region.

Specimen histopathology was reported as a well-differentiated T1 stage SCC developed on the ground of condyloma acuminata with the nearest 12mm surgical margins. The patient was presented to the oncology council with his current findings. The decision of the council did not require chemoradiotherapy and a follow-up decision was taken. In the outpatient clinic controls there was no local recurrence, anal stenosis or gas / fecal incontinence during late follow-up. In the 6th month control superficial USG and pelvic MRI findings, no pathologic inguinal and iliac lymph nodes were detected. The patient is being followed up.

There was no colorectal-anal region cancer history or diagnosed with condyloma in the first or second-degree relatives of the patient. The patient had no sexual partner at the diagnosis or during the treatment period of the disease. So, HPV screening was not done in any of family members.

All procedures performed in this case report involving human participants were in accordance with the 1964 Helsinki declaration and its later amendments or comparable ethical standards. In this study, clinical data and surgical images of the patient were shared with the informed consent of the patient.

## DISCUSSION

Squamous cell carcinoma (SCC) located in the anal canal or perianal region is very rare and it is seen in 2.7% of all gastrointestinal system tumors and the incidence increases by 2.9% every year according to SEER data (4). It is 1.5 times higher in women than in men (5). Factors such as Human Papilloma Virus (HPV) type 16 and 18 infection, homosexual activity, history of cervical/vulvar/vaginal cancer, immunosuppression after solid organ transplantation, HIV infection, hematologic malignancies and smoking have been shown in etiopathogenesis (6). Many studies have shown a particularly strong association with HPV infection. In the current literature data, the prevalence of HPV-16/18 in anal carcinoma patients was found to be 86-97% (7).

Prognosis of anal region SCC is associated with tumor

size and lymph node metastasis. According to the SEER database, only 50% of anal carcinomas were found to be confined to the anal region at the time of initial diagnosis, with a 5-year survival of 80%. Approximately 29% of patients also have regional lymph node metastasis at the time of diagnosis, with a 5-year survival rate of about 60%. In 12% of patients, distant metastasis is also detected at the time of diagnosis, with a 5-year survival rate of 30.5% (8). Non-pelvic metastases are frequently found in the liver, lung and extra-pelvic lymph nodes (9).

Pelvic MRI may be used to evaluate the size of the tumor, depth of invasion, relationship with anal sphincters, lymphatic metastasis, and abdominal / thoracic CT imaging may be used for distant metastasis evaluation (10).

Although HPV 16/18 infection is known to be particularly associated with cervix cancer, it has also been shown to be involved in the etiopathogenesis of anal cancers. In a systematic review conducted by Hoots BE et al., the incidence of HPV infection was 71% in all invasive anal cancers, and 72% of these cases had HPV types 16 and 18 (11). These findings suggest that HPV immunization may reduce the incidence of invasive anal carcinoma. Palefsky JM et al in a study evaluating the effects of HPV vaccine in homosexual men, revealed to reduce the prevalence of invasive anal cancers (12).

Nowadays, chemoradiotherapy has taken the place of surgery as the initial treatment considering the effects and morbidities on overall survival and disease-free survival in anal region cancers. The preferred chemotherapy protocol in combination with radiotherapy is mitomycin / 5-FU or mitomycin / capecitabine (13). However, in a retrospective study performed by Chai CY et al., National Cancer Data Base, 2243 well-differentiated T1N0 invasive perianal cancer cases showed no significant difference between the 5-year overall survival of the patients who had undergone surgery or chemotherapy as the initial treatment (85.3% for local excision; 86, 8% for chemoradiotherapy) (14). When treatment alternatives were compared, it was found that patients treated with local excision were less costly (15).

## CONCLUSION

In conclusion, well differentiated superficial invasive anal carcinomas can be successfully treated by local excision. HPV infection has a profound effect on the etiopathogenesis of anal region cancer and the incidence of the disease can be reduced by HPV immunization.

*Competing interests: The authors declare that they have no competing interest.*

*Financial Disclosure: There are no financial supports.*

*Patient informed consent: Written informed consent was obtained from patient who participated in this study.*

## REFERENCES

1. Scholefield J, Church J. Malignant tumors of the anal canal and anus. In: Keighley M, Williams N, eds. 3rd ed. Surgery of the Anus, Rectum and Colon. Philadelphia, PA: Saunders; 2007.p.567–90.
2. Benson AB, Venook AP, Al-Hawary MM, et al. Anal Carcinoma, Version 2.2018, NCCN Clinical Practice Guidelines in Oncology. J Natl Compr Canc Netw 2018;16:852-71.
3. Amin MB, Edge SB, Greene FL, et al, eds. AJCC Cancer Staging Manual. 8th ed. New York: Springer; 2017.
4. Shiels MS, Kreimer AR, Coghill AE, et al. Anal Cancer Incidence in the United States, 1977-2011: Distinct patterns by histology and behavior. Cancer Epidemiol Biomarkers Prev 2015;24:1548-56.
5. Nelson RA, Levine AM, Bernstein L, Smith DD, Lai LL. Changing patterns of anal canal carcinoma in the United States. J Clin Oncol 2013;31:1569-75.
6. Uronis HE, Bendell JC. Anal cancer: an overview. Oncologist 2007;12:524-34.
7. Centers for Disease Control and Prevention (CDC). Human papillomavirus-associated cancers - United States, 2004-2008. MMWR Morb Mortal Wkly Rep 2012;61:258-61.
8. Altekruse SF, Kosary CL, Krapcho M, et al. SEER Cancer Statistics Review 2010;1975-2007.
9. Cummings BJ. Metastatic anal cancer: the search for cure. Onkologie 2006;29:5-6.
10. Goodman K, Rothenstein D, Lajhem C, et al. Capecitabine plus mitomycin in patients undergoing definitive chemoradiation for anal squamous cell carcinoma. Int. J Radiat Oncol Biol Phys 2014;90:32-33
11. Hoots BE, Palefsky JM, Pimenta JM, et al. Human papillomavirus type distribution in anal cancer and anal intraepithelial lesions. Int J Cancer 2009;124:2375-83.
12. Palefsky JM, Giuliano AR, Goldstone S, et al. HPV vaccine against anal HPV infection and anal intraepithelial neoplasia. N Engl J Med 2011;365:1576-85.
13. Ajani JA, Winter KA, Gunderson LL, et al. Fluorouracil, mitomycin, and radiotherapy vs fluorouracil, cisplatin, and radiotherapy for carcinoma of the anal canal: a randomized controlled trial. JAMA 2008;299:1914-21.
14. Chai CY, Tran Cao HS, Awad S, et al. Management of stage I squamous cell carcinoma of the anal canal. JAMA Surg 2018;153:209-15.
15. Deshmukh AA, Zhao H, Das P, et al. Clinical and economic evaluation of treatment strategies for T1N0 anal canal cancer. Am J Clin Oncol 2018;41:626-31.