

# The clinical and histopathological effects of perineural dexmedetomidine and in combination with sodium bicarbonate in sciatic nerve block in rabbits after sevoflurane anesthesia: A placebo controlled, randomized experimental study

Sedat Akbas<sup>1</sup>, Ahmet Selim Ozkan<sup>1</sup>, Resit Sevimli<sup>2</sup>, Saadet Alan<sup>3</sup>

<sup>1</sup>Inonu University Faculty of Medicine, Department of Anesthesiology and Reanimation, Malatya, Turkey

<sup>2</sup>Inonu University Faculty of Medicine, Department of Orthopedics and Traumatology, Malatya, Turkey

<sup>3</sup>Inonu University Faculty of Medicine, Department of Pathology, Malatya, Turkey

Copyright © 2019 by authors and Annals of Medical Research Publishing Inc.

## Abstract

**Aim:** Peripheral nerve blockade is a common regional anesthetic technique in surgical procedures in daily clinical practice. The aim of this experimental study was to compare perineural dexmedetomidine alone with perineural sodium bicarbonate added to dexmedetomidine for measurement of analgesia, sensorial and motor blockade and histopathologic evaluation.

**Material and Methods:** Twenty-four rabbits were randomly allocated to 3 groups; Group S: sham, Group D: perineural dexmedetomidine (20 mcg/kg) and Group D+SB: perineural dexmedetomidine (20 mcg/kg) plus sodium bicarbonate (8.4%, 0.125 mL). Analgesia measurement was evaluated by hotplate test, the paw withdrawal response was performed for sensorial and motor blockades, also were recorded at baseline, 30, 60, 90 and 120 min after drug administration. Dissected nerve tissue was also examined for histopathologic evaluation.

**Results:** Latency times of Group D or Group D+SB were significantly longer when compared with Group S at 30, 60, 90 and 120 min. There was no significant difference between Group D and Group D+SB for the all scheduled times. Sensorial and motor blockade scores were similar in all groups. Group D or Group D+SB caused edema, inflammation with neutrophil leukocytes, and degeneration of myelin fibers, increased in vacuolization, granulation tissue and fibrosis.

**Conclusion:** Perineural dexmedetomidine alone or in combination with sodium bicarbonate prolonged the duration of analgesia, but did not enhance the sensorial and motor blockade, when compared with placebo. Perineural dexmedetomidine combined with sodium bicarbonate didn't enhance the blockage. Dexmedetomidine caused edema, inflammation and degeneration of myelin fibers, increased in granulation tissue and fibrosis.

**Keywords:** Paw Withdrawal; Perineural Dexmedetomidine; Alkalinization; Sciatic Nerve Blockage; Analgesia Meter.

## INTRODUCTION

Peripheral nerve blockade is a common regional anesthetic technique and performed in a wide spectrum of surgical procedures in daily clinical practice. The most common problem associated with peripheral nerve block techniques is the limited onset and duration of block. The local anesthetic peripheral nerve blocks have increased to use for surgical procedure and postoperative pain management in combination with adjuvant drugs such as

opioids, ketamine, dexamethasone and dexmedetomidine (1).

Dexmedetomidine, was first used as an adjuvant drug in 2004 for an intravenous regional anesthesia, is a highly selective alpha-2 adrenergic receptor agonist (2). Brummett et al. was first described the efficacy of perineural dexmedetomidine in combination with bupivacaine in an experimental study. They showed that many kinds of concentrations of dexmedetomidine

Received: 25.10.2018 Accepted: 07.11.2018 Available online: 13.11.2018

Corresponding Author: Sedat Akbas, Inonu University Faculty of Medicine, Department of Anesthesiology and Reanimation, Malatya, Turkey, E-mail: sedat.akbas@inonu.edu.tr

progressively increased durations of blockage (3). On the other hand, many randomized controlled trials have demonstrated that the use of dexmedetomidine as an adjuvant drug potentially enhanced local anesthetic peripheral nerve blockade by prolonging duration of analgesia (4). Although the use of dexmedetomidine in peripheral nerve blocks and neuraxial anesthesia is off-label, many of them showed it efficient and safe in clinical practice (5).

There exist a number of different studies with comparing dexmedetomidine and many kind of local anesthetics in this field. To date, however, there has been no detailed randomized study comparing perineural dexmedetomidine plus sodium bicarbonate, commonly preferred to prolong the duration of analgesia. The present study sought to address this gap by performing an experimental study to compare perineural dexmedetomidine alone with perineural dexmedetomidine plus sodium bicarbonate in sciatic nerve block in rabbits after sevoflurane anesthesia. This placebo controlled experimental study analyzed the hypothesis that perineural sodium bicarbonate added to dexmedetomidine, when compared with perineural dexmedetomidine alone, evaluated the measurement of analgesia and the duration of sensory and motor blockade.

## MATERIAL and METHODS

### 1. Protocol

This experimental study was made by the approval University Animal Experiments Local Ethics Committee (2017/A-56). Study was performed on 24 New-Zealand type male rabbits weighing between 2–4 kg from our Animals Research Center. Rabbits were housed in cages (74 x 72 x 47 cm) (R-type Cage; Tecniplast, Varese, Italy). Each cage had a resting platform (30 x 68 x 28 cm) a shelter. All rabbits might access to water and food during the experimental study period. Food for rabbits were formed of a commercial dry pellet diet (Sanders R-01; Agroalimentaria Aznar SA, Pamplona, Spain), and water was also provided by bottles. Animals were housed under controlled environmental conditions (at 21-22° C room temperature, humidity of 45–55% and 15 fresh air changes per hour). Photoperiod consisted period of 12-hour daylight/12-hour night. We accepted and applied according to the norms of animal experiment reported by the National Health Research Institute.

### 2. Drug Preparation

Normal saline and dexmedetomidine (Precedex vial 200 mcg mL<sup>-1</sup>, Abbott Pharmaceutical Ind. and Trade Inc., North Chicago, USA) or sodium bicarbonate solution (8.4% NaHCO<sub>3</sub>) was mixed with each other to get final concentration for administration to perineural area. Dexmedetomidine doses were determined by the weight of each rabbit. Sciatic nerve injections were applied by an investigator who was blinded to drug administration, another investigator performed the measurement of analgesia (hotplate test), sensory and motor blockades. Laboratory assistants also prepared the drugs.

### 3. Experimental Design

Rabbits were randomly allocated to 3 groups; Group S: sham (perineural saline, 0.625 mL, n=8); The skin was closed after injection 0.625 mL saline to unilateral sciatic nerve, Group D: perineural dexmedetomidine (0.5 mL, 20 mcg/kg) plus saline (0.125 mL, n=8) and Group D+SB: perineural dexmedetomidine (0.5 mL, 20 mcg/kg) plus sodium bicarbonate (8.4%, 0.125 mL, n=8); and all study drugs were injected into the perineural zone.

### 4. Sciatic Nerve Injection

Each rabbit was preoxygenated by facemask with 100% oxygen for three minutes, then induced with sevoflurane 8% by face mask. The rabbits were manually ventilated by facemask when spontaneous breathing is suppressed. Sciatic nerve block procedure was performed with sterile materials carried out using aseptic techniques. Injection to perineural zone of unilateral sciatic nerve was performed after making a skin incision and carefully dissected the muscles and adipose tissues with surgical techniques by orthopedic surgeon. At the midpoint of the dissection, an unabsorbable muscle fascia suture was performed as a marker for the removal of the nerve. After the injection, controls were made every 30 minutes. After closing the skin in all groups, a paw withdrawal response was observed and recorded every 30 minutes until the sensory block of the test animal returned. Hotplate test was used to evaluate analgesia. Histopathology of tissue was also examined for histopathologic evaluation of the injection site.

### 5. Analgesia Measurement

Hotplate, which was used for evaluating thermal analgesia, was performed to measure acute thermal pain. The surface of Hotplate (Electro mag Instruments, Istanbul, Turkey) which could be controlled using a digital thermometer was heated to attain a stable temperature of 50°C. The time (in seconds) between shaking, claw licking, and plate-to-jump was admitted as latency time when the rabbits were placed on the hot plate surface. To avoid tissue damage, the cut-off time was set to 60 seconds (8). The preliminary was reflected as the mean response times ensured 0 and 30 minutes before drug injection and was accepted as the normal reply of the rats to heat effect. The latency time in the hotplate test was recorded at 0, 30, 60, 90, and 120 minutes after drug administration.

### 6. Sensory and motor blockades

The paw withdrawal response of the toes was accepted to evaluate sensory functions, while the force of the toes was applied laterally to the forceps. The forceps grip was limited to 1 second so as not to damage the claw tissue directly. The rats succeeded in pulling the paw tested in reaction to pain. Sensory reactions were defined according to withdrawal or dubbing and judged as describes; the forceful paw withdrawal response after pinching (normal sensory function): 0, moderate withdrawal: 1, lowest withdrawal: 2 and no response (complete sensory block): 3. In addition, motor functions were evaluated as follows using a scale of 0-3; regular motor activation 0, regular

dorsiflexion motion and moving with curved toes: 1, moderate dorsiflexion motion and moving with curved toes: 2, no dorsiflexion motion and moving with curved toes: 3. Sensory and motor evaluations were measured at 30 minutes intervals by another blinded researcher.

### 7. Histopathological Evaluation

Sciatic nerve excisions for 4 rabbits belonging to each group were performed by the orthopedic surgeon at the end of 1<sup>st</sup> day after saline or drug administration. And remaining rabbits belonging to each group were also performed at the end of 14<sup>th</sup> day after saline or drug administration. After the removal sciatic nerves, each rabbit was then administered a lethal dose of ketamine (600 mg, IV) for euthanasia.

A pathologist who was blinded to the treatment groups performed the histopathological evaluation. The sciatic nerve segments, approximately 1-1.5 cm in length, were extracted. They were fixed with 10% neutral formaldehyde solution for 24-48 hours and sampled as incisions of horizontal and vertical axis. After fixation, tissues were embedded into the paraffin blocks after dehydration and clearing. Paraffin blocks of 4-5  $\mu$ m thickness were prepared in a rotary microtome and deparaffinized in 60°C. After deparaffinization, routine Hematoxylin&Eosin (H&E) staining method was performed. Prepared H&E samples were evaluated under the Olympus BX-51 light microscope and photographed on the Olympus DP-70.

All groups were evaluated with H&E staining in the light microscope at the 1<sup>st</sup> and 14<sup>th</sup> days. The presence of edema, inflammation of surrounding tissue and epineurium, degeneration of myelin fibers and fibrosis in the sciatic nerve were evaluated as semi quantitative on a scale of; 0= no edema, inflammation and fibrosis, 1= mild edema, inflammatory infiltrate and fibrosis in small area, 2= edema, moderate inflammatory infiltrate and fibrosis in local areas, 3= significant edema, severe inflammatory infiltrate and fibrosis (3). Sciatic nerve damage was evaluated on a scale of; 0= no lesion, 1= 1-2% damage of axons and myelin fibers, 2= 2-5% damage of axons and

myelin fibers and 3= more than 5% damage of axons and myelin fibers (6).

### 8. Statistical Analysis

Sample size value was determined in our study with statistical power analysis and was accounted as a power of 0.80. Records were examined using software program for Windows (IBM SPSS statistics version 23, IBM Corp, New York). The records were offered as minimum and maximum (median). The guess of a standard distribution was supported with the Kolmogorov– Smirnov test. The Kruskal–Wallis test was performed without provided guess of normality. The Mann–Whitney U test with Bonferroni's correction was carried out when multiple comparisons were needed. For histological analysis; the statistical significance was detected at  $p < 0.01$  and similarly, Mann–Whitney U test was preferred when multiple comparisons were needed. All data was given as median (minimum - maximum) and were accepted as significant when  $p < 0.05$ .

## RESULTS

All rabbits enrolled in this experimental investigation completed the study. Rabbits were evaluated for thermal analgesia and neurobehavioral examination by the hotplate and the paw withdrawal responses, respectively.

### Results of hotplate test

Onset latency times were 11 (8-16) sec for Group S, 14 (8-27) sec for Group D and 10 (8-0) sec for Group D+SB, respectively. There was no significant differences between the groups in terms of onset latency times in hotplate test ( $p = 0.207$ , Kruskal Wallis test). Also, baseline latency times of all groups were similar in hotplate test ( $p = 0.130$ , one way ANOVA analysis). There was significant differences between the groups in one-way ANOVA analyses in terms of the 30<sup>th</sup>, 60<sup>th</sup>, 90<sup>th</sup> and 120<sup>th</sup> times ( $p = 0.003$ ,  $p < 0.001$ ,  $p < 0.001$  and  $p < 0.001$ , respectively). Latency times of Group D or Group D+SB were significantly longer when compared with Group S in terms of the 30<sup>th</sup>, 60<sup>th</sup>, 90<sup>th</sup> and 120<sup>th</sup> times. Post Hoc test for multiple comparison showed there was no significant difference between Group D and Group D+SB for the all scheduled times. Hotplate test and latency times are presented in Table 1.

**Table 1. Hotplate test and latency times (s), according to groups<sup>1</sup>**

Time (min)	Group S (n: 8)	Group D (n: 8)	Group D+SB (n: 8)	p values
	Mean $\pm$ SD (min - max)	Mean $\pm$ SD (min - max)	Mean $\pm$ SD (min - max)	
Onset <sup>2</sup>	11.38 $\pm$ 2.92 (8 - 16)	15.63 $\pm$ 6.36 (8 - 27)	11.25 $\pm$ 3.73 (8 - 20)	0.207*
Baseline <sup>2</sup>	22.25 $\pm$ 8.95 (9 - 38)	32.00 $\pm$ 6.48 (20 - 38)	30.88 $\pm$ 13.46 (20 - 60)	0.130**
30	14.00 $\pm$ 11.82 (7 - 43)	34.00 $\pm$ 14.19 (22 - 60)	35.25 $\pm$ 9.88 (25 - 55)	0.003**
60	11.22 $\pm$ 4.58 (3.3 - 17)	45.62 $\pm$ 14.00 (30 - 60)	35.50 $\pm$ 10.58 (20 - 54)	<0.001**
90	13.13 $\pm$ 8.59 (5 - 30)	46.63 $\pm$ 13.56 (25 - 60)	34.25 $\pm$ 12.33 (18 - 50)	<0.001**
120	8.00 $\pm$ 4.62 (4 - 17)	29.75 $\pm$ 9.66 (20 - 50)	31.63 $\pm$ 11.07 (20 - 50)	<0.001**

<sup>1</sup> Group S: sham (perineural saline, 0.625 mL, n=8), Group D: perineural dexmedetomidine perineural dexmedetomidine (0.5 mL, 20 mcg/kg) plus saline (0.125 mL, n=8), Group D+SB: perineural dexmedetomidine (0.5 mL, 20 mcg/kg) plus sodium bicarbonate (8.4%, 0.125 mL, n=8)

<sup>2</sup> Onset shows the value which was performed hot-plate test before the administration of saline or drugs. Baseline shows that the latency time which was performed hot-plate test just after the administration of saline or drugs.

\* p value of Kruskal Wallis test between the groups, \*\* p value of one way ANOVA test between the groups

### Sensory and motor blockades

There were no significant differences between the groups in terms of sensorial blockade scores for the all times. Sensorial blockage scores are presented in Table 2. There were no significant differences between the groups in terms of motor blockade scores at baseline, 30<sup>th</sup>, 60<sup>th</sup> and 120<sup>th</sup>. But there was a significant difference between the groups in terms of motor blockade scores at 60th (p=0.006). Motor blockade scores are presented in Table 3.

### Results of histopathological evaluation

Each group was separately evaluated for the histopathological evaluation with respect to the presence of edema, inflammation at epineurium and surrounding tissues, axon-myelin fiber degeneration and fibrosis.

1st day; Group D and Group D+SB meaningfully had edema, inflammation with neutrophil leukocytes, degeneration of myelin fibers, increased in vacuolization granulation tissue and fibrosis, whereas Group S had no significant characteristics. Group D had a significantly higher level of edema and perineural inflammation when compared with Group D+SB. There was no significant difference between the all groups in terms of axon and myelin fiber damage. Group D and Group D+SB had fibrosis around the epineurium, but there was no fibrosis in Group S. There was a statistically significant increased fibrosis

in Group D when compared with Group S. There was a significant difference between Group D and Group D+SB in terms of fibrosis. Also there was significant difference between Group S and Group D+SB in terms of fibrosis. Histopathological changes and appearance of toluidine blue dye in sciatic nerve tissue at 1st day are presented in Figure 1.

14<sup>th</sup> day; Group S had no edema, inflammation at epineurium and surrounding tissues, axon-myelin fiber degeneration and fibrosis. There was a statistically significant difference between Group D and Group D+SB in terms of edema, perineural inflammation and degeneration and fibrosis in myelin fibers. Group D had significant edema and perineural lymphohistiocytic inflammation when compared with Group S. There was significant vacuolization and degeneration in myelin fibers in Group D when compared with other groups. There was no statistically significant difference between Group S and Group D+SB in terms of edema and perineural inflammation. There was statistically significant difference between Group S and Group D+SB in terms of degeneration and fibrosis in myelin fibers. Histopathological changes and appearance of toluidine blue dye in sciatic nerve tissue at 14th day are presented in Figure 2. Histopathological scores; edema, inflammation, myelin fiber degeneration and fibrosis and p values for histopathological scores are presented in Table 4 and 5.

**Table 2. Sensorial blockage scores<sup>1</sup>, according to groups**

Time (min)	Group S (n: 8)	Group D (n: 8)	Group SB (n: 8)	p values
Baseline <sup>2</sup>	0 (0 - 1)	0 (0)	0 (0 - 1)	1.000
30	0 (0 - 1)	0 (0 - 2)	0 (0 - 1)	0.714
60	0 (0 - 1)	1 (0 - 2)	0 (0 - 1)	0.253
90	0 (0 - 1)	1 (0 - 1)	0 (0 - 1)	0.057
120	0 (0 - 1)	0 (0)	0 (0)	1.000

Group S: sham (perineural saline, 0.625 mL, n=8), Group D: perineural dexmedetomidine perineural dexmedetomidine (0.5 mL, 20 mcg/kg) plus saline (0.125 mL, n=8), Group D+SB: perineural dexmedetomidine (0.5 mL, 20 mcg/kg) plus sodium bicarbonate (8.4%, 0.125 mL, n=8)

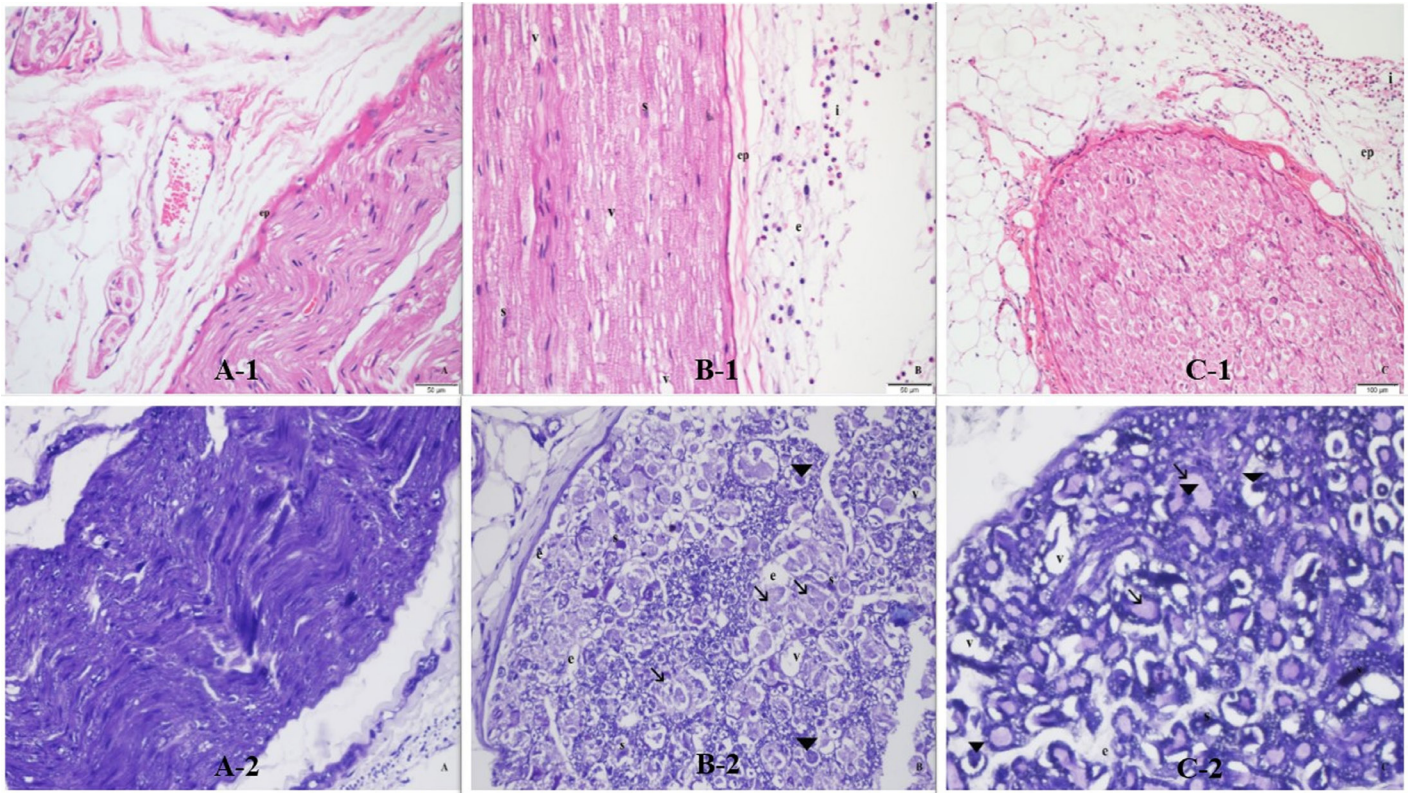
<sup>1</sup>Sensorial blockage scores were defined as; the forceful paw withdrawal response after pinching (normal sensory function): 0, moderate withdrawal: 1, lowest withdrawal: 2 and no response (complete sensory block): 3. <sup>2</sup>Baseline shows that the latency time which was performed hot-plate test just after the administration of saline or drugs

**Table 3. Motor blockage scores<sup>1</sup>, according to groups**

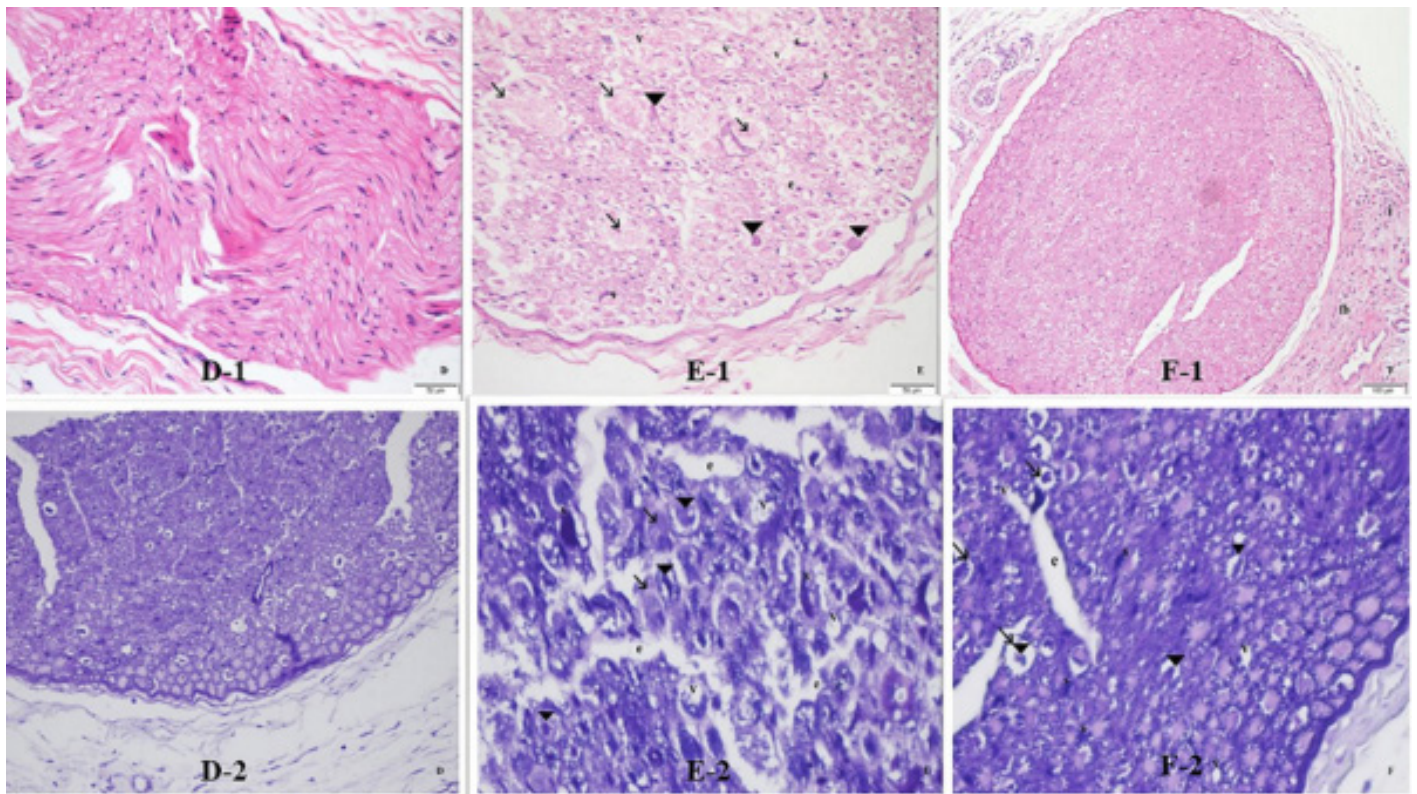
Time (min)	Group S (n: 8)	Group D (n: 8)	Group SB (n: 8)	p values
Baseline <sup>2</sup>	0 (0)	0 (0)	0 (0 - 1)	1.000
30	0 (0)	0 (0 - 1)	0 (0 - 1)	0.745
60	0 (0)	1 (0 - 2)	0 (0 - 1)	0.052
90	0 (0)	1 (0 - 1)	0 (0 - 1)	0.006*
120	0 (0)	0 (0)	0 (0)	1.000

Group S: sham (perineural saline, 0.625 mL, n=8), Group D: perineural dexmedetomidine perineural dexmedetomidine (0.5 mL, 20 mcg/kg) plus saline (0.125 mL, n=8), Group D+SB: perineural dexmedetomidine (0.5 mL, 20 mcg/kg) plus sodium bicarbonate (8.4%, 0.125 mL, n=8).

<sup>1</sup>Motor blockage scores were defined as; regular motor activation 0, regular dorsiflexion motion and moving with curved toes: 1, moderate dorsiflexion motion and moving with curved toes: 2, no dorsiflexion motion and moving with curved toes: 3. <sup>2</sup>Baseline shows the time which was performed hot-plate test just after the administration of saline or drugs



**Figure 1.** Histopathological changes (A-1, B-1, and C-1) and appearance of toluidine blue dye (A-2, B-2, and C-2) in sciatic nerve tissue. \*epi; epineurium, e; edema, v; vacuolization, i; inflammation, arrow head; degenerated axons, s; swollen Schwann cells, thick arrow; myelin degeneration, hematoxylin-eosin staining



**Figure 2.** Histopathological changes (D-1, E-1, and F-1) and appearance of toluidine blue dye (D-2, E-2, and F-2) in sciatic nerve tissue. \*epi; epineurium, e; edema, v; vacuolization, i; inflammation, arrow head; degenerated axons, s; swollen Schwann cells, thick arrow; myelin degeneration, hematoxylin-eosin staining

**Table 4. Histopathological scores; edema, inflammation, myelin fiber degeneration and fibrosis**

		Edema	Inflammation	Myelin fiber degeneration	Fibrosis
1.day	Group S	0	0	0	0
	Group D	1.75 ± 0.43	2.25 ± 0.43	1 ± 0	1.25 ± 0.43
	Group D+SB	1 ± 0	1.25 ± 0.5	1 ± 0	0.25 ± 0.5
14.day	Group S	0	0	0	0
	Group D	1.5 ± 0.57	1.5 ± 1	1.5 ± 1	1.75 ± 1.25
	Group D+SB	1 ± 0	1 ± 0	0.5 ± 0.5	1.25 ± 0.43

Group S: sham (perineural saline, 0.625 mL, n=8), Group D: perineural dexmedetomidine perineural dexmedetomidine (0.5 mL, 20 mcg/kg) plus saline (0.125 mL, n=8), Group D+SB: perineural dexmedetomidine (0.5 mL, 20 mcg/kg) plus sodium bicarbonate (8.4%, 0.125 mL, n=8)

**Table 5. p values for histopathological scores**

		Edema	Inflammation	Myelin fiber degeneration	Fibrosis
1.day	Group S & Group D	<0,001	<0,01	>0,1	<0,01
	Group S & Group D+SB	>0,1	<0,01	>0,1	>0,1
	Group D & Group D+SB	<0,01	<0,05	>0,1	<0,05
14.day	Group S & Group D	<0,1	<0,05	<0,05	<0,05
	Group S & Group D+SB	>0,1	>0,1	<0,1	<0,01
	Group D & Group D+SB	<0,1	<0,1	<0,1	>0,1

Group S: sham (perineural saline, 0.625 mL, n=8), Group D: perineural dexmedetomidine perineural dexmedetomidine (0.5 mL, 20 mcg/kg) plus saline (0.125 mL, n=8), Group D+SB: perineural dexmedetomidine (0.5 mL, 20 mcg/kg) plus sodium bicarbonate (8.4%, 0.125 mL, n=8)

## DISCUSSION

This placebo controlled experimental study showed that perineural dexmedetomidine alone or in combination with sodium bicarbonate prolonged the latency times in hotplate test, while did not enhance the sensorial and motor blockade scores, when compared with placebo. Contrary to our hypothesis, there was no significant difference between perineural dexmedetomidine and perineural dexmedetomidine plus sodium bicarbonate. In histopathological evaluation, perineural dexmedetomidine alone or in combination with sodium bicarbonate caused edema, inflammation with neutrophil leukocytes, and degeneration of myelin fibers, increased in vacuolization, granulation tissue and fibrosis.

Ketamine and xylazine, which have longer duration of analgesia (nearly 60 min after injection) are generally performed in the experimental studies. The analgesic effect and longer duration of these drugs cause to evaluate the analgesia measurements inaccurate. Thus, our experimental study was specifically designed as to maintain the general anesthesia with sevoflurane, which provides a shorter time to start surgical intervention and a faster recovery from anesthesia. Therefore we could evaluate the hotplate test, sensorial and motor blockages more quickly, just after the recovery from anesthesia. We therefore thought that an application of sevoflurane anesthesia, which is rarely used in experimental practice to maintain the general anesthesia, would contribute useful and practical data.

A number of previous clinical and experimental studies have compared the perineural dexmedetomidine added local anesthetics, and all of them have been shown to enhance efficacy with faster onset and longer duration of analgesia (7-13). For example, Hu et al reported in a clinical study that, perineural dexmedetomidine in combination with lidocaine and ropivacaine enhanced the efficacy for sciatic nerve blockade with faster onset and longer duration (7). Gurajala et al reported that the addition of dexmedetomidine to ropivacaine improved the onset time, quality and duration of block but did not decrease the anesthetic agent requirement during general anesthesia (8). Similarly, Dolu et al reported in an experimental study that, perineural bupivacaine plus dexmedetomidine prolonged sensory and motor block times in sciatic nerve block in rats (14). In our study, we observed that perineural dexmedetomidine alone prolonged the duration of analgesia.

Many clinical and experimental studies have been performed to establish the effects of alkalinization on potency of local anesthetics. Alkalinization of local anesthetics has been proposed to shorten the onset of blockade, and increase the duration and quality of analgesia (15). Ririe et al reported that sodium bicarbonate combined with lidocaine for median nerve block significantly increased the rate of motor block (16). In our study, we hypothesized that perineural dexmedetomidine in combination with sodium bicarbonate might enhance the duration of analgesia or sensorial and motor blockade.

Contrary to our hypothesis, there were no significant differences between perineural dexmedetomidine alone and perineural dexmedetomidine in combination with sodium bicarbonate. While dexmedetomidine was not a local anesthetic, we examined again as previously experienced that dexmedetomidine prolonged the duration of analgesia and no change with respect to sensorial and motor blockade.

The injections of perineural local anesthetics or combined with adjuvants had increased severity of nerve injury. Despite the many benefits of perineural administration, intraneural injections unfortunately occur in clinical practice, cause peripheral nerve damage and remain an important clinical problem. On the other hand, previous studies have shown that dexmedetomidine attenuates inflammatory responses induced by local anesthetic drugs (17). Kim et al reported that intraneural dexmedetomidine enhanced the effects of sensory and motor blockade, had anti-inflammatory properties, and protective effects against neural injury and dexmedetomidine as an adjuvant had beneficial effects in rat when local anesthetic drugs injected intraneurally (18). Memari et al reported that combining dexmedetomidine with bupivacaine had a high level of perineural inflammation and nerve damage at day 14 post-injection. Bupivacaine was considered in association with meaningful histopathological changes, including edema of the perineurium and myelin degeneration, when performed perineurally (19). In our study, we found in histopathological evaluation that perineural dexmedetomidine meaningfully had edema, perineural inflammation and increased fibrosis when compared with placebo and there was no change in terms of axon and myelin fiber damage in all groups at 1st day. Perineural dexmedetomidine and/or in combination with sodium bicarbonate had significant edema, perineural lymphohistiocytic inflammation, vacuolization and degeneration in myelin fibers at 14th day. In our experience, there was intraneural injection. Although dexmedetomidine as an adjuvant had beneficial effects, it caused neural injury when performed perineurally.

### Limitations

This study has some limitations. First, the effects of dexmedetomidine may be explained by systemic absorption rather than the perineural administration. Second, the assessments of sensorial and motor blockages were subjective, based on measures previously described (11). Third, we used the dexmedetomidine perineurally with a dose of 20 mcg/kg, despite the effective dose of perineural administration is required to determine the optimum dose without the side effects. In addition, the present study was designed to analyze the duration of sensorial and motor blockades, not to test the onset.

### CONCLUSION

This placebo controlled experimental study concluded that perineural dexmedetomidine alone or in combination with sodium bicarbonate prolonged the duration of analgesia and did not enhance the sensorial and motor blockade,

when compared with placebo. On the contrary to our hypothesis, there was no significant difference between perineural dexmedetomidine alone and in combination with sodium bicarbonate. In histopathological evaluation, dexmedetomidine caused edema, inflammation and degeneration of myelin fibers, increased in vacuolization, granulation tissue and fibrosis.

*Competing interests: The authors declare that they have no competing interest.*

*Financial Disclosure: There are no financial supports*

*Ethical approval: This experimental study was made by the approval of Inonu University Animal Experiments Local Ethical Committee (Protocol no: 2017/A-56) and supported by Scientific Research Projects Coordination Unit of Inonu University. (Project Code: TSA-2018-987).*

*Sedat Akbas ORCID: 0000-0003-3055-9334*

*Ahmet Selim Ozkan ORCID: 0000-0002-4543-8853*

*Resit Sevimli ORCID: 0000-0002-0822-0492*

*Saadet Alan ORCID: 0000-0003-2329-151X*

### REFERENCES

1. Keplinger M, Marhofer P, Kettner SC, et al. A pharmacodynamic evaluation of dexmedetomidine as an additive drug to ropivacaine for peripheral nerve blockade: A randomised, triple-blind, controlled study in volunteers. *Eur J Anaesthesiol* 2015;32:790-6.
2. Memiş D, Turan A, Karamanlioğlu B, et al. Adding dexmedetomidine to lidocaine for intravenous regional anesthesia. *Anesth Analg* 2004;98:835-40.
3. Brummett CM, Norat MA, Palmisano JM, et al. Perineural administration of dexmedetomidine in combination with bupivacaine enhances sensory and motor blockade in sciatic nerve block without inducing neurotoxicity in rat. *Anesthesiol* 2008;109:502-11.
4. Kirksey MA, Haskins SC, Cheng J, et al. Local Anesthetic peripheral nerve block adjuvants for prolongation of analgesia: a systematic qualitative review. *PLoS One* 2015;10:e0137312.
5. Marhofer P, Brummett CM. Safety and efficiency of dexmedetomidine as adjuvant to local anesthetics. *Curr Opin Anaesthesiol* 2016;29:632-7.
6. Yektaş A, Çabalar M, Sar M, et al. Perineural dexmedetomidine effects on sciatic nerve in rat. *Braz J Anesthesiol* 2017;67:57-66.
7. Hu X1, Li J, Zhou R, et al. Dexmedetomidine added to local anesthetic mixture of lidocaine and ropivacaine enhances onset and prolongs duration of a popliteal approach to sciatic nerve blockade. *Clin Ther* 2017;39:89-97.
8. Gurajala I, Thipparampall AK, Durga P, et al. Effect of perineural dexmedetomidine on the quality of supraclavicular brachial plexus block with 0.5% ropivacaine and its interaction with general anaesthesia. *Indian J Anaesth* 2015;59:89-95
9. Trein TA, Floriano BP, Wagatsuma JT, et al. Effects of dexmedetomidine combined with ropivacaine on sciatic and femoral nerve blockade in dogs. *Vet Anaesth Analg* 2017; 2987:31396-4.
10. Helal SM, Eskandr AM, Gaballah KM, et al. Effects of perineural administration of dexmedetomidine in combination with bupivacaine in a femoral-sciatic nerve block. *Saudi J Anaesth* 2016;10:18-24.
11. Ali Erdogan M, Polat A, Yucel A, et al. Effects of perineural administration of dexmedetomidine in combination with

- levobupivacaine in a rat sciatic nerve block. *Curr Ther Res Clin Exp* 2013;74:74-8.
12. Zhang Y, Wang CS, Shi JH, et al. Perineural administration of dexmedetomidine in combination with ropivacaine prolongs axillary brachial plexus block. *Int J Clin Exp Med* 2014;7:680-5.
  13. Marhofer D, Kettner SC, Marhofer P, et al. Dexmedetomidine as an adjuvant to ropivacaine prolongs peripheral nerve block: a volunteer study. *Br J Anaesth* 2013;110:438-42.
  14. Dolu N, Şahin L, Kaplan DS, et al. The effects of bupivacaine combined with different adjuvants on block onset and duration and on ion channel expressions (SCN9A, TRPM) in sciatic nerve block in rats. *Turk J Med Sci* 2016;46:926-35.
  15. Capogna G, Celleno D, Laudano D, et al. Alkalinization of local anesthetics. Which block, which local anesthetic? *Reg Anesth* 1995;20:369-77.
  16. Ririe DG, Walker FO, James RL, et al. Effect of alkalinization of lidocaine on median nerve block. *Br J Anaesth* 2000;84:163-8.
  17. Huang Y, Lu Y, Zhang L, et al. Perineural dexmedetomidine attenuates inflammation in rat sciatic nerve via the NF- $\kappa$ B pathway. *Int J Mol Sci* 2014;15:4049-59.
  18. Kim BS, Choi JH, Baek SH, et al. Effects of intraneural injection of dexmedetomidine in combination with ropivacaine in rat sciatic nerve block. *Reg Anesth Pain Med* 2018;43:378-84.
  19. Memari E, Hosseinian MA, Mirkheshti A, et al. Comparison of histopathological effects of perineural administration of bupivacaine and bupivacaine-dexmedetomidine in rat sciatic nerve. *Exp Toxicol Pathol* 2016;68:559-64.